Hand & Microsurgery

Case Report
Hand Microsurg 2018;X:X-X
doi:10.5455/handmicrosurg.9243

eJM eJManager OPEN ACCESS

Hand therapy following post-traumatic metacarpophalangeal joint arthroplasty: A case report

Zeynep Tuna[1], Mustafa Sari[2], Deran Oskay[1]

ABSTRACT

The purpose of this case report is to contribute to the literature on the physiotherapy assessment and treatment methods following metacarpophalangeal (MCP) joint arthroplasty and to present the results of our treatment program. The patient was a 27-year-old male military staff with a left hand traumatic injury. One year after injury, MCP joint was replaced with a pyrocarbon implant. Hand therapy was planned as four consecutive stages. The first phase focused on early interventions and patient education. After 4 weeks, active joint movements were emphasized. Additional emphasis was placed on strengthening exercises and prevention of the complications in the later stages. In the late-term rehabilitation program after 12th week, return to work and daily life was targeted. The patient was assessed at the 4th, 8th, 12th and 16th weeks after the surgery. The results of the range of motion, grip and pinch strength, functional test and disability level all improved with the treatment program. Initial signs of potential complications were also noted and precaution was taken. Patient-tailored hand therapy program provided significant functional improvements after post-traumatic MCP arthroplasty. Besides, signs of potential complications were recognized through early interventions and regular assessments and any deformity was prevented.

Key words: *Hand function, hand therapy, metacarpophalangeal joint arthroplasty, physiotherapy*

Introduction

Metacarpophalangeal (MCP) joint lesion results in a significant disability as this joint is a key element in hand functions for its both mobility and stabilization roles. Thus, in severe cases the replacement of the joint becomes indicated. Patients benefit from MCP joint arthroplasty as it improves hand function through pain relief, deformity correction, and restoration of the range of motion [1-3]. It is mostly indicated in arthritic conditions and much less in traumatic injuries.

Arthritic conditions which indicate MCP arthroplasty have been widely studied though the literature on post-traumatic arthroplasty received less attention so far [2,4,5]. Likewise, publications focusing on hand

Author affiliations : *Department of Physiotherapy and Rehabilitation, [1]Gazi University, [2]Lokman Hekim University, Ankara, Turkey*
Correspondence : *Mustafa Sarı, MD, Department of Physiotherapy and Rehabilitation, Lokman Hekim University, Ankara, Turkey*
e-mail: mustafa.sari@lokmanhekim.edu.tr
Received / Accepted : *September 20, 2018 / November 04, 2018*

© 2018 Turkish Society for Surgery of the Hand and Upper Exremity

therapy after MCP arthroplasty are also relatively insufficient. The traditional principle such as the maintenance of the joint stability while regaining the functions seems to be the primary goal of post-arthroplasty therapy. In the post-operative process of these patients, various forms of immobilization and exercises are used and gradual return to work and daily life with joint protection principles is targeted. Despite these common principles and therapy methods, there are wide differences in the splinting, exercises and time frames among different conditions and a follow-up therapy has not been reported after MCP arthroplasty in traumatic cases [6]. Therefore, with this case report, we would like to contribute to the literature on hand therapy after post-traumatic MCP arthroplasty with making a point to the potential complications and present the results of our treatment program.

Case Report

The patient was a 27-year-old right-handed male military staff. In January 2017, he got injured on his left hand by an explosive incident during a military field mission. He consulted our hand therapy clinic as an outpatient at the post-operative third week. After informing the patient in detail about the treatment, he gave his written consent for publication, too.

The patient had his final epicrisis of the arthroplasty surgery and gave verbal information about the previous interventions.

The patient applied to the emergency service of a university hospital in a nearby city immediately after the injury. The wound was repaired primarily there. One week after the injury, the patient applied to the Orthopaedics and Traumatology Department in a university hospital. He had an arthrodesis on his second finger as the MCP joint was defectively injured. Three months after the arthrodesis, an external fixator was placed in his finger and traction was applied for 6 months. However, our patient did not want to retire from the military due to the disability in his hand and he did prefer to have an MCP joint arthroplasty. The surgery was performed in January 2018. After the surgery, he consulted our hand therapy clinic.

Surgical Procedure

During the operation, index finger MCP joint was replaced with a double-compartment endoprosthesis. Under general anaesthesia, the second MCP joint was reached through a long dorsal incision with splitting the extensor tendon. It was seen that the proximal 1/3 part of the proximal phalanx was defective. The proximal and distal compartments of 3 to 2 size were placed appropriately. It was seen that the implants were stable and the collateral ligaments were intact. The joint capsule and extensor tendon were repaired. The patient had no post-operative problems and was discharged on the post-operative second day.

Hand Therapy Protocol

The patient applied to our hand therapy clinic individually within the 3rd week. The treatment program was planned as four stages as very early, early, middle, and late rehabilitation stages. The patient was also instructed to perform the exercises at home. The frequency for exercises was ten repetitions per every 3 hours.

1. Very Early Rehabilitation (Post-operative 3rd - 4th week):

- Elevation and massage for oedema control
- Patient education for hand care and against the signs of potential complications such as infection
- Active flexion exercises of distal interphalangeal (DIP) and proximal interphalangeal (PIP) joints in a pain-free range

2. Early Rehabilitation (Post-operative 4-8 weeks):

- Hot-pack or warm bath before exercises
- Flexor and extensor tendon gliding exercises
- Finger flexion blocking exercises
- Active second finger flexion, extension and abduction exercises (no adduction)
- Abduction strengthening exercises with rubber band in the horizontal plane as a mild angulation of the finger was noticed (Figure 1).
- For this angulation, the second finger was immobi-



Figure 1. Angulation of the index finger.

lized in a simple splint during the night (Figure 2).

- Light daily life activities such as eating, drinking, texting on the phone were allowed and powerful grip was avoided.

3. Mid-term Rehabilitation (Week 8-12):

- Finger flexion and extension exercises with resistance putty of all joints in the operated finger
- Abduction strengthening exercises of the operated finger with resistance putty
- Night splinting for the angulation in the operated finger was continued with an additive component. Because a slight DIP extension deficit was noticed and thus a component was also added to keep the DIP joint in hyperextension (Figure 3). Strengthening exercise with rubber band for DIP extension was also added.
- Daily life activities were allowed except for heavy work

4. Late Rehabilitation (12 weeks and after):

- Fine pinching activities with coins, keys, needles
- Dynamic functional activities such as catching a ball with the left hand or playing a bimanual game on the mobile phone
- Totally free in daily life
- Return to work

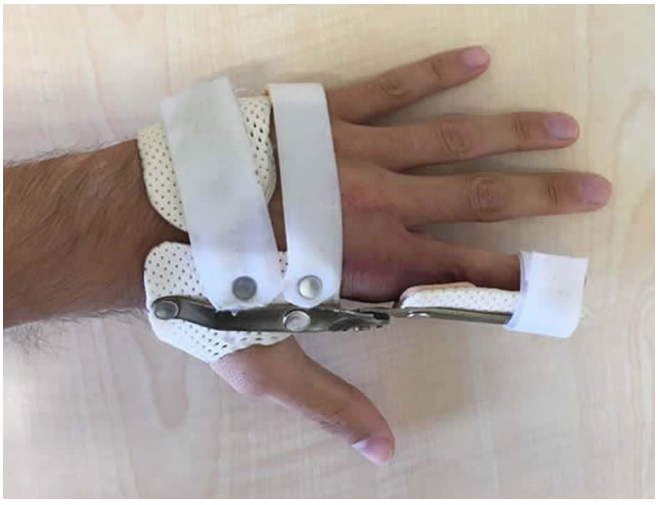

Figure 2. Simple night splinting for the mal-angulation.



Figure 3. An additive component for immobilization of the fingertip in hyperextension.

Assessments

Assessments were carried out at the end of the 4th, 8th, 12th and 16th week. The range of motion, grip and three different pinch (lateral, bipod and tripod) strengths, performance-based function and disability level were evaluated at four consecutive time points. The

Table 1. Results of grip and pinch strength measurements and range of motion of the index finger at consecutive time points (injured side was left).

	4th week		8th week		12th week		16th week	
	R	L	R	L	R	L	R	L
Grip strength (kg-f)	39,2	17,2	37,8	23,8	40,6	27,5	39,8	29
Lateral pinch strength (kg-f)	11,6	2,6	11,3	2,8	11,7	2,9	11,6	3,2
Bipod pinch strength (kg-f)	6,3	2,4	6,1	2,5	6,2	2,8	6,5	3
Tripod pinch strength (kg-f)	9,1	5,0	9,5	5,5	9,4	6,1	9,6	6,4
PIP flexion (°)	120	60	120	65	120	75	120	75
DIP flexion (°)	75	70	75	70	75	75	75	75
DIP extension (°)	0	-20	0	-20	0	-10	0	-10
MCP flexion (°)	90	70	90	80	90	90	90	90
MCP extension (°)	25	0	25	10	25	15	25	20

PIP: Proximal interphalangeal joint; **DIP:** Distal interphalangeal joint; **MCP:** Metacarpophalangeal joint.

Table 2. Results of DASH and NHPT at 4th and 16th week.

Variable		4th week	16th week
DASH		21,55	1,72
NHPT (sec)	R	11,56	11,47
	L	18,42	12,28

DASH: Disabilities of Shoulder, Elbow and Hand; **NHPT:** Nine-Hole Peg Test.

range of motion was measured with a universal finger goniometer, grip strength with a hand-held dynamometer and pinch strength with a pinch meter. Strength measurements were performed in the standard position and the mean value of the three repeats was analysed [7]. Nine-Hole Peg Test (NHPT) was used as a performance-based functional test. The time for replacement and removal was recorded in seconds [8]. The disability level of the patient was assessed by the Turkish version of Disabilities of the Arm, Shoulder and Hand (DASH) questionnaire [9]. DASH and NHPT were performed only at the first and last assessments.

Results

Results of grip and pinch strength and range of motion of the index finger measurements of the injured and non-injured hands are given in Table 1. All the variables improved throughout time with treatment. Especially MCP range of motion reached norm values as flexion range was 90° and extension was 20° after therapy.

DASH questionnaire scores and functional test results also improved in comparison to the beginning (Table 2). DASH score was at almost its minimum level after treatment as it was 1, 72 points.

Discussion

Hand therapy following index finger post-traumatic MCP arthroplasty contributed significantly to functional recovery in our case. Grip and pinch strength, range of motion of the operated finger, functional performance of the hand, and disability level all improved with our patient-tailored treatment program.

We did like to report our hand therapy results in this case as the MCP arthroplasty is an uncommon surgical operation because it is out of healthcare insurance in our country. The most important point that we experienced in this case was the prevention of the deformities that developed during the follow-up. We were alert for any angulation in the finger throughout the follow-up period as we knew that any minor shift would affect the fine intrinsic balance of the hand [10]. For this reason, we took precautions against potential complications such as instability or deformities at the initial phase. Firstly, we noticed the angulation of the MCP joint at the early stage of rehabilitation and therefore we added counteracting exercises and splinting. Moreover, we did allow

only light daily activities despite the patient's minimal disability according to the DASH score. Because we did not feel confident about the stability of the joint once an angulation in the finger appeared. Therefore, powerful grip was still avoided despite the patient's minimal disability because we thought that it may cause further deviation of the finger during the activities. Also, based on our clinical observation, our patient's disability level was minimal as he was very motivated and ambitious for recovery and it aroused a doubt to us about the speed of the progression.

Secondly, in the following stage, we also noticed the extensor lag of the DIP joint possibly due to the splitting of extensor tendon during the surgery. Resistive extension exercises and splint modification were emphasized to prevent a potential Mallet deformity. In the final assessment, we noticed an improvement of 10 degrees in extensor lag with additive treatment.

In arthritic cases, MCP arthroplasty is primarily indicated for pain relief besides functional recovery [11]. However, in contrast to arthritis, our post-traumatic patient reported no pain neither at the first session nor during the whole follow-up period. Therefore, we asked the patient about his pain only verbally, so we did not assess the pain level in detail.

Our treatment program seems to be unique as there is a lack in the published literature about the subject. For our treatment planning, we took the pyrocarbon material used for replacement into account. Among the others, pyrocarbon implants are popular for their mechanical properties such as elasticity, durability and biocompatibility [12,13]. Such advantages of this implant made it possible to start with the active exercises at an early stage. On the other hand, it is not known if the pyrocarbon has disadvantages like vulnerability to instability or other deformities [14]. Therefore, we cannot make any conclusions about the effect of implant type on the potential deformities that we encountered.

In conclusion, MCP arthroplasty is a seldom surgical procedure on the traumatic finger. However, it has great clinical importance as MCP joint is critical in hand function. Published materials focusing on the post-operative hand therapy in this patient population is poor due to the rareness of the operation. With this follow-up report, we did like to contribute to the hand therapy knowledge after MCP arthroplasty surgery. Besides, based on our case, we would like emphasize that careful examination with frequent periods is essential after MCP arthroplasty surgery to prevent the potential deformities starting from the initial phase. However, it is also certain that further studies are necessary for strong evidence about the effects of hand therapy after MCP arthroplasty.

Conflict of interest statement

The authors have no conflicts of interest to declare.

References

1. Aujla RS, Sheikh N, Divall P, Bhowal B, Dias JJ. Unconstrained metacarpophalangeal joint arthroplasties: a systematic review. Bone Joint J 2017;99B: 100-6.
2. Massy-Westropp N, Johnston RV, Hill C. Post-operative therapy for metacarpophalangeal arthroplasty. Cochrane Database Syst Rev 2008;23:CD003522.
3. Blair SJ, Swanson AB, Swanson GD. Evaluation of impairment of hand and upper extremity function. Instr Course Lect 1989;38:73-102.
4. Parker WL, Rizzo M, Moran SL, Hormel KB, Beckenbaugh RD. Preliminary results of nonconstrained pyrolytic carbon arthroplasty for metacarpophalangeal joint arthritis. J Hand Surg Am 2007;32:1496-505.
5. Zhang H, Xue D, Yu J. Is Swanson prosthesis better than Sutter prosthesis for metacarpophalangeal joint arthroplasty? A meta-analysis. J Plast Surg Hand Surg 2015;49:45-51.
6. Massy-Westropp N, Krishnan J. Postoperative therapy after metacarpophalangeal arthroplasty. J Hand Ther 2003;16:311-4.
7. Mathiowetz V, Weber K, Volland G, Kashman N. Reliability and validity of grip and pinch strength

evaluations. J Hand Surg Am 1984;9:222-6.
8. Mathiowetz V, Weber K, Kashman N, Volland G. Adult norms for the nine hole peg test of finger dexterity. Occup Ther J Res 1985;5:24-38.
9. Düger T, Yakut E, Öksüz Ç, Yörükan S, Bilgütay BS, Ayhan Ç, et al. [Reliability and validity of the Turkish version of the Disabilities of the Arm, Shoulder and Hand (DASH) Questionnaire][Article in Turkish]. Turkish J Physiother Rehab 2006;17:99-107.
10. Linscheid RL. Implant arthroplasty of the hand: retrospective and prospective considerations. J Hand Surg Am 2000;25:796-816.
11. Squitieri L, Chung KC. A systematic review of outcomes and complications of vascularized toe joint transfer, silicone arthroplasty, and PyroCarbon arthroplasty for posttraumatic joint reconstruction of the finger. Plast Reconstr Surg 2008;121:1697-707.
12. Bellemère P. Pyrocarbon implants for the hand and wrist. Hand Surg Rehabil 2018;37:129-54.
13. Beckenbaugh RD. Preliminary experience with a noncemented nonconstrained total joint arthroplasty for the metacarpophalangeal joints. Orthopedics 1983;6:962-5.
14. Cook SD, Beckenbaugh RD, Redondo J, Popich LS, Klawitter JJ, Linscheid RL. Long-term follow-up of pyrolytic carbon metacarpophalangeal implants. J Bone Joint Surg Am 1999;81:635-48.

© 2018 Turkish Society for Surgery of the Hand and Upper Exremity. This is an open access article licensed under the terms of the Creative Commons Attribution NonCommercial ShareAlike 4.0 (https://creativecommons.org/licenses/by-nc-sa/4.0/) which permits unrestricted, noncommercial use, distribution and reproduction in any medium, provided the work is properly cited.