OLGU SUNUMU/CASE REPORT

Gülhane Tıp Derg 2012; 54: 302-305

© Gülhane Askeri Tıp Akademisi 2012

doi:10.5455/gulhane.30574

Multiple lung cysts and Birt-Hogg-Dube syndrome: management of anaesthesia and surgery

Esra Özer (*), Hasan Kutluk Pampal (*), Mehmet Dakak (**)

SUMMARY

Birt-Hogg-Dube syndrome is a rare autosomal dominant inherited disorder characterized by hair follicle hamartomas, renal tumors and spontaneous pneumothorax. We present a case of a patient with Birt-Hogg-Dube syndrome diagnosed after recurrent spontaneous pneumothoraces.

Key words: *Surgery, thoracic bullae, pneumothorax anaesthesia, ventilation*

ÖZET

Multipl akciğer kistleri ve Birt-Hogg-Dube sendromu: anestezi ve cerrahi yönetimi

Birt-Hogg-Dube sendromu saç foliküllerinin hamartomu, böbrek tümörleri ve spontan pnömotoraks ile karakterize, otozomal dominant geçişli nadir görülen bir hastalıktır. Olgumuzda, tekrarlayan spontan pnömotoraks nedeni ile Birt-Hogg-Dube sendromu tanısı alan hastadan bahsedilmektedir.

Anahtar kelimeler: *Cerrahi, torasik bül, pnömotoraks anestezi, ventilasyon*

Introduction

Birt-Hogg-Dube syndrome (BHDS) is a rare genodermatosis characterized by hair follicule hamartomas, renal tumors and spontaneous pneumothorax. The lung cysts in BHDS do not cause problems with breathing. There is an increased risk of spontaneous pneumothorax, which air leaking out of the lungs and into the chest. Spontaneous pneumothorax may result in a collapsed lung (1,2). We present the case of a 49-year-old man with bilateral multiple pulmonary cysts and recurrent pneumothorax who had typical skin lesions. On computed tomography, multiple bullae in both lungs were detected.

Case Report

A 49-year-old man weighing 85 kg and 170 cms tall, presented to our hospital with chest pain, short of breath, and a dry cough for 2 months. He had only 1 pack-year smoking history and had stopped smoking 3 years ago. He had a history of recurrent pneumothoraces which were relieved by insertion of chest tube drainage. Family anamnesis revealed a Birt-Hogg-Dube Syndrome (BHDS) in a member of his family. The affected family member was identified by the histologic examination of typical skin lesions diagnosed as fibrofolliculoma. No additional organ lesions was shown in the follow-up examinations of the family member. Genetic testing was also done to confirm the diagnose of BHDS. Our patient indeed had a 5-year history of papulous lesions on his neck and chin as described in the literature, which on skin biopsy was shown to be fibrofolliculoma (Fig 2) (1).

On admission, he was comfortable at rest but had

* TOBB ETU Hospital, Department of Anaesthesiology and Reanimation
**TOBB ETU Hospital, Department of Thoracic Surgery

Reprint request: Dr. Mehmet Dakak, TOBB ETU Hospital, Department of Thoracic Surgery, Sogutozu, Ankara, Turkey
E-mail: dakakmehmet@gmail.com

Date submitted: February 21, 2011 **Date accepted:** July 07, 2011 **Online publication date:** December 26, 2012

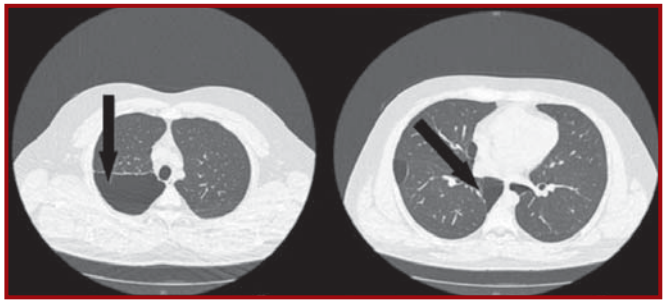

Figure 1. High-resolution computarized thorax tomography (HRCT). Bilateral multiple pulmonary cysts. Large bulla was seen on the right lower lobe of the lung.

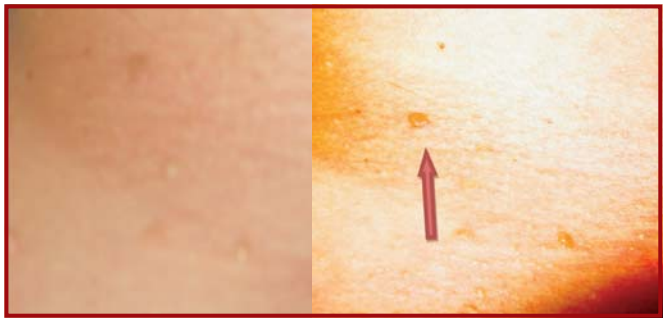

Figure 2. Papular skin lesion seen on the neck and chin.

dyspnea on physical activity. Chest radiography showed multiple focal radiolucent areas along the right heart border and at the right and left costophrenic angle. There was no pneumothorax. High-resolution computerized tomography of chest (HRCT) showed multiple bilateral cystic lesions of lung (Fig 1). The pulmonary lesions consisted of thin-walled cysts measuring 1-3 cm in diameter and involving mainly the right middle and upper lobes. Only a few cysts measuring 1-1.5 cm in diameter were seen in the lower lobe. Several cysts measuring 0.5-1 cm in diameter were present in the lingula and left lower lobe. No other abnormality was seen. A diagnosis of BHDS was made from clinical manifestations and family anamnesis in our patient.

Breath sounds was particularly diminished on the right lower lung on physical examination. The patient's vital signs were normal (Blood pressure 125/73 mmHg, heart rate 80/per min., oxygen saturation -SpO2 96%). Preoperative blood tests and pulmonary function test results including static lung volumes, expiratory flows, and carbon monoxide diffusing capacity were also normal.

3 mg^{-1} midazolam was given intravenously 5 minutes prior to surgery. Induction of total intravenous anaesthesia was initiated with 200 mg (2.5 $mg.kg^{-1}$) of intravenous propofol. The trachea was intubated after 0.6 $mg.kg^{-1}$ rocuronium bromide was given intravenously. A right-sided 37F double-lumen tube (Portex, Canterbury,UK) was inserted, its position was confirmed with bronchoscope and anaesthesia was maintained with 4-6 $mg.kg.h^{-1}$ propofol and 0.08-0.1$\mu g.kg.min^{-1}$ remifentanil infusion. The patient was allowed to breathe spontaneously, inhaling 40% air in 60% oxygen. With the patient in the left lateral position, independent lung ventilation was instituted. Synchronized intermittent mandatory ventilation (SIMV) was applied to both lungs with a resultant exhaled tidal volume of 0.6 L, 12/min.respiratory rate with no PEEP . The flow-volume and pressure-flow loop was monitored. The ventilator circuit was disconnected every 10 min to allow expiration of any trapped gases. After positioning the patient arterial blood gas was: PaO_2 134 mmHg, $PaCO_2$ 36 mmHg, and pH 7.41. End-tidal CO_2 was 32 mmHg.

Despite bilateral bullae, it was decided to do resection of the giant bullae only on the right lung to prevent the risk of inducing pneumothorax and lung collapse.

After a right posterolateral thoracotomy, a giant bullae appeared on the middle lobe of the right lung which was 10x7 cm in diameter (Fig 3) and multiple bullae located on the surface of the middle and upper lobes of the right lung with a diameter ranging 1-3 cms. The multiple localized small bullous lesions were resected by using GIA lineary stapler and were plicated by clips, minor bronchial openings were identified by underwater air leak and sutured with 3/0 prolene. Giant air cyst and solely located bullae were resected placing pense and suturing. The chest was closed over a single 32F chest tube drainage. Propofol and remifentanil infusion were discontinued, the patient was found to be conscious, pain-free, and breathing adequately. Arterial blood gas was: PaO_2: 205 mmHg, $PaCO_2$:36 mmHg, pH:7.36, and end-tidal CO_2 33 mmHg. The patient was extubated and the patient was supplemented with O_2 via a face mask. Deep-breathing and physiotherapy exercises were started soon after transfer to the intensive care unit.

Postoperative chest radiograph showed an expanded right lung. The patient was moved to the ward the next day. Postoperatively, intravenous morphine was administered at a rate of 1$mL.hr^{-1}$ through patient

controlled analgesia machine (PCA) for 3 days. The patient was discharged from the hospital on the 5th postoperative day. Computerized tomography scan was normal and no recurrent pneumothorax was detected one month after discharge fom hospital.

Discussion

Clinical and genetic studies suggest that BHDS patients may have a predisposition to renal malignancies, lung cysts and pneumothorax (1, 2). Spontaneous pneumothorax within the BHDS is caused by the rupture of pulmonary cysts. Patients with BHDS do not always have all three manifestations (skin, lung, and kidney), and sometimes have only multiple pulmonary cysts without any other features (4,5). Zbar et al. (4) confirmed the presence of subpleural and intraparenchmal cysts by HRCT scan in 83% out of 111 affected members of BHDS families. Based on previous reports, it appears that the majority of patients with BHDS have pulmonary cysts, which may develop earlier than the skin and renal manifestations. In this context, the detection of pulmonary cysts may be useful for early diagnosis of this syndrome. By the early detection of this syndrome, it will be possible to follow up the patients and their family with care to renal tumor and pneumothorax which can affect prognosis and quality of life.

Bullae are air-containing spaces within lung parenchyma, which result from destruction of alveolar tissue. Enlargement of bullae is the result of valve-like mechanism that permits air trapping within the bullae (6). Increased airway resistance,and compression of surrounding normal lung tissue by bullae could affect gaseous exchange. Operative mortality due to large bullae was 12% (7). A variety of surgical options for obliteration of bullae were described; segmetntal resection, lobectomy, plication and local excision were suggested as suitable techniques for selected cases with well localized lesions of various sizes (8). In our case, we chose to use lung parenchyma saving surgery to prevent lung compliance.

In these patients pulmonary function was lessen than 25% of predicted value. Thus, surgery results in deterioration of lung function and chest wall dynamics. Therefore, institution of positive-pressure ventilation may lead to rupture of bullae, life-threatening pneumothorax, and hypoxia. Thus, we used spotaneously breathing induction technique and double-lumen tracheal intubation. A double-lumen tube (DLT) is the method of choice for achieving pyhsiological lung seperation. Condition for safe intubation and positioning of DLT was achieved with propofol, short acting opioid and non-depolarizing neuromuscular blocking agent (rocuronium bromide). Manual ventilation is commenced cautiously, with small tidal volumes, low inspiratory pressures and prolonged expiratory phases to atmosphere. With such manoeuvres, hypoxaemia and hypotension were avoided during induction of anaesthesia. Although carbon dioxide retention occurs, this causes no harm because provided oxygenation is maintained at safe levels.

Respiratory rate, inspiratory flow, low PEEP, and FiO_2 should be adjusted to optimize oxygenation and carbon dioxide excretion while, in the patient with large bullae, simultaneously minimizing air leak. Essentially, it is not the technique but how and when it is applied, as any technique may be beneficial to the individual or phase of the surgical procedure. The basic rule is to avoid application of excessive pressure at any point during a respiratory cycle. Therefore, the safest starting point to use manual inflation applied cautiously and proceed to mechanical method with a

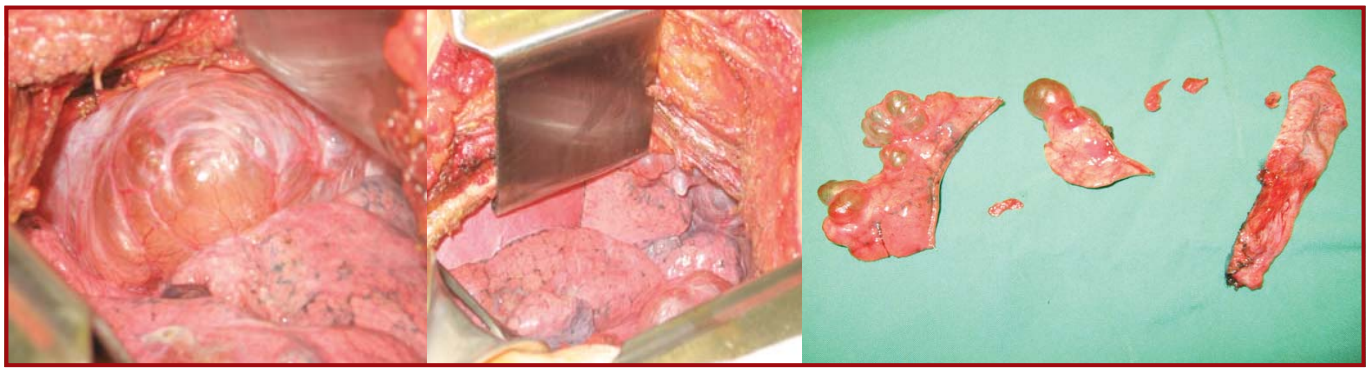

Figure 3. Surgical specimens. Large and small multiple bullae in the right lower lobe of the lung. Resected bullae specimens was demonstrated.

low frequency, low inspiratory pressure (< 20 cmH_2O) and expiration patterns without resistance (no PEEP). Early extubation is important to improve lung mechanics in these patients.

In summary, we describe a case of Birt-Hogg-Dube syndrome associated with multiple pulmonary cysts, an association of large bullae was also reported in the radiologic findings of the patient. Adequate pain relief and the patient's cooperation in chest physiotherapy can help to maintain pulmonary function and reduce pulmonary complications. The improved airflow and efficient pulmonary and chest wall mechanics performed with good anaesthetic management suggested to be a reason of good surgical success. Therefore, this case also highlights the fact that anaesthetic management and surgical manipulation of such cases are difficult.

References

1. Menko FH, Steensel MAM, Lennart SG,et al. Birt-Hogg-Dube syndrome:diagnosis and management (Review). Lancet Oncol 2009;10:1199-1206.
2. Kunogi M, Kurihara M, Shigihara I. Clinical and genetic spectrum of Birt-Hogg-Dube syndrome patients in whom pneumothorax and/or multiple lung cysts are the presenting feature.J Med Genet 2010;47:281-287
3. Khoo SK, Giraud S, Kahnoski K, et al. Clinical and genetic studies of Birt-Hogg-Dube syndrome. J Med Genet 2002;39:906-912.
4. Zbar B, Alvord WG, Glenn G, et al. Risk of renal and colonic neoplasms and spontaneous pneumothorax of the Birt-Hogg-Dubeube syndrome.Cancer Epidemiology Biomarkers Prev 2002;11: 393-400.
5. Schmidt LS, Nickerson ML, Warren MB, et al. Germline BHD-mutation spectrum and phenotype analysis of a large cohort of families with Birt-Hogg-Dube syndrome. Am J Hum Genet 2005;76(6):1023-1033.
6. Gunji Y, Akiyoshi T, Sato T, et al. Mutations of Birt-Hogg-Dube gene in patients with multiple lung cysts and reccurent pneumothorax. J Med Genet 2007;44(9):588-593.
7. Neema PK, Sinha PK, Varma PK, Rathod RC. Simultaneous repair of bilateral multiple emphysematous bullae with a secundum atrial septal defect. J Cardiothorac Vasc Anesth 2004;18: 632-636.
8. Andrews SN, Khrisnadas R, Berrisford RG, Froeschle PO. Pneumothorax and Birt-Hogg-Dube syndrome: daignostic and therapeutic aspects. Resp Med and Thoracic Surg 2007;7:18-20.