Accepted Article

DR. ZEYNEP TUNA (Orcid ID : 0000-0001-5139-2401)

Article type : Research Article

Cortical Motor Areas Show Different Reorganizational Changes in Adult Patients with Brachial Plexus Birth Injury (BPBI)

Zeynep TUNA, PhD. Gazi University Faculty of Health Sciences Department of Physiotherapy and Rehabilitation, Ankara, Turkey. zeyneptuna6@yahoo.com

Deran OSKAY, PhD Gazi University Faculty of Health Sciences Department of Physiotherapy and Rehabilitation, Ankara, Turkey deranoskay@yahoo.com

Oktay ALGIN, MD. Atatürk Education and Research Hospital Department of Radiology, Ankara, Turkey. droktayalgin@gmail.com

Orhan Murat KOÇAK, MD. Kırıkkale University Faculty of Medicine Department of Psychiatry, Kırıkkale, Turkey. orhanmuratkocak@gmail.com

Correspondence to Zeynep TUNA, PT, PhD. Gazi University Faculty of Health Sciences Department of Physiotherapy and Rehabilitation, 06500, Ankara, Turkey. E-mail: zeyneptuna6@yahoo.com Phone: +903122065016 Fax: +903122162636 ORCID: 0000-0001-5139-2401

Running title: Neuroplasticity in BPBI

Conflict of Interest: None.

This article has been accepted for publication and undergone full peer review but has not been through the copyediting, typesetting, pagination and proofreading process, which may lead to differences between this version and the Version of Record. Please cite this article as doi: 10.1002/JDN.10037

This article is protected by copyright. All rights reserved

Ethical Approval: Obtained with the record number 09.11.2015-57.

Patient Consent Statement: Patients gave consent before enrollment.

No materials were used from other resources.

Data Availability: None.

Acknowledgements: Zeynep Tuna received a bursary from The Scientific and Technological Research Council of Turkey (TUBITAK) during her doctoral education. This study is a part of her PhD thesis.

ABSTRACT

Introduction: Brachial plexus birth injury (BPBI) may cause permanent disability. It is recently thought to result from the (mal)adaptive reorganizational central nervous system problems.
Methods: In this study, adult patients with BPBI and age-matched healthy controls were compared for the cortical activity during action observation by functional magnetic resonance imaging (fMRI).
Results: The cortical activity in patients was significantly weaker than in the control group (p <0, 05). Areas of difference were middle temporal gyrus, premotor area and inferior parietal lobule. The signal change in these areas was significantly lower in the patient group (p<0, 05).
Conclusions: This study showed that the cortical activity in the associative motor regions was weaker in the patients while no primary region showed any difference. The results were concluded that there is a diversity in the neuroplastic changes between primary and associative motor areas. Clinically, neurorehabilitative interventions should be planned based on this diversity.
Keywords: brachial plexus birth injury, neuroplasticity, neurorehabilitation, action observation

INTRODUCTION

Brachial Plexus Birth Injury (BPBI) is a nerve traction injury during labor. It causes various functional impairments in the upper extremity depending on the severity of injury. Most children with BPBI recover spontaneously while up to 30% of them may suffer from permanent disability[1]. Those patients have functional limitations even through the adulthood. Recently, it has been claimed that the permanent disability in BPBI may originate from central problems rather than the

This article is protected by copyright. All rights reserved

Accepted Article

limited nerve regeneration or chronic musculoskeletal problems[2, 3]. Our clinical observations similarly show that, despite intensive therapies and surgical approaches, some patients still have suboptimal clinical outcomes which cannot be explained only with the problems in peripheral nerve regeneration. It appears that, they do not tend to use their affected upper limb in daily life although they score much better in the clinical assessments. It brings to mind whether there are problems other than musculoskeletal ones in those therapy-resistive patients.

Similar to our observations, Anguelova and colleagues reported that those patients may have central nervous system problems as they showed that automatic movements are more impaired in those patients compared to the voluntary ones in their study[2]. They interpreted these results that developmental apraxia is present in this patient population. The results of this study was also supported by an earlier electromyography study in which those patients showed partial re-innervation despite poor clinical outcome[3]. Results of both studies may be initiatives for investigating the (mal)adaptations within the central nervous system and thus, explain the underlying reasons for limited clinical recovery following BPBI in patients with permanent disability.[2,3] In other words, up-to-date point of view has shown that, not only peripheral nerve regeneration process but also neuroplasticity may affect the functional recovery after BPBI. However, despite the recent evolutions in the field, the neuroimaging studies investigating the neuroplastic changes after BPBI appear to be relatively poor. The neuroimaging studies seem to be limited to the cortical changes only after adult injuries, not the adults with birth palsies[4, 5]. Likewise, the only neuroimaging study in the BPBI population can be regarded as technically unsatisfactory as it did not include any kind of control group[6].

As the up-to-date point of view has raised that central nervous system is also affected in patients with BPBI, we decided to investigate the cortical changes in this patient population. We hypothesized that functional cortical activity in patients with BPBI would differ from that in the healthy population because of the maladaptive process due to insufficient input flow during early life. Therefore, the aim of this study was to assess the cortical activity in adult patients with BPBI by fMRI and make a comparison to the healthy controls.

MATERIALS AND METHODS

This study was carried out in corporation of a physiotherapy department and magnetic resonance imaging research centre. The study protocol was approved by the Gazi University

This article is protected by copyright. All rights reserved

Research Ethics Committee with the registration number 09.11.2015-57. All the participants gave their written informed consent before enrolment.

For the study, we retrieved the records of the patients who were treated in our clinic previously and discharged. Adult patients with upper trunk (C5-C6) involvement were called and invited to participate in the study. None of the patients we reached were receiving any therapy at the time of study. The inclusion criteria were being above 18 years old, involvement of upper trunk (C5-C6), a minimum of 5 years after the latest surgery and no history of any other neurologic or orthopaedic disorder. In addition, the patients that reported respiratory difficulty after birth were excluded. In the control group, the inclusion criteria were having no history of any neurologic diseases or upper extremity injuries. Individuals with any conditions limiting the appropriate positioning within the MRI scanner were also considered to be excluded.

In the first visit; age, gender, dominant side and any medical history of the participants were recorded. Additionally, affected side, level of injury, any surgical and physiotherapy history of the patients were also registered. They were functionally assessed according to the Modified Mallet Scale (MMS).[7] The second visit for scanning was scheduled at the first visit.

MMS is one of the most common scales in the assessment of patients with BPBI.[7] The scale is a physician-rated functional motor assessment tool. Patients are asked to perform some movements to assess the function of the shoulder and the elbow. For each subscale, a score of 0 represents no testability whereas a score of 5 is normal function. The lowest possible total score is 0 and the highest possible total score is 25.

The researchers completed a preparation step before the scanning procedure. This preparation step is explained in the following paragraphs.

Preparation before fMRI scanning

We planned to assess the cortical activity during performing the impaired movements of the patients and compare it to that of healthy people. However, upper trunk involvement results in functional impairment of shoulder and elbow movements which are limited in the cylinder of the scanner. The narrow cylindrical design of the scanner limited the proximal movements of the

This article is protected by copyright. All rights reserved

upper extremity. Therefore, we decided to use action observation method for functional imaging. For this reason, we prepared videos of the most impaired movements to show to the participants during scanning.

Action observation is one of the most recent methods for both assessment and training in the rehabilitative field. It is not only used as a therapeutic intervention in the neurological conditions but also in the cortical activity assessment in the neuroimaging studies.[8-11] This method is based on the finding that observation of a movement activates the brain regions similar to those activated during execution of that movement[12,13]. This phenomenon called *mirroring* and it is a function of mirror neurons found in the human premotor cortex, parietal lobules and superior temporal sulcus.[14] Based on this scientific background, we used action observation method in our study as the motor task because of the physical limitation due to the MRI scanner cylindrical design.

Video recording

The impaired movements after upper trunk injury are among the items of MMS (hand to mouth, hand to neck, global elevation, hand to back,…). Therefore, we decided to record the videos of a healthy individual performing the items of the MMS scale. This healthy individual was informed about the study and gave his consent for the use of his images in this study.

Before video recording, attention was paid on some important points that will optimize the participant's concentration. Firstly, the healthy model performed the movements with no mimics on his face. Secondly, the background colour was in contrast with his clothes to enhance the observer's attention. Thirdly, video recording was performed from an appropriate distance to the model to clearly see the whole movement range. When the video recording was completed, however, we realized that the total video duration was too long and thus the scanning session would be very exhausting for a single participant. For this reason, we decided to select only two mostly impaired movements (hand to mouth and hand to neck) to show during scanning (Figure 1a and b). After video recording, an experienced researcher (O.M.K.) placed the videos in a randomized manner within the MATLAB (MathWorks, USA) 14a program.

Scanning procedure

This article is protected by copyright. All rights reserved

All the participants laid in supine position inside the 3 Tesla MRI scanner (Tim Trio, Siemens, Germany) and integrated eyeglasses were placed over their head. The glasses provide the participants to see the screen behind them by mirrors while lying inside the scanner. It was checked before the start if they can see the monitor appropriately and feel comfortable after suitable supporting.

Before the start, participants were instructed to think about nothing else and concentrate on the video. An emergency button was provided for any unusual condition. Both structural and functional imaging were performed consecutively within the same scanning session. The technical features for T1-weighted structural imaging were as follows: repetition time/echo time: 2130/3.45; number of slices: 208; section-thickness of the slices: 0.8 mm; field of view: 230x230 mm; matrix size: 128x128 and flip angle: 8°. After structural imaging, 4 sessions of 20 blocks were performed. At each session, there were 5 different videos. Four videos included two movements of each side (right and left) and the fifth video was a picture of the healthy model in a neutral position (baseline condition) (Figure1c). Each video was repeated for 5 times in a randomized manner. The technical features for functional imaging (gradient-echo blood oxygen level dependent imaging) were as follows: repetition time/echo time: 3000/30; number of slices: 35; voxel size: 3 x 3 x 3mm; field of view: 192 x 192 mm; matrix size: 64 x 64 and flip angle: 90°.

Data analysis

Statistical Parametrical Mapping 12 (Wellcome Department of Cognitive Neurology, London, UK) was used for data analysis. Pre-processing consists of placement of the structural image on the Montreal Neurologic Institute (MNI) coordinates, slice timing, realignment, co-registration, normalization and smoothing (9 mm full width half maximum) steps consecutively.

In the first level analysis, each movement of each side was contrasted to the other four conditions. Results of these all four contrasts were included in the full factorial design in the second level analysis. In this whole brain analysis, conditions were group (patient vs. control) and side of the movement in the video (left vs. right). Cluster size larger than ten voxels and family wise error-corrected p-value < 0.05 for cluster-level was accepted threshold for significance.

This article is protected by copyright. All rights reserved

After determination of significant clusters in whole brain analysis, region of interest analysis was also performed. Spherical method with a 6 mm-radius was used to determine the region of interests. Percent of signal change relative to the baseline condition of each region of interest was compared between the groups (patients vs controls).

Statistical Analysis

The results were given as median ± interquartile range. Since small sample size, the categorical variables were given for each participant individually in tables. Mann-Whitney-U test was used to compare the percent of signal change of each region of interest. Level of $p<0.05$ with 95% CI was accepted as significant for analysis.

RESULTS

Ten patients were evaluated at the first visit. Three of them were under 10 years old and one underwent a forearm surgery 2 months ago. Finally, a total of 6 patients were included in the study. One patient was excluded at the data analysis step due to her dental brace. Therefore, the analyses were performed with 5 patients and 5 healthy age-matched controls (Figure 2).

Age, gender and dominant side of each participant were given in Table 1. The age of the patients varied between 20 and 39 while the control group similarly between 20 and 36 years old. The gender distribution was also similar between the patients and controls. Each group included only one male participant. All the patients had right side involvement. Only one patient had right side dominance despite same (right) side involvement (Table 1 and 2). Table 2 also shows the clinical scores of "hand to mouth" and "hand to neck" movements of the MMS.

Figure 3 shows the brain areas that were activated significantly more in the healthy control group. These regions were the left midtemporal gyrus (Broadmann Area 39), the inferior parietal lobule (Broadmann Area 40) and the premotor area (Broadmann Area 6). In the control group, cluster size, T/F statistical value and MNI coordinates of those areas were shown in Table 3. There was neither significant effect of the side (right vs left) of the movement nor group-side interaction.

Region of Interest (ROI) analysis also confirmed that the control group had significantly higher activity in these regions when compared to the patient group (Table 4). Results showed that

This article is protected by copyright. All rights reserved

Accepted Article

the percent of the signal change of all ROIs in the patients were lower than those in the controls ($p<0.05$).

DISCUSSION

Central nervous system changes have recently been reported to occur in patients with BPBI[2, 3]. The preliminary results in this study also confirmed that visually triggered cortical activity is significantly weaker in those patients than that in age-matched healthy population. Action observation of the most impaired movements (hand to neck and hand to mouth) seemed to trigger less activation in the contralateral hemisphere in adult patients with BPBI. Watching the movements of either right or left side appeared not to differ regarding the brain activity.

Observation of an action is well-known to activate the same brain regions as the real motor performance does[12, 13]. For this reason, action observation is a suitable method for functional brain imaging of the individuals with physical disabilities.[14] Observing a movement rather than performing it can not only eliminate the compensatory muscle activation during imaging but also avoids any undesirable head motion that can blunt the magnetic resonance images. For this reason, in a previous study, researchers instructed the patients to perform the movement and scanned the patient immediately after the movement[6]. However, none of the studies so far assessed the real-time brain activity. To our knowledge, despite the small number of patients, this is the first study that used the action observation method for to assess the real-time cortical activity via functional brain imaging in this population. By using this method, we could assess simultaneous functional brain activity during observation of the movements.

The most striking result of this method in our study was that the associative motor areas were activated more weakly in the patient group while the activation was similar in the primary motor areas in both groups. This result was concluded that central programming of the movements which is organized in the associative brain regions seems to be impaired in this patient population[15-17]. Despite, motor execution of the movements which is represented in the primary areas looks normal or maybe compensated. In other words, these patients could not activate the representative areas enough despite watching the correct pattern of the movement. Therefore, impaired central motor programming was thought to be at least partly responsible for this insufficient cortical activity of the associative areas. In parallel to our interpretation, a previous

This article is protected by copyright. All rights reserved

study also reported that central motor programming is deficient in the patients with BPBI[2]. They showed that those patients did not use their affected arm well during an automatic movement (catching a ball) while they could move that arm well when they were instructed to do so. The authors of the study interpreted their results as a consequence of deficient central motor programming[2].

Different from BPBI, patients with hereditary neuropathy showed similarity regarding the cortical activity compared to the adults with acquired neuropathy[18]. They concluded that early cortical reorganization resulted in compensatory changes at very early ages in the hereditary disease. [18] In BPBI, the infant has to grow up into adulthood with a damaged peripheral nerve and thus with decreased impulse flow. Therefore, motor programming develops insufficiently and maladaptive cortical changes occur. We think that the weaker activity in the representative motor areas in our patient group is also a result of such a maladapted motor programming.

We are not sure whether the difference in the dominant sides of the patients and controls would make an impact on the results. To minimize this possibility, we showed the movements of both sides in the videos. In addition, only the left hemisphere (contralateral to the affected limb) showed difference regarding activity although the patients watched movements of both sides. Anyway, it is necessary to evaluate the impact of the dominant side in further studies.

We are aware that the results of our study should be interpreted cautiously due to our very small sample size. We would like to explain the two main reasons for this limitation. Firstly, we planned to assess the adult patients for their steady neural organization, however, those patients mostly give up treatment through the adulthood and they are loss to follow-up. Therefore, we could reach a small number of patients. Secondly, the adult patients were either university students in different cities or employed individuals in a full-time work. Therefore, some of the invited patients refused to participate in the study due to work, school or travel issues. Consequently, we had to carry out the study with a very small sample size. Even so, we used valid and reliable methods and equipment and also senior author was a very experienced researcher in the neuroimaging field. Anyway, it is clear that larger sample sizes are needed to confirm our preliminary results.

This article is protected by copyright. All rights reserved

Clinically, keeping the cautious approach to our results in mind, we suggest that the planning of the neurorehabilitative therapies should be cortex-targeting. Also, we recommend to take the difference in the neuroplastic changes between the primary and associative brain areas into account during treatment. As the associative areas which are activated weakly in those patients include mirror-neuron system, neurorehabilitative methods should target to stimulate this mirroring function. Thereby, the motor repertoire of the associative areas can be improved or at least maintained. In conclusion, prevention of the maladaptive changes or (re)shaping of the cortical reorganization may contribute to the outcomes of the surgical and therapeutic interventions which are often suboptimal.

Author Contributions:
ZT: study design, patient enrolment and manuscript preparation
DO: study design, interpretation of the results and manuscript editing
OA: data collection, interpretation of the results and manuscript editing
OMK: data analysis and interpretation and manuscript editing

REFERENCES

1. van Dijk JG, Pondaag W, Malessy MJ. Obstetric lesions of the brachial plexus. Muscle Nerve 2001; 24: 1451-61.
2. Anguelova GV, Malessy MJ, Buitenhuis SM, van Zwet, EW, van Dijk, JG. Impaired Automatic Arm Movements in Obstetric Brachial Plexus Palsy Suggest a Central Disorder. J Child Neurol 2016; 31: 1005-9.
3. Khu KJ. Neuroplasticity and Brachial Plexus Injury. World Neurosurg 2015; 84: 1509-10.
4. Bjorkman A, Weibull A, Svensson H, Dahlin L. Cerebral Reorganization in Patients with Brachial Plexus Birth Injury and Residual Shoulder Problems. Front Neurol 2016; 7: 240.
5. Liu B, Li T, Tang WJ, Zhang JH, Sun HP, Xu WD, et al. Changes of inter-hemispheric functional connectivity between motor cortices after brachial plexuses injury: a resting-state fMRI study. Neuroscience 2013; 243: 33-9.

This article is protected by copyright. All rights reserved

6. Yoshikawa T, Hayashi N, Tajiri Y, Satake Y, Ohtomo K. Brain reorganization in patients with brachial plexus injury: a longitudinal functional MRI study. Scientific World Journal 2012; 501751.
7. Al-Qattan MM, El-Sayed AA. Obstetric brachial plexus palsy: the mallet grading system for shoulder function-revisited. Biomed Res Int 2014; 398121.
8. Alsamour M, Gilliaux M, Renders A, Stoquart G, Edwards MG. Does observation of a disabled child's action moderate action execution? Implication for the use of Action Observation Therapy for patient rehabilitation. Cortex. 2018; 107: 102-109.
9.Borges LR, Fernandes AB, Melo LP, Guerra RO, Campos TF. Action observation for upper limb rehabilitation after stroke. Cochrane Database Syst Rev. 2018 Oct 31; 10:CD011887
10.Gueugneau N, Bove M, Ballay Y, Papaxanthis C.Interhemispheric inhibition is dynamically regulated during action observation. Cortex. 2016; 78: 138-149
11.Mizuno J, Kawamura M, Hoshiyama M. Brain Activity on Observation of Another Person's Action: A Magnetoencephalographic Study. Motor Control. 2018; 1; 22(4): 377-390.
12. Buccino G, Binkofski F, Fink GR, Fadiga L, Fogassi L, Gallese V, et al. Action observation activates premotor and parietal areas in a somatotopic manner: an fMRI study. Eur J Neurosci 2001; 13: 400-4.
13. Gazzola V, Keysers C. The observation and execution of actions share motor and somatosensory voxels in all tested subjects: single-subject analyses of unsmoothed fMRI data. Cereb Cortex 2009; 19: 1239-55.
14. Rizzolatti G, Fogassi L, Gallese V. Neurophysiological mechanisms underlying the understanding and imitation of action. Nat Rev Neurosci 2001; 2: 661-70.
15. Prechtl HF, Hopkins B. Developmental transformations of spontaneous movements in early infancy. Early Hum Dev 1986; 14(3-4): 233-8.
16. Casartelli L, Federici A, Cesareo A, Biffi E, Valtorta G, Molteni M, et al. Role of the cerebellum in high stages of motor planning hierarchy. J Neurophysiol 2017; 117: 1474-82.
17. Serrien DJ, Sovijarvi-Spape MM, Rana G. Developmental changes in motor control: insights from bimanual coordination. Dev Psychol 2014; 50: 316
18. Rocca MA, Valsasina P, Fazio R, Previtali SC, Messina R, Falini A, et al. Brain connectivity abnormalities extend beyond the sensorimotor network in peripheral neuropathy.
Hum Brain Mapp 2014; 35: 513-26.

This article is protected by copyright. All rights reserved

Figure Legends:

Figure 1: The video image of the healthy model performing hand to mouth (a) and hand to neck (b) movements and baseline condition (c)

Figure 2: Flowchart of patient enrollment to the study

Figure 3: The regions of the main effect of group in full factorial analysis

Accepted Article

This article is protected by copyright. All rights reserved

Table 1: Age, gender and dominant side of each participant

N of patient	Age	Gender	Dominant side
I	39	M	L
II	25	F	L
III	21	F	L
IV	20	F	L
V	22	F	R
N of control			
I	36	M	R
II	27	F	R
III	22	F	R
IV	20	F	R
V	22	F	R

Accepted Article

This article is protected by copyright. All rights reserved

Accepted Article

Patient no	Affected side	"Hand to mouth" score	"Hand to neck" score
I	R	3	3
II	R	4	4
III	R	2	5
IV	R	3	4
V	R	4	3

Table 2: Affected side and Mallet subscore of "hand to mouth" and "hand to neck" movements of each patient

This article is protected by copyright. All rights reserved

Accepted Article

Table 3: Cluster size, T/F statistical value and MNI coordinates of the differently activated cortical areas

		MNI Coordinates				
Cluster size	**T/F Stat**	**X**	**Y**	**Z**	**Broadmann Area**	**Region**
117	62.90113	-45	-58	11	39	Left Midtemporal Gyrus
34	44.90681	-50	-26	32	40	Left Inferior Parietal Lobule 1
28	40.2583	-50	-6	48	6	Left Premotor Area
14	35.91851	-28	-40	36	40	Left Inferior Parietal Lobule 2

MNI: Montreal Neurologic Institute

This article is protected by copyright. All rights reserved

Accepted Article

Table 4: Results of Region of Interest analysis of the four clusters of main effect of group

	PATIENTS (med±IQR)	**CONTROLS (med±IQR)**	**p**
Midtemporal Gyrus	0,025 (0,001-0,003)	0,090 (0,0375-0,0975)	0,021
Inferior Parietal Lobule 1	0,000 (-0,0025-0,0025)	0,03 (0,017-0,052)	0,017
Premotor Area	0,015 (0,015-0,030)	0,045 (0,003-0,006)	0,041
Inferior Parietal Lobule 2	-0,005 (-0,02-0,01)	0,035 (0,002-0,006)	0,012

IQR: interquartile range

This article is protected by copyright. All rights reserved

Accepted Article



jdn_10037_f1.jpg

This article is protected by copyright. All rights reserved

Accepted Article

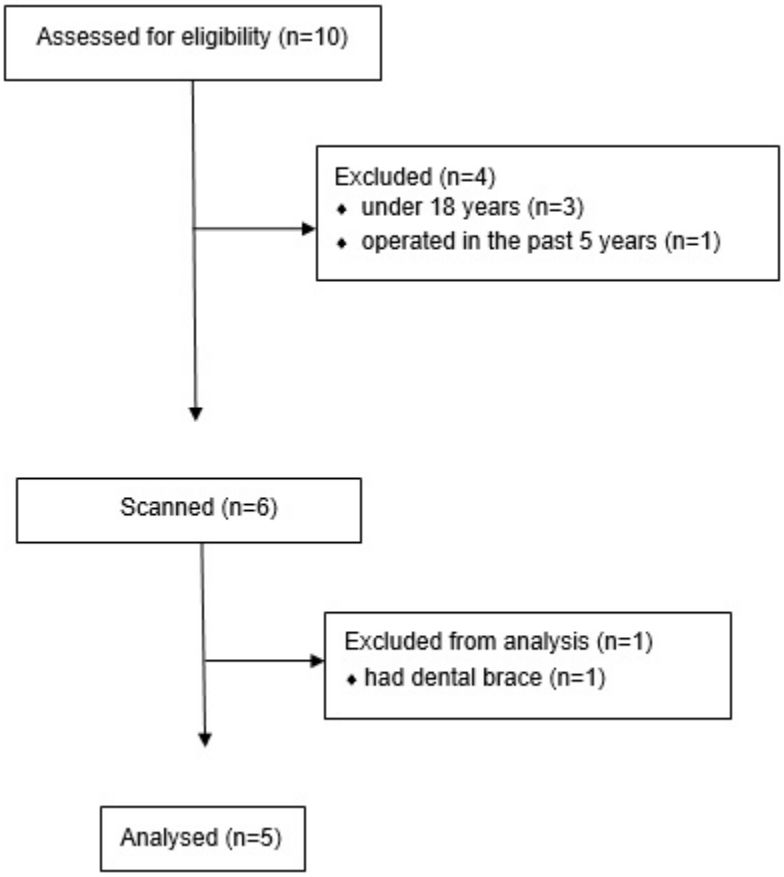

jdn_10037_f2.jpg

This article is protected by copyright. All rights reserved

Accepted Article

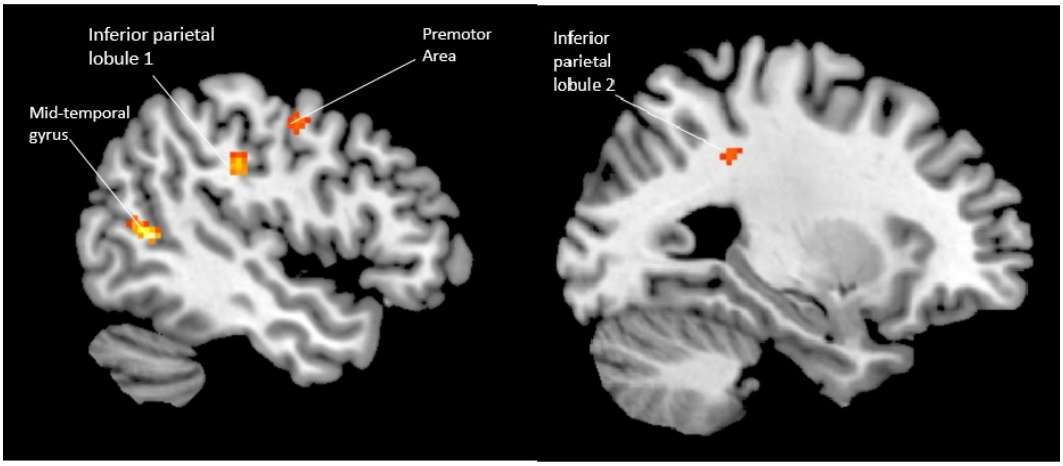

jdn_10037_f3.jpg

This article is protected by copyright. All rights reserved