Pain Medicine 2015; 16: 1643–1649
Wiley Periodicals, Inc.

LETTERS TO THE EDITOR

Heterotopic Ossification and Peripheral Nerve Entrapment: Ultrasound is a Must-use Imaging Modality

Dear Editor,

Heterotopic ossification (HO) —new lamellar bone formation in a place where normally osseous tissue does not exist—is commonly seen around the hip joints [1]. It is relatively a frequent complication after traumatic brain injury (TBI). HO can present with pain, swelling, local warmth, tenderness, and decrease in range of motion. In addition, nerve or vascular entrapments can develop depending on the location of the ossified tissue [2,3].

A 25-year-old man was seen due to stiffness in his right hip and elbow joints, and weakness, numbness, and tingling (in his right thigh and forearm). He had suffered TBI and distal humerus fracture 4 months ago due to a motor-vehicle accident. Physical examination revealed restriction in the right hip and elbow motions, right-hand interosseous muscle atrophy, hypoesthesia in the right ulnar and sciatic nerve dermatomes. Radiographs showed HO around the right hip and callus formation in the right elbow (Figure 1A,E). Thereafter, ultrasound (US) imaging clearly demonstrated the sciatic nerve entrapment by the HO and the ulnar nerve entrapment by the callus tissue (Figure 1B–D). Electrodiagnostic tests confirmed the (Figure 1F) ulnar and sciatic nerve entrapments (severe subacute axonal injuries). The patient was referred to orthopedic surgery and was also called for follow-up visits.

Salga et al. [4] have previously described sciatic nerve compressions by HO. They concluded that the diagnosis should be based on clinical examination and computed tomography but that electroneuromyography was not sensitive enough. Conversely, owing to its several advantages (inexpensive, lack of ionizing radiation, repeatable,

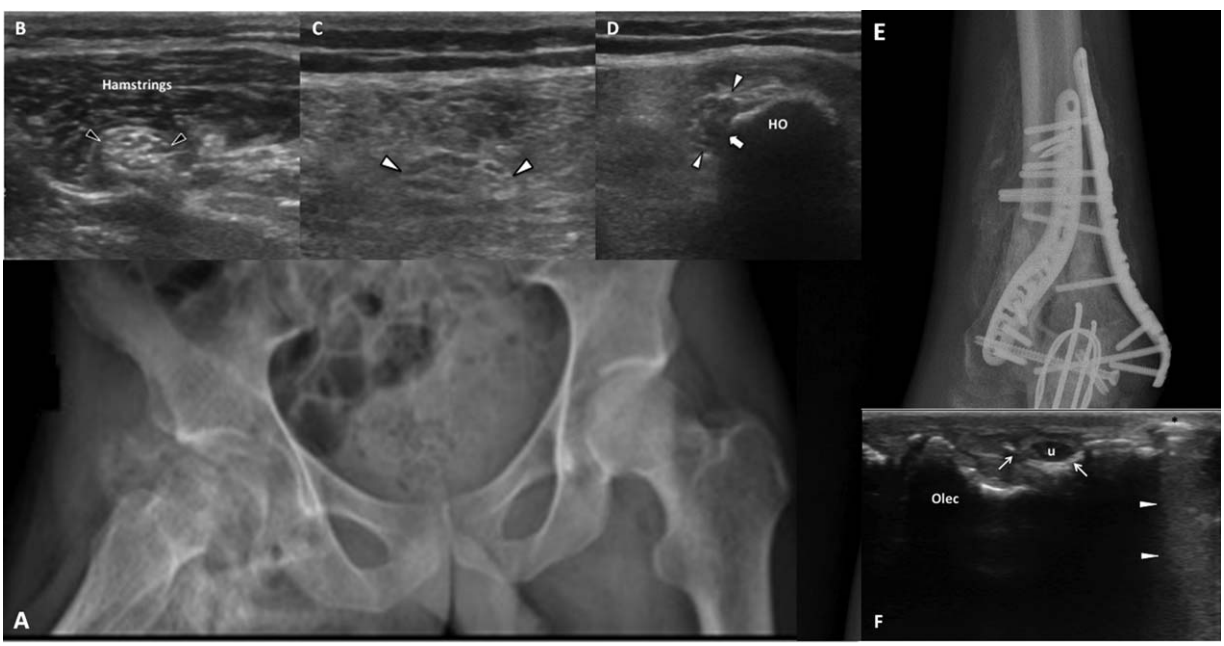

Figure 1 Antero-posterior radiographs show HO around the right hip (A) and callus formation proximal to the right elbow (E). US imaging (axial view) shows irregular osseous tissue (white arrows) underlying and compressing the ulnar nerve (F). Please note the nearby metallic pin (asterisk) giving a comet tail artifact (arrowheads). Comparative sciatic nerve US imaging (axial views). Although the nerve is visualized as normal (black arrowheads) on the left side (B), the right sciatic nerve (white arrowheads) is swollen with hypoechoic and enlarged fascicles on the right side (midthigh) (C). Proximally, the nerve is also seen to be compressed (arrow) due to the HO (D).

Downloaded from https://academic.oup.com/painmedicine/article/16/8/1643/2460790 by Gazi Universitesi user on 02 October 2023

convenient, and patient-friendly) the role of US imaging is well established for peripheral nerve pathologies, HO or fracture healing [3,5]. Yet, it can sensitively depict the ossification and related soft tissue changes even during the early period when radiographs are negative [6]. For peripheral nerve entrapments, the typical findings would be nerve flattening at the site of compression and swelling usually proximal to it [5]. Likewise, in our patient, the HO in the right hip, callus formation in the right elbow and the pertinent nerve entrapments could have been simultaneously demonstrated by US imaging.

In conclusion, we would like to underscore once again the paramount and convenient role of US scanning for various musculoskeletal complications during the follow-up of patients in the rehabilitation settings [7].

Murat Kara, MD,* Timur Ekiz, MD,* Gökhan Tuna Öztürk, MD,* Şule Şahin Onat, MD,* and Levent Özçakar, MD†
*Ankara Physical Medicine and Rehabilitation Training and Research Hospital;
†Hacettepe University Medical School, Department of Physical and Rehabilitation Medicine, Ankara, Turkey

Reprint requests to: Timur Ekiz, MD, Türkocağı St No: 3 Sıhhiye, 06230 Ankara, Turkey. Tel: 90 312 310 32 30; Fax: 90 312 311 80 54; E-mail: timurekiz@gmail.com

Conflict of interest: None
Authors disclosure and funding: None

References

1 Kara M, Ekiz T, Sarıkaya FG, Demir SO, Özçakar L. Severe bilateral heterotopic ossification in a patient with multiple sclerosis. Rehabil Nurs, in press.

2 Ekiz T, Yetişgin A, Yıldızgören MT, Onat SS. Pain associated with heterotopic ossification: Does it have a neurogenic component as well. Pain Physician 2014;17:E793.

3 Kara M, Yalçın S, Yenigün D, et al. Heterotopic ossification and cubital tunnel syndrome in traumatic brain injury: Ultrasound 'sees' both. J Back Musculoskelet Rehabil, in press.

4 Salga M, Jourdan C, Durand MC, et al. Sciatic nerve compression by neurogenic heterotopic ossification: Use of CT to determine surgical indications. Skeletal Radiol 2015;44:233–40.

5 Özçakar L, Kara M, Chang KV, et al. Nineteen reasons why physiatrists should do musculoskeletal ultrasound: EURO-MUSCULUS/USPRM Recommendations. Am J Phys Med Rehabil, in press.

6 Ekiz T, Yıldızgören MT, Yetişgin A. Musculoskeletal ultrasound by-passes the diagnostic and radiological challenges in heterotopic ossification. Singapore Med J 2014;55:604.

7 Özçakar L, Carli AB, Tok F, et al. The utility of musculoskeletal ultrasound in rehabilitation settings. Am J Phys Med Rehabil 2013;92:805–17.

Two Virtual Reality Pilot Studies for the Treatment of Pediatric CRPS

Dear Editor,

The following letter describes two pilot studies testing the feasibility of immersive virtual reality therapy on pediatric patients with unilateral lower limb complex regional pain syndrome (CRPS). In these studies, patients completed target-hitting tasks in virtual reality using novel avatar bodies. Patients completed all sessions without adverse effects and both patients and parents were enthusiastic about the treatment. We discuss how function was tracked within and across sessions, and next steps.

Because virtual reality (VR) replaces sensory information from the physical world, users may partially replace their sense of presence in the physical world, or in their physical body. This quality of presence was first used to treat pain using distraction [1] and has also been used to produce relaxation or increased engagement (e.g., in physical therapy). A second quality that may be utilized in pain treatment is flexibility: the ability to change the relationship between a participant's appearance and/or actions in the physical world, and the appearance and actions that this participant perceives virtually [2]. Leveraging the flexibility of virtual reality allows the creation of avatars whose movements differ from that of the participants' own, allowing more radical interventions than mirroring the unaffected limb. Following Lanier's concept of homuncular flexibility [3], researchers have demonstrated that users can learn to identify with avatars that have very different bodies [4] and learn to control these avatars very rapidly [5]. We propose that using such novel bodies may also be therapeutic for pain.

Methods

Four patients with pediatric CRPS, confirmed by Budapest Criteria [6], were enrolled in this study, after institutional review board (IRB) approval, consent, and assent. All patients were receiving concurrent multidisciplinary therapy including physical and occupational

Downloaded from https://academic.oup.com/painmedicine/article/16/8/1643/2460790 by Gazi Universitesi user on 02 October 2023