BMC Anesthesiology

RESEARCH

Open Access

Comparison of the analgesic efficacy of ultrasound-guided superficial serratus anterior plane block and intercostal nerve block for rib fractures: a randomized controlled trial

Musa Zengin[1*], Onur Küçük[2], Muhyettin Aslan[3], Göktürk Fındık[4] and Ali Alagöz[2]

Abstract

Background Various regional analgesic methods are frequently incorporated into multimodal analgesia strategies for managing rib fractures. This study aimed to compare the analgesic efficacy of ultrasound-guided superficial serratus anterior plane block (S-SAPB) and intercostal nerve block (ICNB) in patients with isolated rib fractures.

Methods This randomized controlled trial included patients aged 18–65 years with unilateral isolated rib fractures (≤ 6 ribs) resulting from trauma. Patients underwent ultrasound-guided S-SAPB (20 ml 0.25% bupivacaine) or ICNB (3 ml 0.25% bupivacaine for each fractured rib). Pain levels were assessed using the Visual Analogue Scale (VAS) both prior to the procedure (Pre-Block, (T0)) and at specific time points following the intervention: 1st hour (T1), 2nd hour (T2), 4th hour (T4), 8th hour (T8), 16th hour (T16), and 24th hour (T24). The changes in observed values over time were expressed as delta (Δ).

Results Both S-SAPB and ICNB provided effective analgesia. In the first 4 h, ICNB demonstrated a greater reduction in VAS scores, particularly in patients with 10th and 11th rib fractures. However, S-SAPB resulted in significantly longer-lasting analgesia, with greater pain relief after 8 h (T8–T24) compared to ICNB ($p < 0.05$). Patients in the S-SAPB group required no additional analgesia, whereas 43.3% of ICNB patients required supplemental tramadol ($p < 0.001$). Both techniques were well tolerated, with no reported complications.

Conclusions S-SAPB provides prolonged analgesia and may be preferable for managing rib fracture pain beyond the initial 8 h. However, ICNB offers superior pain relief in the early postoperative period, especially for lower rib fractures (10th–11th ribs). A combined approach that includes both blocks may optimize pain control in patients with multiple rib fractures involving the 10th and 11th ribs.

Keywords Intercostal nerve block, Pain, Plane blocks, Rib fracture, Serratus anterior plane block, Trauma

*Correspondence:
Musa Zengin
musazengin@gmail.com
Full list of author information is available at the end of the article

© The Author(s) 2025. **Open Access** This article is licensed under a Creative Commons Attribution-NonCommercial-NoDerivatives 4.0 International License, which permits any non-commercial use, sharing, distribution and reproduction in any medium or format, as long as you give appropriate credit to the original author(s) and the source, provide a link to the Creative Commons licence, and indicate if you modified the licensed material. You do not have permission under this licence to share adapted material derived from this article or parts of it. The images or other third party material in this article are included in the article's Creative Commons licence, unless indicated otherwise in a credit line to the material. If material is not included in the article's Creative Commons licence and your intended use is not permitted by statutory regulation or exceeds the permitted use, you will need to obtain permission directly from the copyright holder. To view a copy of this licence, visit http://creativecommons.org/licenses/by-nc-nd/4.0/.

Background

Thoracic injuries encompass a wide range of conditions, from simple contusions and rib fractures to open thoracic trauma [1]. However, the most common condition requiring hospitalization is blunt trauma with rib fractures, which is often accompanied by severe pain [2]. This type of pain often requires hospitalization due to the potential risk of respiratory and hemodynamic complications in many patients [3]. Inadequate pain management significantly elevates the risk of respiratory complications in patients with rib fractures [4, 5]. Poor pain control can result in exacerbation of acute lung injury, basal atelectasis, the necessity for non-invasive or invasive mechanical ventilation, extended hospital stays, and a subsequent rise in overall treatment costs [6, 7].

Systemic analgesics are the primary treatment for pain associated with rib fractures; however, their effectiveness is often limited. Nonsteroidal anti-inflammatory drugs (NSAIDs) are cost-effective and generally well-tolerated but are associated with risks such as acute kidney injury and an increased likelihood of bleeding, which can limit their use [8]. Opioid analgesics are linked to substantial side effects, such as sedation, respiratory depression, and hypotension, with these risks being particularly pronounced in elderly patients. Additionally, opioid-related side effects exacerbate the risk of developing atelectasis [9]. Regional analgesia, as a component of multimodal analgesia, offers effective pain control [2]. Techniques commonly utilized for managing rib fractures include thoracic epidural analgesia (TEA), thoracic paravertebral block (TPVB), intercostal nerve block (ICNB), intrapleural block, and various fascial plane blocks (Erector spinae plane block (ESPB), Rhomboid Intercostal and Sub-Serratus (RISS) block, etc.) [1, 10–14]. Moreover, considering the area of effect of the SPSIPB technique described by Tulgar et al., SPSIPB may be a potential alternative plane block for effective analgesia in rib fractures [15]. While TEA is highly effective for managing pain associated with rib fractures, its success and application are highly dependent on the clinician's expertise. Moreover, TEA carries risks, such as epidural hematoma [16] and secondary infection [17]. TPVB has a failure rate that can reach 10%, with potential complications including pleural puncture, vascular puncture, hypotension, and abnormal spread of the local anesthetic (LA) agent [18]. ICNB involves the injection of 3–5 mL of LA into the intercostal space at each designated level [19]. Studies have identified ICNB as an effective method for analgesic management in patients with rib fractures [1]. The superficial serratus anterior plane block (S-SAPB), first described by Blanco et al. in 2013, primarily targets the cutaneous branches of the intercostal nerves, as well as the thoracicus longus and thoracodorsal nerves [20, 21]. In their study, Blanco et al. [21] reported the occurrence of sensory block in the anterolateral and posterior chest wall within the T2-T9 dermatome following S-SAPB, and a loss of muscle strength was observed. S-SAPB generally has a low occurrence of side effects, including nausea, hypotension, and LA systemic toxicity (LAST) [22]. Several studies have shown that S-SAPB is comparable to, or even superior to, other techniques in thoracic surgery cases [23, 24]. Although the application of the S-SAPB for managing rib fractures is limited in the current literature, there are studies conducted especially in the emergency department [25, 26]. In these studies, it has been demonstrated the effectiveness of the S-SAPB for analgesic management in cases of multiple rib fractures, (including 10th, 11th, 12th ribs) [25, 26].

This study hypothesizes that there is no significant difference between the analgesic efficacy of ultrasound-guided S-SAPB and ICNB in the management of pain in patients with isolated multiple rib fractures. Specifically, the study aims to compare the effects of both techniques on pain scores, additional analgesic consumption, and patient satisfaction over a 24-h period.

Materials and methods

Study design

This prospective, randomized, assessor-blind study was conducted following approval from the Ankara Bilkent City Hospital Clinical Research Ethics Committee on December 1, 2021, under protocol number "E.Kurul-E1-21–2143." The study was registered in the international protocol registration and results system "ClinicalTrials.gov" under registration number "NCT05160155." All procedures adhered to the ethical standards of the institutional research committee, the 1964 Helsinki Declaration (revised in 2013), and subsequent amendments or comparable ethical standards. The article complies with the CONSORT guidelines for reporting clinical trials.

Participants

Patients aged 18–65 years with unilateral isolated rib fractures (involving six or fewer ribs) caused by trauma, a body mass index (BMI) of 18–30 kg/m^2, and classified as American Society of Anesthesiologists (ASA) physical status I-III were enrolled in the study conducted between December 2021 and December 2022. Exclusion criteria included: patients who did not consent to participate, those who requested withdrawal from the study, patients with rib fractures in both hemithoraxes, individuals allergic to the LAs used in the study, patients with infections at the intervention site, those with dementia/cognitive impairment, patients with bleeding disorders, and individuals with a history of chronic corticosteroid or opioid

use. Patients who fulfilled the inclusion criteria were included in the study after giving written informed consent. The patients were monitored in the thoracic surgery intensive care unit throughout the study. All data were gathered by an independent researcher who was blinded to the randomization process and the block application. Patient registration and allocation were conducted in accordance with the CONSORT checklist (Fig. 1).

Interventions

Upon admission to the thoracic surgery clinic for isolated rib fractures due to trauma, patients received either S-SAPB or ICNB in addition to the standard analgesia protocol. The patients were monitored for 24 h. All patients were administered 1 mg of intravenous (IV) midazolam for sedation after venous access was established. Electrocardiogram, pulse oximetry, and noninvasive blood pressure measurements were continuously monitored and documented. All block applications were administered by the same anesthesiologist.

Standard analgesia protocol

All patients were given 1 g of acetaminophen three times a day and 50 mg/2 mL of dexketoprofen twice a day as part of the standard IV analgesia protocol. During the follow-up period, IV tramadol was administered as "additional analgesic" at a dose of 0.5 mg/kg (in increments of 5 mg, not exceeding the calculated dose based on the patient's weight) if the resting visual analog scale (VAS) score was 4 or higher. Additional analgesia was provided only during follow-up periods based on the VAS score recorded during clinical assessments. The total amount of tramadol administered as additional analgesia was recorded.

Block procedures

Under strict aseptic conditions for all patients, block procedures were performed using a high-frequency 6 to 18 MHz linear probe (SonoHealth Guangzhou, SonoHealth Medical Technologies Co. Ltd., China) and a US-compatible 22-gauge, 8 cm nerve block needle (Pajunk, SonoPlexSTIM, Germany).

Superficial Serratus Anterior Plane Block (S-SAPB)

S-SAPB was performed following the technique described by Blanco et al. [21] with the patient in the lateral decubitus position and the traumatized hemithorax positioned upwards. The US probe was placed at the

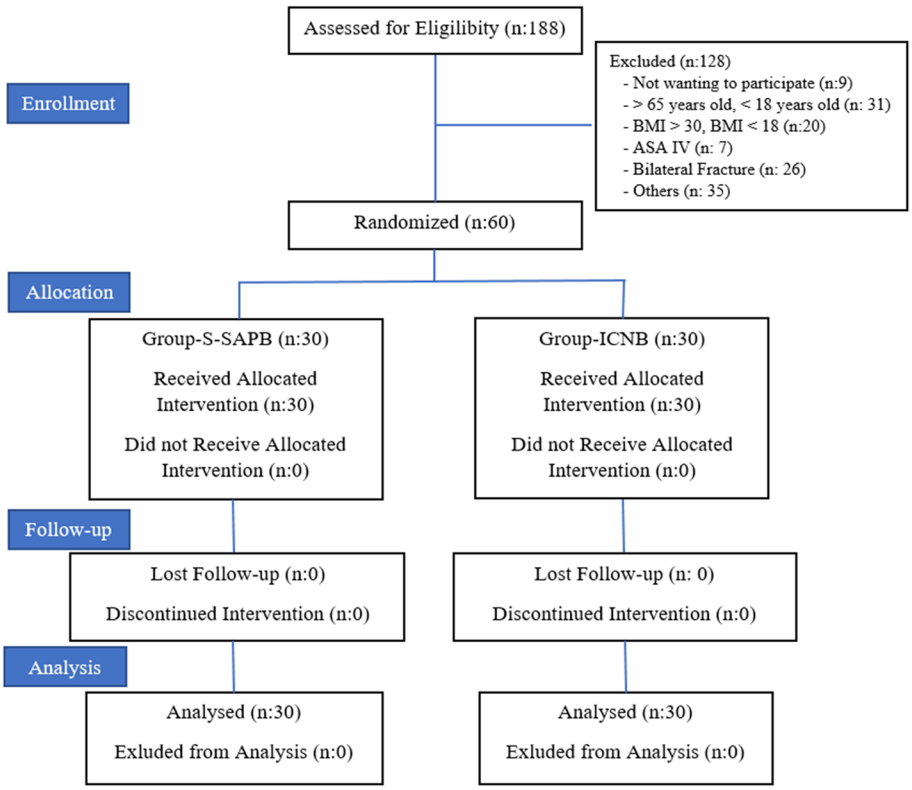

Fig. 1 CONSORT flow diagram of the study population. ASA: American Society of Anesthesiologists; BMI: body mass index; ICNB: intercostal nerve block; S-SAPB: superficial serratus anterior plane block

intersection of the 5th rib and the mid-axillary line. Using the US, the latissimus dorsi, teres major, and serratus anterior muscles were visualized above the fifth rib. The thoracodorsal artery served as an additional reference to define the superficial plane of the serratus anterior muscle. The block needle was advanced in-plane, beneath the latissimus dorsi muscle and above the serratus anterior muscle. After confirming accurate needle placement with hydrodissection (2 mL of normal saline), 20 mL of 0.25% bupivacaine was administered (Fig. 2).

Intercostal Nerve Block (ICNB)

ICNB was performed according to the technique described in the International Pain Society's joint committee recommendations [27]. Three mL of 0.25% bupivacaine were administered to each fractured rib. The patients were placed in the lateral decubitus position with the traumatized hemithorax facing upward. The linear US probe was placed longitudinally (parallel to the long axis of the rib) to visualize the rib, internal intercostal muscles, and pleura. A 22-gauge, 8-cm needle was advanced using an in-plane technique, targeting the lower edge of the rib. Then, 3 mL of 0.25% bupivacaine was administered (Fig. 3).

Patient data recorded included age, gender, BMI, diagnosis, ASA physical status, side of the thorax affected by trauma, fractured ribs, VAS scores during follow-up periods, hemodynamic data during follow-up periods [hearth rate (HR), mean blood pressure (MBP), oxygen saturation (SpO_2)], total tramadol consumption, post-procedure side effects (e.g., nausea/vomiting, itching, allergic reactions, hypotension, neurological complications, respiratory depression, infection), additional analgesic needs, and patient satisfaction.

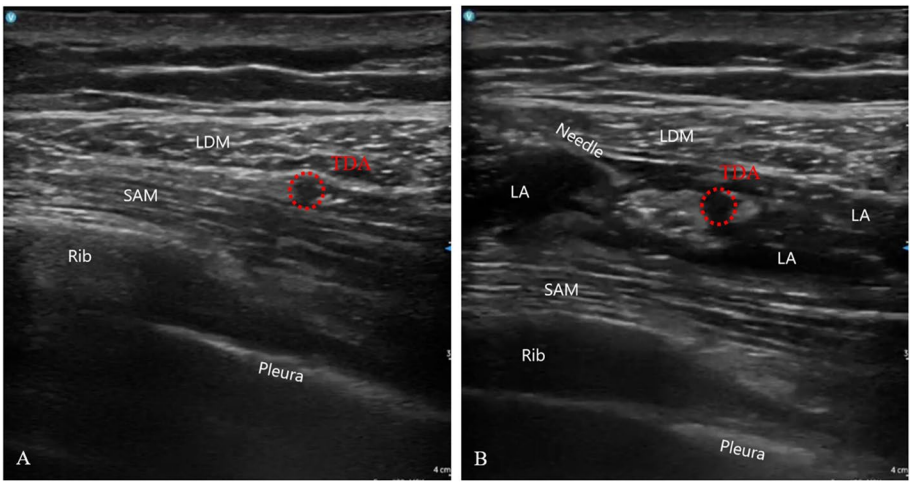

Fig. 2 Superficial serratus anterior plane block. **A** Anatomical scene before the block. **B** The local anesthetic spread above the SAM and below the LDM. LA: Local anesthetic, LDM: Latissimus dorsi muscle, SAM: Serratus anterior muscle. TDA: Thoracodorsal artery

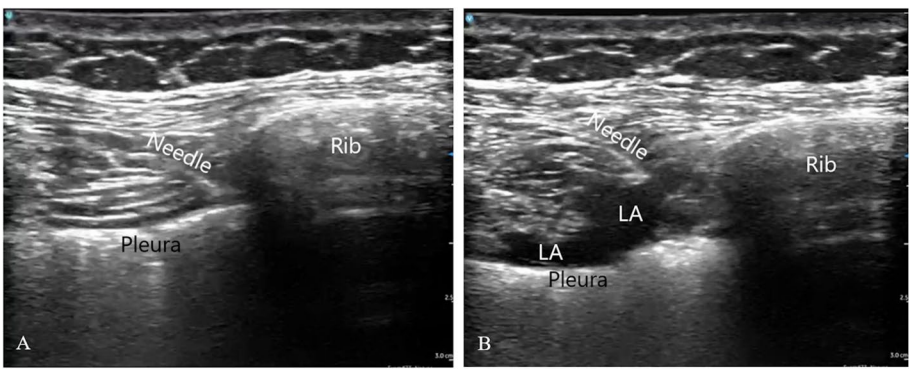

Fig. 3 Intercostal nerve block. **A** Anatomical scene before the block. **B** The local anesthetic spread above the pleura and below the internal intercostal muscles. LA: Local anesthetic

Evaluation of pain

The VAS (0 = no pain, 100 mm = unbearable pain) was used to monitor baseline pain before the procedure (pre-block) and assess pain after the procedure. VAS values were recorded at the following time points: 1st-hour (T1), 2nd-hour (T2), 4th-hour (T4), 8th-hour (T8), 16-hour (T16), and 24th-hour (T24) after the initial time point (T0). T0 represented the patient's baseline pain value at hospitalization, before initiating the analgesia protocol. VAS scores were documented both at rest and coughing at these seven-time points.

The changes in the observed values over time were expressed as Delta (Δ). The change at the 1st hour (T1) relative to the baseline (T0) was expressed as ΔT0-1, the 2nd-hour change as ΔT0-2, the 4th-hour change as ΔT0-4, the 8th-hour change as ΔT0-8, the 16th-hour change as ΔT0-16, and the 24th-hour change as ΔT0-24.

Evaluation of satisfaction

Patient satisfaction after the procedure was assessed using a 5-point Likert scale. Twenty-four hours after initiating the analgesia protocol, patients were asked to select one of five options to represent their satisfaction over the past 24 h. The options were recorded as follows: *1 point:* very dissatisfied; *2 points:* dis-satisfied; *3 points:* neither dissatisfied nor satisfied; *4 points:* satisfied; *5 points:* very satisfied.

Outcomes

The primary outcome measure was the change in VAS scores, assessed at rest and coughing, 24 h after block application, compared to the baseline VAS score recorded at the time of hospitalization. The secondary outcomes were the total amount of tramadol administered as additional analgesia within the 24-h follow-up period; the patient's score on the 5-point Likert satisfaction scale at the 24th hour; the change in VAS scores for patients with fractures of the 10th, 11th, and 12th ribs between the two groups during the follow-up periods, compared to the baseline (pre-block) VAS pain score.

Sample size

Due to the lack of comparable clinical studies in the literature, we conducted a pilot study. A total of 12 patients (6 patients per group) were included for the two groups, and the change in the 24-h average VAS score was calculated. The average change in VAS score was 31.50 ± 14.37 mm for the S-SAPB group and 18.33 ± 13.06 mm for the ICNB group, based on the average baseline VAS value.

Based on these values, the sample size was calculated with G*Power© software version 3.1.9.6 (Institute for Experimental Psychology, Heinrich Heine University, Düsseldorf, Germany). The calculation was performed for the Mann–Whitney U test, which was employed to assess the primary outcome of the study (24-h VAS resting change from baseline between ICNB and S-SAPB). With a two-sided (two-tailed) type I error rate of 0.05, a power of 90% (1-β = 0.9), and an effect size (d) factor of 0.95, the required sample size was determined to be at least 26 participants per group. Consequently, our study was designed to include 60 patients (30 patients per group).

Randomization

At the time of admission, each eligible patient was assigned a unique random identification number, which was used for all recorded data. The randomization was performed using the Research Randomizer software program, which generated a computer-generated randomization table to allocate patients into either the S-SAPB group or the ICNB group. To ensure allocation concealment, the assignment sequence was placed in sealed, opaque, consecutively numbered envelopes. Inside each envelope, a paper marked with either "S" for S-SAPB or "I" for ICNB was enclosed. The envelopes were prepared by an independent investigator who was not involved in patient enrollment, intervention, or data collection.

Randomization occurred after patient enrollment and confirmation of eligibility. To maintain blinding, the anesthesiologist performing the blocks was aware of the assigned intervention but had no role in pain assessment or data collection. Patients were provided with only general information regarding the procedure to minimize bias while maintaining ethical transparency. Both interventions were conducted under identical aseptic conditions and with uniform pre-procedural preparation to prevent patients from distinguishing between the two techniques.

Post-procedure pain assessments, additional analgesic administration, and patient satisfaction evaluations were conducted by an independent pain management nurse and a blinded investigator who were unaware of group assignments, ensuring objective outcome measurements.

Statistical analysis

Data analysis was conducted using SPSS for Windows, version 22.0 (SPSS Inc., Chicago, IL, United States). The Shapiro–Wilk test was used to assess the normality of the distribution for continuous variables. The Levene test was employed to evaluate the homogeneity of variances. Continuous data were presented as mean ± standard deviation (SD) for normally distributed variables, and median (interquartile range, IQR) for non-normally distributed variables. Categorical data were expressed as frequencies and percentages. Statistical comparisons for normally distributed variables between two independent

groups were performed using the Student's t-test, while the Mann–Whitney U test was used for non-normally distributed data. Categorical variables were compared using Pearson's chi-square test or Fisher's exact test, with a p-value < 0.05 considered statistically significant for all analyses.

One-way consecutive measurements were corrected according to the ANOVA result and epsilon (ε) values were calculated according to Greenhouse–Geisser. Significance values for multiple comparisons were adjusted using the Bonferroni correction. Graphical representations were created using Jamovi version 2.3.21.0 software (Sydney, Australia).

Results

A total of 188 patients were evaluated for the study between December 2021 and December 2022. 128 of these patients were excluded due to exclusion criteria. Sixty patients were randomized. Data from 30 patients who underwent S-SAPB and 30 patients who underwent ICNB were analyzed (Fig. 1). The demographic characteristics and details of the fractured ribs in each group are presented in Table 1. There was no statistically significant difference between the two groups in terms of these parameters. The rib fractures of the patients are also detailed in Fig. 4.

The changes in MBP values at different time points (T1-8) relative to the pre-block time (T0) in both groups, no statistically significant differences were found between the groups (ΔT0-1, $p=0.783$; ΔT0-2, $p=0.604$; ΔT0-4, $p=0.394$; ΔT0-8, $p=0.054$). However, there were statistically significant differences between the groups in terms of MBP changes at ΔT0-16 ($p=0.029$) and ΔT0-24 ($p=0.034$). In the ICNB group, there was an average decrease in MBP of 7.53 ± 6.67 mmHg between T0 and T16, while in the S-SAPB group, the decrease was 11.36 ± 6.58 mmHg. Between T0 and T24, the ICNB group showed an average MBP decrease of 6.33 ± 7.20 mmHg, compared to a decrease of 10.26 ± 6.81 mmHg in the S-SAPB group. The standard error graph of MBP values at different time points between the groups is shown in Fig. 5.

When the HR changes at different time points (T1-24) relative to the pre-block time (T0) were examined, no statistically significant differences were found between the groups in the ΔT0-1 ($p=0.628$), ΔT0-2 ($p=0.975$), and ΔT0-4 ($p=0.239$) change values. However, statistically significant differences were observed between the groups in HR change values at ΔT0-8 ($p=0.008$), ΔT0-16 ($p=0.034$), and ΔT0-24 ($p=0.040$). In the ICNB group, there was an average decrease in HR of 4.70 ± 5.52 beats/min between T0 and T8, while in the S-SAPB group, the decrease was 8.46 ± 5.13 beats/min. Between T0 and T16, the ICNB group showed an average HR decrease of 6.00 ± 4.13 beats/min, compared to a decrease of 8.50 ± 4.74 beats/min in the S-SAPB group. Similarly, between T0 and T24, the ICNB group had an average HR decrease of 5.46 ± 4.15 beats/min, while the S-SAPB group had a decrease of 8.00 ± 5.12 beats/min. The standard error graph of HR values at different time points between the groups is shown in Fig. 5.

When examining the changes in SpO_2 at different time points (T1-24) relative to the pre-block time (T0), no statistically significant differences were found between the groups for ΔT0-1 ($p=0.118$), ΔT0-2 ($p=0.988$), ΔT0-4 ($p=0.867$), ΔT0-8 ($p=0.145$), ΔT0-16 ($p=0.824$), and ΔT0-24 ($p=0.168$). The standard error graph of oxygen saturation values at different time points between the groups is shown in Fig. 5. When evaluating SpO_2 changes within each group, the block application significantly altered SpO_2 over time in the ICNB group ($p<0.001$, Greenhouse–Geisser, $\varepsilon=0.622$). In the ICNB group, SpO_2 increased by 1.7 units at T1, 1.7 units at T2, 1.6 units at T4, 1.36 units at T8, 1.80 units at T16, and 1.36 units at T24, compared to T0. Similarly, in the S-SAPB group, the block application significantly altered oxygen saturation over time ($p<0.001$, Greenhouse–Geisser, $\varepsilon=0.700$). In the S-SAPB group, oxygen saturation increased by 1.13 units at T1, 1.7 units at T2, 1.66 units at T4, 1.83 units at T8, 1.73 units at T16, and 1.83 units at T24, compared to T0.

The resting VAS scores at different time points are shown in Table 2. When examining the changes in resting VAS scores at different time points relative to T0, no statistically significant differences were found between the groups for ΔT0-1 ($p=0.947$), ΔT0-2 ($p=0.689$), and ΔT0-4 ($p=0.325$). At 8 h, the ICNB group showed a median decrease of 16 mm in resting VAS scores compared to the baseline, while the S-SAPB group showed a median decrease of 34.5 mm (ΔT0-8, $p<0.001$). At 16 h, the ICNB group had a median decrease of 16.5 mm compared to baseline, and the S-SAPB group had a median decrease of 33 mm (ΔT0-16, $p<0.001$). At 24 h, the ICNB group had a median decrease of 17.5 mm, while the S-SAPB group had a median decrease of 27 mm (ΔT0-24, $p<0.001$). After 8 h, the decrease in VAS scores in the S-SAPB group was significantly greater compared to the ICNB group when compared to baseline values.

The VAS cough scores at different time points relative to T0, no statistically significant differences were found between the groups for ΔT0-1 ($p=0.367$), ΔT0-2 ($p=0.836$), and ΔT0-4 ($p=0.569$). At 8 h, the ICNB group showed a median decrease of 19 mm in VAS cough scores compared to baseline, while the S-SAPB group showed a median decrease of 39.5 mm (ΔT0-8, $p<0.001$). At 16 h, the ICNB group had a median decrease of

Table 1 Comparison of demographic data and rib fractures between groups

Parameters		ICNB ($n=30$)		S-SAPB ($n=30$)		*P*
Age, year, median (IQR)		44 (27.75)		53 (18.0)		0.222*
Gender, n (%)	Female	10	(33.3%)	9	(30.0%)	0.781†
	Male	20	(66.7%)	21	(70.0%)	
BMI, kg/m^2, median (IQR)		26.85 (4.48)		26.15 (3.33)		0.935*
Side, n (%)	Left	10	(33.3%)	13	(43.3%)	0.426†
	Right	20	(66.7%)	17	(56.7%)	
ASA, n (%)	I	12	(40.0%)	11	(36.7%)	0.786†
	II	14	(46.7%)	13	(43.3%)	
	III	4	(13.3%)	6	(20.0%)	
Comorbidity, n (%)	Yes	13	(43.3%)	11	(36.7%)	0.598†
	No	17	(56.7%)	19	(63.3%)	
	Hypertension	5	(16.7%)	5	(16.7%)	
	DM	3	(10.0%)	3	(10.0%)	
	Asthma	3	(10.0%)	2	(6.7%)	
	Hypothyroidism	3	(10.0%)	2	(6.7%)	
	CAD	2	(6.7%)	2	(6.7%)	
	Hyperlipidemia	2	(6.7%)	2	(6.7%)	
	Arrhythmia	-	-	2	(6.7%)	
	Heart failure	-	-	2	(6.7%)	
	COPD	1	(3.3%)	1	(3.3%)	
	Peripheral artery disease	1	(3.3%)	-	-	
	Sjögren's syndrome	1	(3.3%)	-	-	
	Benign prostatic hypertrophy	1	(3.3%)	-	-	
Fractured rib, n (%)	Rib-2	3	(4.1%)	1	(1.3%)	0.934†
	Rib-3	6	(8.1%)	7	(9.2%)	
	Rib-4	9	(12.2%)	12	(15.8%)	
	Rib-5	13	(17.6%)	11	(14.5%)	
	Rib-6	8	(10.8%)	12	(15.8%)	
	Rib-7	10	(13.5%)	9	(11.8%)	
	Rib-8	6	(8.1%)	9	(11.8%)	
	Rib-9	9	(12.2%)	7	(9.2%)	
	Rib-10	7	(9.5%)	6	(7.9%)	
	Rib-11	3	(4.1%)	2	(2.6%)	

Continuous variables are expressed as either the mean ± standard deviation (SD) or median (IQR) and categorical variables are expressed as either frequency (percentage). Mann Whitney u Test* Chi Square Test†. p = Level of Significance, $p<0.05$

ASA American Society of Anesthesiologists, *BMI* Body mass index, *CAD* Coronary artery disease, *COPD* Chronic obstructive pulmonary diseases, *DM* Diabetes mellitus, *ICNB* Intercostal nerve block, *S-SAPB* superficial serratus anterior plane block

19.5 mm compared to baseline, and the S-SAPB group had a median decrease of 35.5 mm (ΔT0-16, $p<0.001$). At 24 h, the ICNB group showed a median decrease of 22 mm, while the S-SAPB group showed a median decrease of 31.5 mm (ΔT0-24, $p=0.007$). The decrease in VAS cough scores in the S-SAPB group was significantly greater compared to the ICNB group after 8 h when compared to baseline values. The VAS cough scores at different time points are shown in Table 2. Additionally, Fig. 6 displays the standard error graphs of VAS resting and VAS cough scores at various time points between the groups.

Regarding the use of additional analgesia between the groups, 13 patients (43.3%) in the ICNB group received additional analgesia during the 24-h follow-up period, whereas no patients in the S-SAPB group received additional analgesia ($p<0.001$). In the ICNB group, the first instance of additional analgesia was administered to 11 patients at the 8-h follow-up and 2 patients at the 16-h follow-up. A total of 19 instances of additional analgesia

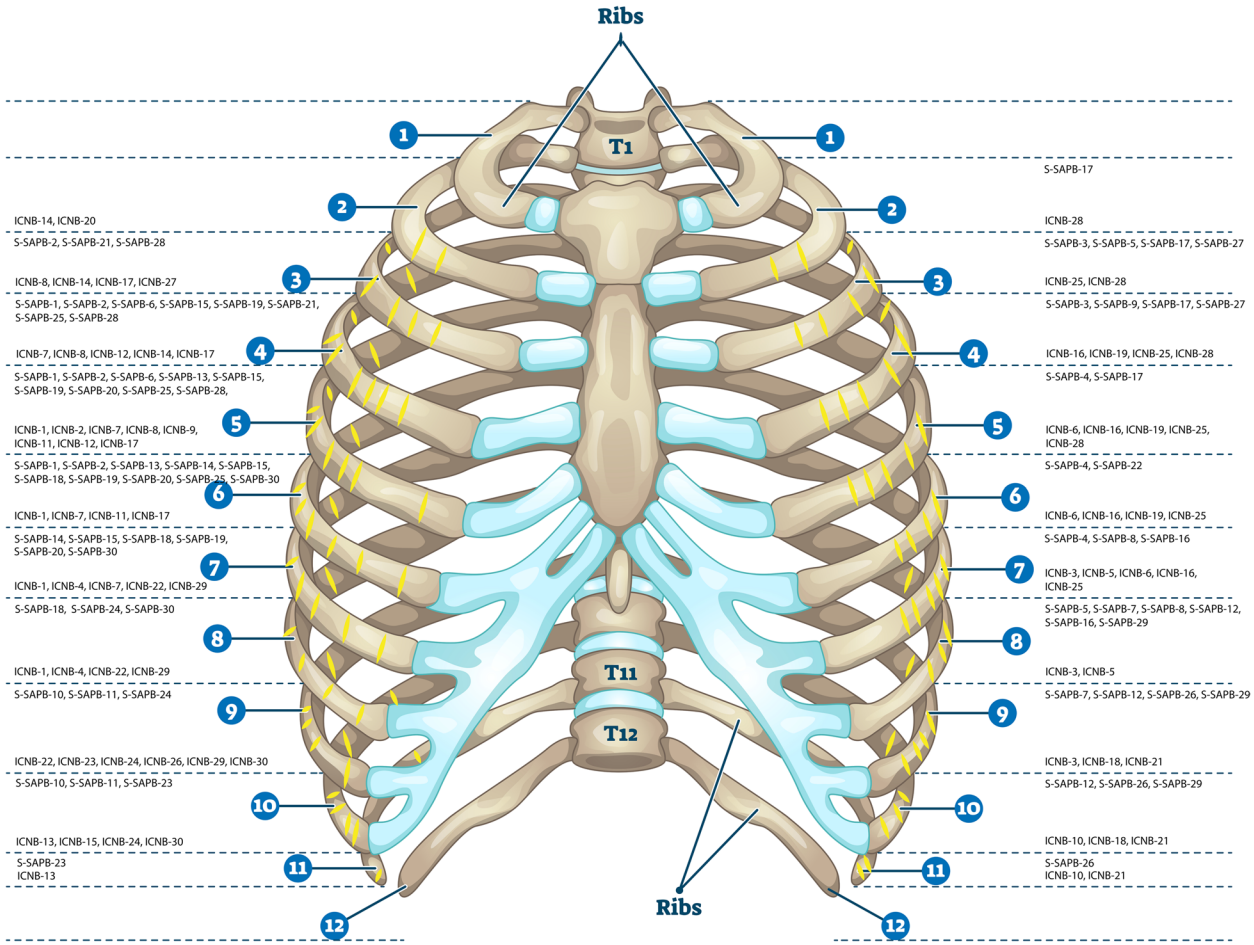

Fig. 4 A comprehensive visual representation of rib fractures, classified according to groups (ICNB: Intercostal Block, S-SAPB: Superficial Serratus Anterior Plane Block, Yellow lines: Representative image of rib fracture lines detected on chest radiography, Numbers: Identification numbers given to patients upon admission according to the randomization table, Numbers inside blue circles: rib numbers); In instances where the fracture lines observed in the patient-based radiographic image were in close proximity to one another, they were represented as a single line

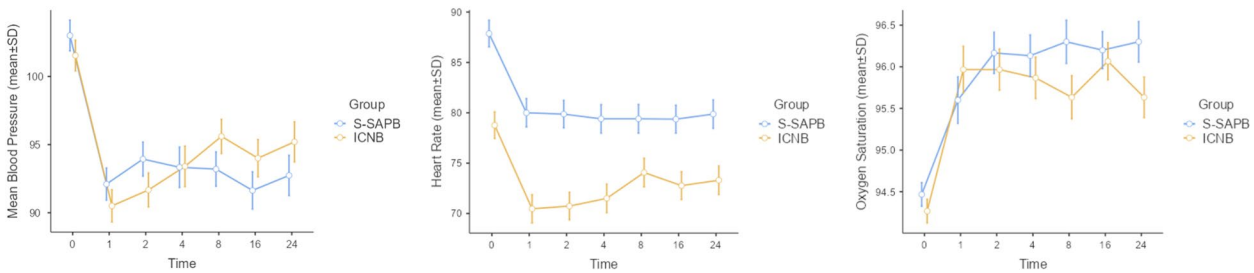

Fig. 5 Standard error graph of mean arterial pressure, heart rate, and oxygen saturation values at time points between groups. ICNB: intercostal nerve block; S-SAPB: superficial serratus anterior plane block

were administered in the ICNB group over the 24-h follow-up period.

Pain score follow-ups for patients with fractures of the 10th, 11th, and 12th ribs are shown separately in Table 3. No patients had fractures of the 12th rib. In the ICNB group, 7 patients had fractures of the 10th and 11th ribs, while in the S-SAPB group, 6 patients had fractures of the 10th and 11th ribs. When examining the changes in VAS resting scores at different time points relative to T0, although no statistically significant differences were

Table 2 Comparison of VAS values and additional analgesic needs of the groups

Parameters	ICNB ($n=30$)	S-SAPB ($n=30$)	*P*
VAS rest, mm (median, IQR)			
T0	49.5 (14.75)	48.0 (15.5)	0.529*
T1	20.5 (11.75)	21.5 (8.75)	0.491*
T2	16.5 (8.75)	16.0 (14.25)	0.894*
T4	15.0 (9.0)	13.5 (12.25)	0.830*
T8	27.0 (23.5)	15.0 (10.0)	**<.001***
T16	31.0 (14.0)	19.5 (5.5)	**<.001***
T24	30.0 (7.75)	20.0 (7.5)	**<.001***
Delta VAS rest, mm (median, IQR)			
ΔT0-1	28.0 (8.5)	28.0 (8.75)	0.947*
ΔT0-2	31.0 (9.5)	33.5 (9.75)	0.689*
ΔT0-4	31.5 (9.75)	33.5 (9.5)	0.325*
ΔT0-8	16.0 (20.25)	34.5 (10.75)	**<.001***
ΔT0-16	16.5 (9.5)	33.0 (12.75)	**<.001***
ΔT0-24	17.5 (14.0)	27.0 (15.25)	**<.001***
VAS cough, mm (median, IQR)			
T0	69.5 (16.5)	67.0 (17.25)	0.641*
T1	39.5 (15.25)	40.0 (9.75)	0.636*
T2	33.0 (11.0)	37.0 (14.75)	1.000*
T4	31.5 (10.5)	32.0 (10.0)	0.599*
T8	43.5 (24.0)	30.0 (12.75)	**<.001***
T16	49.0 (7.75)	33.0 (8.5)	**<.001***
T24	48.0 (7.75)	38.0 (8.0)	**<.001***
Delta VAS cough, mm (median, IQR)			
ΔT0-1	28.0 (14.25)	28.0 (10.75)	0.367*
ΔT0-2	32.5 (14.0)	33.5 (12.5)	0.836*
ΔT0-4	34.5 (13.25)	37.0 (11.75)	0.569*
ΔT0-8	19.0 (21.25)	39.5 (13.75)	**<.001***
ΔT0-16	19.5 (11.5)	35.5 (14.25)	**<.001***
ΔT0-24	22.0 (15.5)	31.5 (18.0)	**0.007***
Additional analgesic, n (%)			
Yes	17 (56.7%)	30 (100%)	**<.001**†
No	13 (43.3%)	0	

Continuous variables are expressed as either * the median (IQR) and categorical variables are expressed as either † frequency (n) or percentage (%)

Continuous variables were compared with a Mann–Whitney U and categorical variables were compared using Pearson's Chi-Square test

Statistically significant *p*-values are in bold. $p=$ Level of Significance, $p<0.05$

ICNB Intercostal nerve block, *S-SAPB* Superficial serratus anterior plane block, *VAS* Visual Analog Scale, Δ Delta

found for ΔT0-1, ΔT0-2, and ΔT0-4, a greater decrease in VAS scores was observed in the ICNB group. This decrease was not as pronounced as the change in VAS cough scores. After T8, the reduction in VAS scores (both resting and cough) was more pronounced in the S-SAPB group. The Delta VAS standard error change graphs for patients with 10th and/or 11th rib fractures are shown in Fig. 7.

Finally, no side effects due to the block applied in analgesia management were recorded in the patients.

Discussion

This study, which evaluated the outcomes of multimodal analgesia using S-SAPB and ICNB in patients with isolated rib fractures, demonstrates that similar analgesic efficacy was achieved in both groups during the first 8 h. However, it was observed that the analgesia provided by S-SAPB was more effective after the 8-h mark. Another notable finding of the study was that ICNB provided more effective analgesia in the first 4 h, particularly for fractures at the 10th and 11th ribs, with similar analgesic effects observed in both groups during subsequent follow-ups. Following the determination of the analgesia procedure in addition to the block applications, effective analgesia management was provided in both groups during the follow-up period.

In addition to complications such as pneumothorax, lung contusion, and hemothorax that can develop from blunt chest trauma, severe pain is one of the most significant concerns [2]. This pain not only causes serious anxiety and stress in patients but also leads to secretion retention due to inadequate breathing. Consequently, the risk of pulmonary complications increases significantly [6, 7].

While systemic parenteral and oral analgesics are commonly used in traditional approaches, regional techniques have become an important component of treatment due to the high incidence of side effects associated with systemic analgesics [8, 28]. Although techniques such as TPVB and TEA are effective, they may not always be suitable due to the challenges of application and the difficulty of positioning trauma patients [16–18]. In recent years, thoracic wall blocks have gained popularity because they provide effective analgesia and are relatively easy to learn to perform [29]. However, aspects such as their effectiveness, optimal volume, and LA dosage in these applications remain uncertain [30]. ICNB is indicated for the management of various chronic and acute pain conditions, such as rib fractures, post-thoracotomy pain syndrome, herpes zoster, and intercostal neuralgia [1]. ICNB is performed by administering a LA solution of 3 to 5 ml into the intercostal sulcus. This technique offers a reliable and consistent unilateral dermatomal analgesia at the vertebral level where it is applied [1]. The advantages of this method are relatively straightforward to implement, and there are no neurological complications associated with the procedure, such as nausea, vomiting, dizziness, or bleeding. The majority of complications associated with ICNB can be attributed to the close anatomical proximity of the nerve to the lung and intercostal vessels. The disadvantages of ICNB include

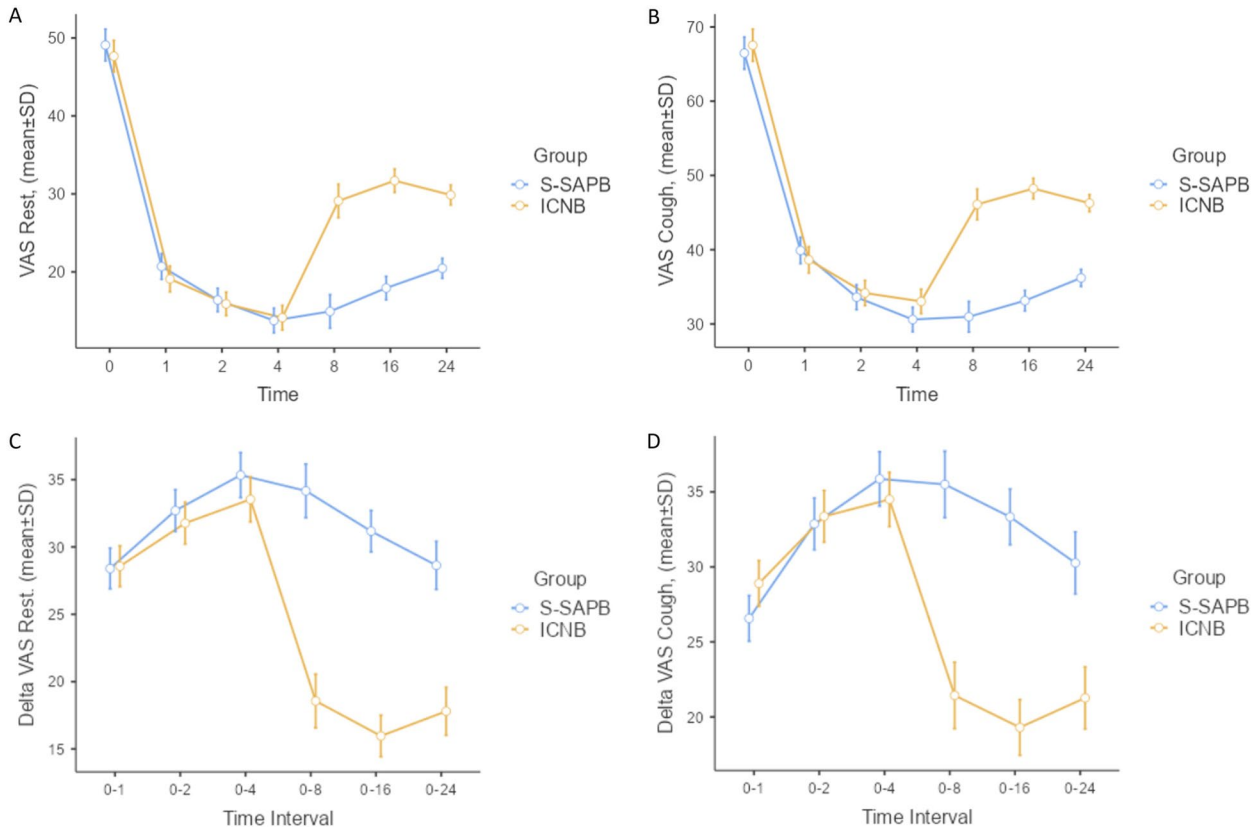

Fig. 6 VAS rest, VAS cough, Delta VAS rest and Delta VAS cough standard error graph between groups at different time points. ICNB: intercostal nerve block; S-SAPB: superficial serratus anterior plane block; VAS: Visual Analog Scale

the need for repeated administration every six hours due to its short duration of effect (up to six hours) and the potential for complications such as pneumothorax or hemothorax [31, 32]. Caution must be exercised regarding LAST, as the absorption rate from the injection site is high. Therefore, it is critical to keep the total administered dose is maintained below the maximum permitted level. Additionally, there is a potential risk of spinal blockade [33]. It is important to note that ICNB does not provide complete surgical anesthesia for thoracic surgery. Therefore, it is recommended that ICNB be included as part of a multimodal analgesia plan for use in intraoperative analgesia [34]. ICNBs, which have been used for many years, are favored for their ease of application and rapid onset, especially in the early stages. Nonetheless, the need for multiple injections at each level and their short duration of action may reduce patient comfort and exacerbate the stress response, particularly in trauma patients [19]. Additionally, the risk of developing LAST due to rapid absorption is a significant concern, which may also limit the duration of the analgesic effect [35].

SAPB is performed by applying LA under (deep) or above (superficial) the serratus anterior muscle. The evidence suggests that superficial application provides more effective and longer-lasting analgesia [21]. It is hypothesized that the S-SAPB functions by blocking the lateral cutaneous branches of the intercostal nerves, rather than directly targeting the intercostal nerves themselves [20]. In contrast to peripheral nerve blocks, fascial plane blocks depend on the diffusion of LAs along the fascial planes and through the muscle layers [20]. Consequently, despite the mechanism of action remaining unclear, it is established that the procedure affects the intercostal nerves, the thoracicus longus nerve and the thoracodorsal nerve [20]. Although cadaveric studies have indicated that dye uptake is limited to the lateral area [36], the precise dermatomal level at which the analgesic effect occurs remains a topic of contention. Following the S-SAPB, a sensory block was observed in the anterolateral and posterior aspects of the chest wall within the T2-T9 dermatome [21]. A review of the literature reveals that the most frequently administered LAs for clinical SAPB are ropivacaine and bupivacaine [22]. A LA volume of 20–40 ml is frequently employed in clinical practice [22]. The mean duration of paresthesia was reported to be

Table 3 Comparison of VAS values between the groups in patients with 10th and/or 11th rib fracture(s)

Parameters	ICNB ($n=7$)	S-SAPB ($n=6$)	*P*
VAS rest, mm (median, IQR)			
T0	41.0 (15.50)	47.5 (11.25)	0.316*
T1	14.0 (12.0)	23.5 (8.0)	0.062*
T2	10.0 (10.5)	21.0 (10.75)	0.113*
T4	10.0 (16.5)	23.5 (7.0)	0.052*
T8	31.0 (22.0)	20.5 (7.75)	0.391*
T16	24.0 (13.0)	21.0 (8.0)	0.115*
T24	28.0 (4.5)	27.0 (8.5)	0.473*
Delta VAS rest, mm (median, IQR)			
ΔT0-1	31.0 (6.0)	28.5 (14.75)	0.390*
ΔT0-2	31.0 (3.5)	30.0 (17.5)	0.774*
ΔT0-4	30.0 (9.0)	27.5 (12.75)	0.223*
ΔT0-8	10.0 (1.5)	28.0 (17.5)	0.082*
ΔT0-16	17.0 (3.5)	27.5 (17.0)	0.171*
ΔT0-24	15.0 (11.5)	23.5 (11.75)	0.252*
VAS cough, mm (median, IQR)			
T0	55.0 (21.0)	67.5 (16.25)	0.100*
T1	31.0 (5.0)	41.5 (9.25)	0.063*
T2	29.0 (10.0)	36.5 (6.75)	0.114*
T4	28.0 (8.0)	39.5 (6.25)	**0.032***
T8	46.0 (20.0)	38.5 (11.25)	0.193*
T16	45.0 (9.5)	39.0 (5.0)	0.150*
T24	42.0 (7.0)	42.0 (4.75)	0.616*
Delta VAS cough, mm (median, IQR)			
ΔT0-1	24.0 (12.0)	27.0 (17.75)	0.829*
ΔT0-2	28.0 (7.0)	34.0 (16.75)	0.616*
ΔT0-4	27.0 (10.0)	31.5 (13.25)	0.829*
ΔT0-8	10.0 (3.5)	31.0 (23.75)	**0.026***
ΔT0-16	15.0 (9.0)	30.5 (20.0)	0.053*
ΔT0-24	16.0 (17.5)	27.0 (18.25)	0.086*

Continuous variables are expressed as either the median (IQR)

Continuous variables were compared with a Mann–Whitney U test *. p = Level of Significance, $p<0.05$

ICNB Intercostal nerve block, *S-SAPB* Superficial serratus anterior plane block, *VAS* Visual Analog Scale, Δ Delta

752 min for the intercostal nerves and 778 min for the motor nerves following the superficial injection of the serratus anterior [21]. Rose et al. demonstrated the efficacy of deep SAPB in patients with 3–10 anterolateral and posterior rib fractures, providing effective analgesia [37]. In a study conducted by Partyka et al. (2024), involving 210 patients with rib fractures, it was found that the application of S-SAPB resulted in more effective analgesia and a reduction in the consumption of opioids when compared to the control group [38]. In a randomized controlled trial conducted by Tekşen et al. [25] on patients with rib fractures, the S-SAPB group exhibited superior analgesic efficacy compared to the control group. In a case series of 10 patients with anterior-lateral-posterior rib fractures in the emergency department, Paul et al. observed a significant reduction in pain scores following S-SAPB application [26]. In our preceding studies, we have observed that the administration of deep and S-SAPB in the context of thoracic surgery provides effective postoperative analgesia in the hemithorax [23]. In addition to all these, SAPB, which has been increasingly used for analgesia in recent years, particularly in thoracic surgery, has been reported to provide a longer analgesic effect due to its fascial plane block mechanism [24]. Moreover, the distribution of LA within the fascial plane may reduce the incidence of LAST by leading to slower absorption of the LA [39]. Another advantage of S-SAPB is that it requires only a single injection point, thereby enhancing patient comfort [25]. The present study demonstrated that ICNB administration was associated with enhanced analgesia and a diminished prevalence of pain during movements such as coughing within the initial hour. However, the observed difference was not found to be statistically significant. The results indicate that the provision of more efficacious analgesia during the initial period may confer a benefit to patients undergoing ICNB. This method may be particularly preferable for patients experiencing severe pain requiring a quick onset of action. However, when considering long-term analgesia, S-SAPB appears to be more effective. Additionally, the observation of these effects in hemodynamic parameters suggests that S-SAPB may be a more appropriate method for long-term pain management.

Shallow breathing due to severe pain is a common issue in rib fractures, leading to increased hypoxia and pulmonary complications [2, 7]. The increase in SpO_2 values in both groups indicates that more effective breathing was achieved as a result of the effective analgesia provided to these patients.

Ribs numbered 4 to 10 are generally the most vulnerable to fractures, while ribs 11 and 12 are more difficult to fracture due to their increased mobility. Our study observed trauma in ribs 10 and 11, although in small numbers. When considering the general distribution, the distribution of rib fractures observed is consistent with the literature. It's important to note that trauma may occur in ribs 10 and 11, albeit infrequently, and alternative analgesia should be considered [40]. The limited analgesic effect of S-SAPB observed in the 10th and 11th ribs in this study may be due to its reduced efficacy in these areas, as suggested by existing literature. This suggests that an alternative approach for analgesia, especially in the 10th and 11th ribs, may be to use ICNB at several levels together with S-SAPB at appropriate doses, taking

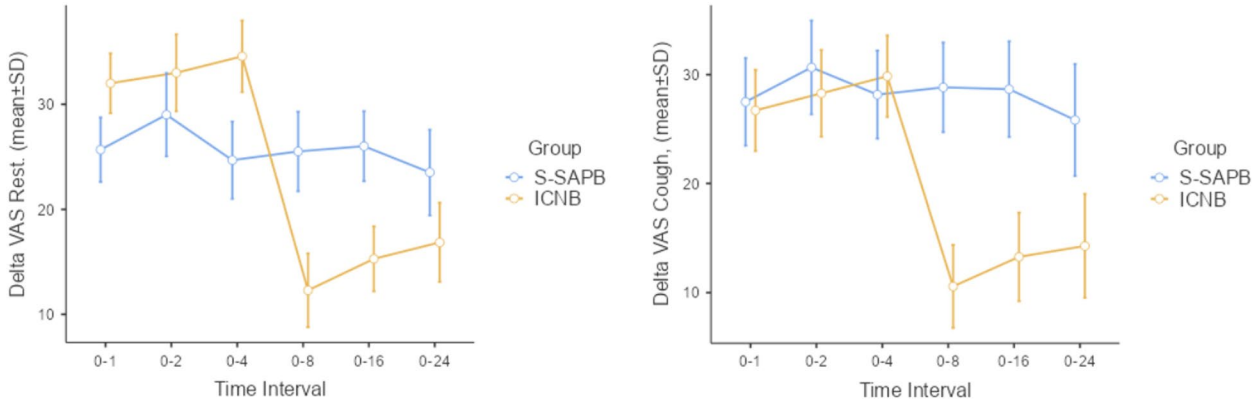

Fig. 7 Intergroup Delta VAS rest and Delta VAS cough standard error graph in patients with 10th and/or 11th rib fracture(s) ICNB: intercostal nerve block; S-SAPB: superficial serratus anterior plane block; VAS: Visual Analog Scale. Δ: Delta

into account the risk of LAST. This strategy may provide the benefit of S-SAPB's long-term analgesic effects while minimizing the need for multiple injections.

Limitations

Primarily, it was conducted at a single center and did not incorporate a control group. Additionally, chronic pain in patients was not assessed. Because the study was conducted in a tertiary thoracic surgery hospital, the generalizability of the findings to the larger population may be limited. Lastly, the primary outcome of our study was to compare the 24-h changes in resting VAS values between the two groups. The sample size was determined based on basal and 24-h VAS resting values. Since both blocks provide effective and safe postoperative analgesia, the small sample size introduces an additional margin of error when comparing the groups.

Conclusion

Effective pain management for rib fractures is essential to reduce complications and improve patient outcomes. This randomized controlled trial demonstrated that both S-SAPB and ICNB are effective analgesic techniques for rib fractures. However, their efficacy varies over time. S-SAPB provided prolonged analgesia, reducing pain scores significantly after the 8-h mark, and eliminated the need for additional analgesia. In contrast, ICNB resulted in superior pain relief in the early post-procedure hours (first 4 h), particularly for fractures of the 10th and 11th ribs. These findings suggest that S-SAPB may be preferable for long-term pain control, while ICNB may be beneficial for rapid pain relief in the early phase, especially for lower rib fractures.

Considering the limitations of each technique, S-SAPB may be preferred for long-term analgesia and ICNB for rapid pain relief. Additionally, a combined approach that includes both blocks may optimize pain control in patients with multiple rib fractures involving the 10th and 11th ribs. Further large-scale, multicenter studies are needed to explore the most effective analgesic strategies, determine the ideal combination of techniques, and evaluate their long-term outcomes in different patient populations.

Abbreviations

ASA	American Society of Anesthesiologists
BMI	Body mass index
IV	Intravenous
NSAIDs	Nonsteroidal anti-inflammatory drugs
TEA	Thoracic epidural analgesia
HR	Hearth rate
ICNB	Intercostal nerve block
LA	Local anesthetic
LAST	Local anesthetic systemic toxicity
MAP	Mean arterial pressure
Q	Quartiles
SAPB	Serratus anterior plane block
SD	Standard deviation
SpO_2	Oxygen saturation
TPVB	Thoracic paravertebral block
US	Ultrasound
VAS	Visual analog scale

Acknowledgements

None.

Authors' contributions

MZ: Conceptualization, Funding acquisition, Investigation, Methodology, Project administration, Resources, Software, Supervision, Validation, Writing – original draft, Writing – review & editing. OK: Formal analysis, Investigation, Methodology, Project administration, Resources, Software, Supervision, Validation, Visualization, Writing – original draft, Writing – review & editing. MA: Data curation, Investigation, Methodology, Resources, Software, Supervision, Validation, Writing – original draft, Writing – review & editing. GF: Funding acquisition, Investigation, Methodology, Project administration, Supervision, Validation, Writing – original draft, Writing – review & editing. AA: Conceptualization, Formal analysis, Investigation, Methodology, Project administration, Resources, Software, Supervision, Validation, Visualization, Writing – original draft, Writing – review & editing. All authors have read, reviewed, and approved the manuscript.

Funding
No funding received.

Data availability
The datasets used and/or analysed during the current study available from the corresponding author on reasonable request.

Declarations

Ethics approval and consent to participate
Compliance with ethical standards: All procedures performed in studies involving human participants were in accordance with the ethical standards of the institutional and/or national research committee and with the 1964 Helsinki declaration (as revised in 2013) and its later amendments or comparable ethical standards. Informed consent was obtained from all participants and was written in this study.
Ethical approval: The study was conducted with a prospective and randomized design after obtaining approval from the Ankara Bilkent City Hospital Ethical Committee (E.Kurul-E1-21–2143, 01/12/2021) and written informed consent was obtained from all subjects participating in the trial. The trial was registered on www.clinicaltrials.gov (https://clinicaltrials.gov/) under the identifier NCT05160155 on 15/12/2021. (principal investigator: Musa Zengin, MD).
Informed consent: Patients were informed about the study, and their written consent was obtained.

Consent for publication
Not applicable.

Competing interests
The authors declare no competing interests.

Author details
[1]Department of Anesthesiology and Reanimation, University of Health Sciences, Ankara Etlik City Hospital, Ankara, Turkey. [2]Department of Anesthesiology and Reanimation, University of Health Sciences, Ankara Atatürk Sanatorium Training and Research Hospital, Ankara, Turkey. [3]Department of Thoracic Surgery, Diyarbakır Gazi Yaşargil Training and Research Hospital, Diyarbakır, Turkey. [4]Department of Thoracic Surgery, University of Health Sciences, Ankara Atatürk Sanatorium Training and Research Hospital, Ankara, Turkey.

Received: 12 December 2024 Accepted: 6 March 2025
Published online: 13 March 2025

References

1. Hwang EG, Lee Y. Effectiveness of intercostal nerve block for management of pain in rib fracture patients. J Exerc Rehabil. 2014;10(4):241–4.
2. Ho AM, Karmakar MK, Critchley LA. Acute pain management of patients with multiple fractured ribs: a focus on regional techniques. Curr Opin Crit Care. 2011;17(4):323–7.
3. Shuaib W, Vijayasarathi A, Tiwana MH, Johnson JO, Maddu KK, Khosa F. The diagnostic utility of rib series in assessing rib fractures. Emerg Radiol. 2014;21(2):159–64.
4. Segers P, Van Schil P, Jorens P, Van Den Brande F. Thoracic trauma: an analysis of 187 patients. Acta Chir Belg. 2001;101(6):277–82.
5. Ziegler DW, Agarwal NN. The morbidity and mortality of rib fractures. J Trauma. 1994;37(6):975–9.
6. Dogrul BN, Kiliccalan I, Asci ES, Peker SC. Blunt trauma related chest wall and pulmonary injuries: An overview. Chin J Traumatol. 2020;23(3):125–38.
7. Chrysou K, Halat G, Hoksch B, Schmid RA, Kocher GJ. Lessons from a large trauma center: impact of blunt chest trauma in polytrauma patients-still a relevant problem? Scand J Trauma Resusc Emerg Med. 2017;25(1):42.
8. Koushik SS, Bui A, Slinchenkova K, Badwal A, Lee C, Noss BO, et al. Analgesic Techniques for Rib Fractures-A Comprehensive Review Article. Curr Pain Headache Rep. 2023;27(11):747–55.
9. Ballantyne JC, Carr DB, deFerranti S, Suarez T, Lau J, Chalmers TC, et al. The comparative effects of postoperative analgesic therapies on pulmonary outcome: cumulative meta-analyses of randomized, controlled trials. Anesth Analg. 1998;86(3):598–612.
10. El-Boghdadly K, Wiles MD. Regional anaesthesia for rib fractures: too many choices, too little evidence. Anaesthesia. 2019;74(5):564–8.
11. Womack J, Pearson JD, Walker IA, Stephens NM, Goodman BA. Safety, complications and clinical outcome after ultrasound-guided paravertebral catheter insertion for rib fracture analgesia: a single-centre retrospective observational study. Anaesthesia. 2019;74(5):594–601.
12. Adhikary SD, Liu WM, Fuller E, Cruz-Eng H, Chin KJ. The effect of erector spinae plane block on respiratory and analgesic outcomes in multiple rib fractures: a retrospective cohort study. Anaesthesia. 2019;74(5):585–93.
13. Yeying G, Liyong Y, Yuebo C, Yu Z, Guangao Y, Weihu M, et al. Thoracic paravertebral block versus intravenous patient-controlled analgesia for pain treatment in patients with multiple rib fractures. J Int Med Res. 2017;45(6):2085–91.
14. Yayik AM, Aydin ME, Tekin E, Ulas AB, Ahiskalioglu A. An alternative plane block for multiple rib fractures: Rhomboid Intercostal and Sub-Serratus block (RISS). Am J Emerg Med. 2019;37(12):2263.e5-2263.e7.
15. Tulgar S, Ciftci B, Ahiskalioglu A, Bilal B, Sakul BU, Korkmaz AO, et al. Serratus Posterior Superior Intercostal Plane Block: A Technical Report on the Description of a Novel Periparavertebral Block for Thoracic Pain. Cureus. 2023;15(2):e34582.
16. Freise H, Van Aken HK. Risks and benefits of thoracic epidural anaesthesia. Br J Anaesth. 2011;107(6):859–68.
17. Pöpping DM, Zahn PK, Van Aken HK, Dasch B, Boche R, Pogatzki-Zahn EM. Effectiveness and safety of postoperative pain management: a survey of 18 925 consecutive patients between 1998 and 2006 (2nd revision): a database analysis of prospectively raised data. Br J Anaesth. 2008;101(6):832–40.
18. Lin HM, Chelly JE. Post-dural headache associated with thoracic paravertebral blocks. J Clin Anesth. 2006;18(5):376–8.
19. Baxter CS, Singh A, Ajib FA, Fitzgerald BM. Intercostal Nerve Block. 2023 Jul 31. In: StatPearls. Treasure Island (FL): StatPearls Publishing; 2024 Jan–. PMID: 29489198.
20. Mayes J, Davison E, Panahi P, Patten D, Eljelani F, Womack J, et al. An anatomical evaluation of the serratus anterior plane block. Anaesthesia. 2016;71(9):1064–9.
21. Blanco R, Parras T, McDonnell JG, Prats-Galino A. Serratus plane block: a novel ultrasound-guided thoracic wall nerve block. Anaesthesia. 2013;68(11):1107–13.
22. Xie C, Ran G, Chen D, Lu Y. A narrative review of ultrasound-guided serratus anterior plane block. Ann Palliat Med. 2021;10(1):700–6.
23. Zengin M, Sazak H, Baldemir R, Ulger G, Alagoz A. The Effect of Erector Spinae Plane Block and Combined Deep and Superficial Serratus Anterior Plane Block on Acute Pain After Video-Assisted Thoracoscopic Surgery: A Randomized Controlled Study. J Cardiothorac Vasc Anesth. 2022;36(8):2991–9.
24. Hanley C, Wall T, Bukowska I, Redmond K, Eaton D, Ní Mhuircheartaigh R, et al. Ultrasound-guided continuous deep serratus anterior plane block versus continuous thoracic paravertebral block for perioperative analgesia in videoscopic-assisted thoracic surgery. Eur J Pain. 2020;24(4):828–38.
25. Tekşen Ş, Öksüz G, Öksüz H, Sayan M, Arslan M, Urfalıoğlu A, et al. Analgesic efficacy of the serratus anterior plane block in rib fractures pain: A randomized controlled trial. Am J Emerg Med. 2021;41:16–20.
26. Paul S, Bhoi SK, Sinha TP, Kumar G. Ultrasound-Guided Serratus Anterior Plane Block for Rib Fracture-Associated Pain Management in Emergency Department. J Emerg Trauma Shock. 2020;13(3):208–12.
27. Narouze SN, Provenzano D, Peng P, Eichenberger U, Lee SC, Nicholls B, et al. The American Society of Regional Anesthesia and Pain Medicine, the European Society of Regional Anaesthesia and Pain Therapy, and the Asian Australasian Federation of Pain Societies Joint Committee recommendations for education and training in ultrasound-guided interventional pain procedures. Reg Anesth Pain Med. 2012;37(6):657–64.
28. Pincus E. Regional Anesthesia: An Overview. AORN J. 2019;110(3):263–72.
29. Sharma R, Louie A, Thai CP, Dizdarevic A. Chest Wall Nerve Blocks for Cardiothoracic, Breast Surgery, and Rib-Related Pain. Curr Pain Headache Rep. 2022;26(1):43–56.

30. Fusco P, Pascarella G, Stecco C, Blanco R, Forero M, Pawa A, et al. Factors to consider for fascial plane blocks' success in acute and chronic pain management. Minerva Anestesiol. 2024;90(1–2):87–97.
31. Pedersen VM, Schulze S, Høier-Madsen K, Halkier E. Air-flow meter assessment of the effect of intercostal nerve blockade on respiratory function in rib fractures. Acta Chir Scand. 1983;149(2):119–20.
32. Rauchwerger JJ, Candido KD, Deer TR, Frogel JK, Iadevaio R, Kirschen NB. Thoracic epidural steroid injection for rib fracture pain. Pain Pract. 2013;13(5):416–21.
33. Wurnig PN, Lackner H, Teiner C, Hollaus PH, Pospisil M, Fohsl-Grande B, et al. Is intercostal block for pain management in thoracic surgery more successful than epidural anaesthesia? Eur J Cardiothorac Surg. 2002;21(6):1115–9.
34. Gadsden J, Kwofie K, Shastri U. Continuous intercostal versus paravertebral blockade for multiple fractured ribs. J Trauma Acute Care Surg. 2012;73(1):293–4.
35. Elkhashab Y, Wang D. A review of techniques of intercostal nerve blocks. Curr Pain Headache Rep. 2021;25(10):67 Erratum in: Curr Pain Headache Rep. 2021; 25(10):74.
36. Biswas A, Castanov V, Li Z, Perlas A, Kruisselbrink R, Agur A, et al. Serratus Plane Block: A Cadaveric Study to Evaluate Optimal Injectate Spread. Reg Anesth Pain Med. 2018;43(8):854–8.
37. Rose P, Ramlogan R, Madden S, Lui A. Serratus anterior plane block home catheter for posterior rib fractures and flail chest. Can J Anaesth. 2019;66(8):997–8.
38. Partyka C, Asha S, Berry M, Ferguson I, Burns B, Tsacalos K, et al. Serratus Anterior Plane Blocks for Early Rib Fracture Pain Management: The SABRE Randomized Clinical Trial. JAMA Surg. 2024;159(7):810–7.
39. Hotta K. Fascial plane blocks: anatomical structures that affect the spread of local anesthetic. J Anesth. 2019;33(4):493–4.
40. Bulger EM, Arneson MA, Mock CN, Jurkovich GJ. Rib fractures in the elderly. J Trauma. 2000;48(6):1040–7.

Publisher's Note

Springer Nature remains neutral with regard to jurisdictional claims in published maps and institutional affiliations.