Archives of Orthopaedic and Trauma Surgery
https://doi.org/10.1007/s00402-024-05270-0

ARTHROSCOPY AND SPORTS MEDICINE

The potential of posterior cruciate ligament buckling phenomenon as a sign for partial anterior cruciate ligament tears

Mehmet Ali Tokgoz[1] · Ethem Burak Oklaz[1] · Oguzhan Ak[1] · Elif Banu Guler Oklaz[2] · Muhammet Baybars Ataoglu[1] · Ulunay Kanatli[1]

Received: 12 September 2023 / Accepted: 3 March 2024
© The Author(s) 2024

Abstract

Introduction Diagnosis of a partial tear of the anterior cruciate ligament (ACL) can be challenging with physical examination and imaging techniques. Although magnetic resonance imaging (MRI) has high sensitivity and specificity for diagnosing complete ACL tears, its effectiveness may be limited when it is used to diagnose for partial tears. The hypothesis of the present study is that the posterior cruciate ligament (PCL) buckling phenomenon, which is a secondary sign of complete ACL tears on MRI, may be a useful method for diagnosing partial ACL tears.

Materials and methods The data of 239 patients who underwent knee arthroscopy in a single institution between 2016 and 2022 were analyzed retrospectively. Patients were divided into three groups based on the condition of their ligaments: partial tears, complete tears and intact ligaments. To evaluate the buckling phenomenon on sagittal T2-weighted MRI, measurements of the posterior cruciate ligament angle (PCLA) and the posterior cruciate ligament-posterior cortex angle (PCL-PCA) were conducted in each group. Subsequently, the ability of these two measurement methods to distinguish partial tears from the other groups was assessed.

Results Both methods provided significantly different results in all three groups. Partial tears could be distinguished from intact ligaments with 86.8% sensitivity, 89.9% specificity when PCLA < 123.13° and 94.5% sensitivity, 93.2% specificity when PCL-PCA < 23.77°. Partial tears could be distinguished from complete tears with 79.5% sensitivity, 78.4% specificity when PCLA > 113.88° and with 86.1% sensitivity, 85.3% specificity when PCL-PCA > 16.39°.

Conclusion The main finding of the present study is that the PCLA and PCL-PCA methods are useful on MRI for diagnosing partial ACL tears. PCLA value between 113°-123° and PCL-PCA value between 16°-24° could indicate a partial ACL tear. With these methods, it is possible to distinguish partial tears from healthy knees and reduce missed diagnoses. In addition, the differentiation of partial and complete tears by these methods may prevent unnecessary surgical interventions.

Level of evidence Level III.

Keywords Partial anterior cruciate ligament tears · Posterior cruciate ligament buckling phenomenon · Magnetic resonance imaging · Knee arthroscopy

Introduction

Partial anterior cruciate ligament (ACL) injury constitutes 10–27% of isolated ACL injuries [1]. There are different views on the definition of this injury. Some authors define the injury based on damage to the anteromedial (AM) and posterolateral (PL) bundles of the ACL, identified by their tibial insertion sites, while others define it based on the percentage of ACL fibers that are torn [1–5]. Despite the controversy over its definition, tears in which the ligament is not completely damaged are generally considered partial tears [3]. In clinical practice, physical examination and imaging

✉ Ethem Burak Oklaz
burakoklaz@gmail.com

[1] Department of Orthopaedics and Traumatology, Gazi University Faculty of Medicine, Emniyet Mahallesi, Mevlana Bulvarı No: 29 Yenimahalle, Ankara, Turkey

[2] Department of Radiology, Bilkent City Hospital, Ankara, Turkey

Published online: 16 March 2024

techniques such as magnetic resonance imaging (MRI) are commonly used for the diagnosis of this condition. As the Lachman test and pivot-shift test have limited accuracy in detecting partial tears, the value of imaging in these patients is even greater [1, 6]. MRI has a sensitivity of 92–100% and a specificity of 85–100% for diagnosing complete tears, but these rates are lower for incomplete tears [7, 8]. Instrumental laxity measurements may help to differentiate partial tears from complete tears, but are not useful in differentiating partial tears from intact ACLs unless there is a severe damage [9, 10]. For this reasons, these injuries are usually diagnosed by arthroscopic examination.

Differentiating partial tears is crucial for the patient's prognosis. Unnecessary surgical treatments could be prevented by distinguishing patients with partial tears who have the potential for recovery by conservative treatment from those with complete tears [10–13]. Moreover, distinguishing between patients with partial tears and those with intact ACLs can help avoid missed diagnoses and guide appropriate conservative or surgical treatment [10, 14]. The differentiation between partial and complete tears is also very important when deciding on the surgical technique. While ACL reconstruction is often the main surgical modality for complete tears, there are also options for treating partial tears, such as AM or PL bundle reconstruction [15, 16] and primary repair [17–19]. The distinction between partial and complete tears is therefore crucial in preoperative planning. To this end, several studies have been published using 3T MRI and specific MRI findings to achieve a more accurate diagnosis [8, 20, 21]. Although these studies have been helpful in identifying partial tears, there is currently a need for research that demonstrates high sensitivity and specificity in diagnosing them.

A review of the literature on secondary MRI findings revealed that, particularly in recent years, new studies have been conducted on the posterior cruciate ligament (PCL) buckling phenomenon [22, 23]. In sagittal MRI evaluations of patients with ACL injuries, the vertical component of the PCL becomes more upright as a result of increased anterior tibial translation (ATT). The PCL angle (PCLA) is the most commonly utilized method for assessing the degree of this finding (Fig. 1a) [24]. A more recent study also described the PCL-posterior cortex angle (PCL-PCA), which has been shown to have higher sensitivity and specificity in determining the degree of this finding (Fig. 1b) [23].

The purpose of this study is to assess the applicability of these two methods for diagnosing partial ACL tears, which are difficult to detect by MRI. We hypothesize is that these methods may be useful in the differential diagnosis of partial tears.

Methods

The study protocol was approved by the University Ethics Committee (Decision E-77082166-604.01.02-673921, research code: 2023 – 649) and adhered to the guidelines of the World Medical Association Declaration of Helsinki. In this study, video recordings and MRIs of patients who underwent arthroscopic surgery at a single institution between 2016 and 2022 were evaluated retrospectively. The data of 285 patients were collected prospectively. Patients with inflammatory arthritis, PCL or collateral ligament injury, patellofemoral malalignment, a history of previous knee surgery, bucket handle meniscus tears, meniscus root tears and complex meniscus tears were excluded from the study. The remaining 239 patients were included in the study. Demographic data, including age,sex and body mass index (BMI) were analyzed.

In the arthroscopic examination, both ACL bundles were examined using a probe. For a more accurate assessment, the PL bundle was also evaluated at Cabot's position (figure of four position) [25]. According to this, ACLs were categorized into 3 groups: group 1 A (46 patients) was considered

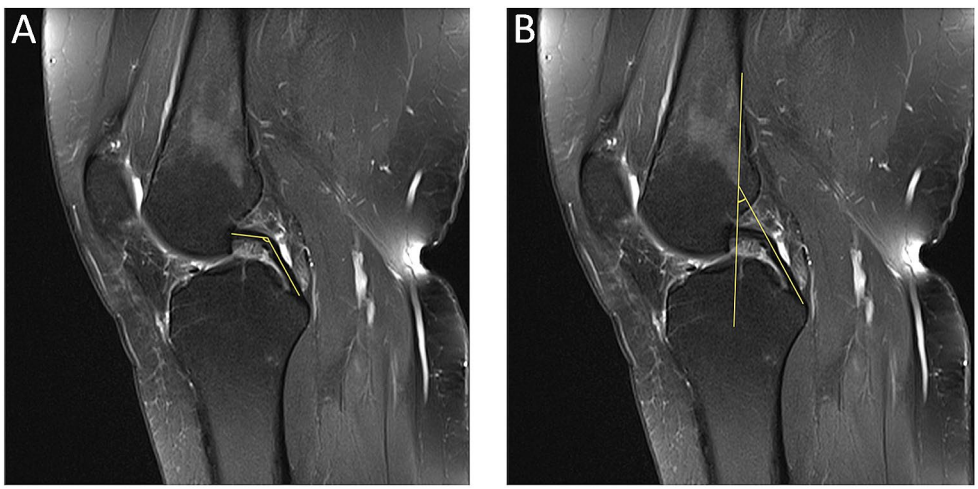

Fig. 1 Sagittal T2-weighted MRI of the knee showing PCLA **(a)** and PCL-PCA **(b)** views

to have an injury to the AM bundle with an intact PL bundle and group 1B (28 patients) was considered to have an injury to the PL bundle with an intact AM bundle, group 2 (74 patients) was considered to have complete tears and group 3 (91 patients) was considered to have intact ACLs.

MRI was performed on a 1.5-Tesla system (Signa, HiSpeed; General Electric Medical Systems, Milwaukee, WI, USA) with the patient in a supine position and the knee in extension. The imaging protocol included sagittal T2-weighted (time to response [TR]/time to echo [TE]: 2460/41) images. The field of view was 25 cm and the slice thickness/interslice gap was 3e4/0–1 mm in all sequences. In a small number of patients (6.7%, $n=16$) in whom the PCL could not be completely evaluated in a single sagittal slice, we used thin-slice 3D fast spin echo T2-weighted images, which are available in the routine knee MR protocol in our clinic and allow multiplanar reconstruction and angle correction.

The PCLA was determined to be the angle between a line through the central portion of the femoral insertion of the PCL and a line through the central portion of the tibial insertion of the PCL (Fig. 1a) [24]. The PCL-PCA method was evaluated on the sagittal plane view at the most lateral portion of the tibial insertion of the PCL. The angle was measured between a line drawn from the posterior diaphyseal cortex of the femur and a line parallel to the central portion of the most vertical part of the PCL (Fig. 1b) [23, 26]. Mean PCLA and PCL-PCA compared among the groups. Subsequently, the sensitivity and specificity of these two methods for distinguishing partial tears from those of the other groups were assessed. The medial posterior tibial slope (MPTS) and lateral posterior tibial slope (LPTS) were measured from sagittal MR images of the patients [27]. The relationships of these tibial slope values with the PCLA and PCL-PCA were evaluated.

MRIs were evaluated by a radiologist and a knee surgeon who were blinded to the former radiologic reports and arthroscopic results. Arthroscopic surgery video recordings were evaluated by two knee surgeons with at least 10 years of experience. To investigate intraobserver reliability, the same observer reevaluated all MRI or video records at intervals of more than 2 weeks from the initial evaluation. To evaluate interobserver reliability, another observer similarly evaluated all the video records or MRIs randomly.

The sample size calculation was performed with an aim to account for a 20% difference in complication rates between the two groups. The significance level (alpha) was set at 5% and the desired statistical power was 80%. Consequently, each group initially included 28 participants. However, in order to enhance the statistical power of the study, a decision was made to screen all eligible patients from the archive of the current institute where the study was conducted [23].

Statistical analysis

Statistical analysis and graphics editing were performed using IBM SPSS 26.0 (IBM Corp., Armonk, NY., USA). Measurement data were reported as mean ± standard deviation (range of values), while nominal data were presented as numbers and percentages. To attain both inter-rater and intra-rater reliability, a mixed-effects model was employed, treating reviewer-rater discrepancies as fixed effects. The assessment utilized the inter-class correlation coefficient (ICC) for absolute agreement, taking into account the mean of the scores provided by the two reviewers. Consistently high inter-rater agreement was observed for all measures, as indicated by ICC values exceeding 0.8. The MPTS and LPTS data were split based on the intactness of the anterior cruciate ligament. Subsequent analysis, employing Spearman's rho correlation coefficient, sought to determine the relationships PCLA and PCL-PCA with both medial and lateral posterior tibial slope measurements.

The chi-square test was employed to compare categorical variables, the ANOVA test was used for comparing binary measurement data in independent groups, and the Kruskal-Wallis test was utilized when normal distribution assumptions were not met. Post-hoc pairwise analyses were conducted following multiple group comparisons. A significance level of $p<0.05$ was considered statistically significant, and Bonferroni correction was applied to adjust p-values for the pairwise analyses. ROC analysis was employed to determine the cut-off measurements complete and partial tears. The performance of the measurements was assessed using the area under the ROC curve (AUC). AUC values between 0.9 and 1 were classified as excellent, values between 0.8 and 0.9 as good, values between 0.7 and 0.8 as fair, values between 0.6 and 0.7 as poor, and values between 0.5 and 0.6 as failed [28, 29].

Results

A retrospective review was conducted on a total of 239 patients who were included in the study. Of these patients, 171 were male and 68 were female, with a mean age of 33.09 ± 11.70 years and a median age of 32.5 years (range, 13–52) at the time of surgery. There was no statistically significant difference between the groups in terms of mean age or BMI ($p=0.3$ and $p=0.2$, respectively) (Table 1). There were 67 meniscal injuries, 12 patellofemoral disorders and 12 osteochondral defects in the intact ACL group.

Table 1 Comparison of measurement methods and demographics in 3 groups

	Group 1		Group 2	Group 3
	A	B		
n	46	28	74	91
Age	34.33 ± 14.65	31.05 ± 13.34	30.8 ± 8.83	33.05 ± 10.91
Gender (F/M)	15/31	8/20	7/67	38/53
BMI	24.1 ± 2.4	23.7 ± 2.6	24.3 ± 2.2	24.6 ± 2.1
PCLA	116.47 ± 4.89	118.35 ± 5.47	109.97 ± 5.90	129.11 ± 5.85
PCL-PCA	19.73 ± 3.30	18.75 ± 3.15	14.26 ± 2.47	31.25 ± 5.24
Medial PTS	6.30 ± 2.50	6.39 ± 1.96	6.52 ± 2.15	6.11 ± 2.32
Lateral PTS	6.71 ± 2.43	6.87 ± 1.98	6.97 ± 2.12	5.61 ± 2.22

BMI: Body Mass Index, PCLA: Posterior Cruciate Ligament Angle, PCL-PCA: Posterior Cruciate Ligament-Posterior Cortex Angle, PTS: Posterior Tibial Slope

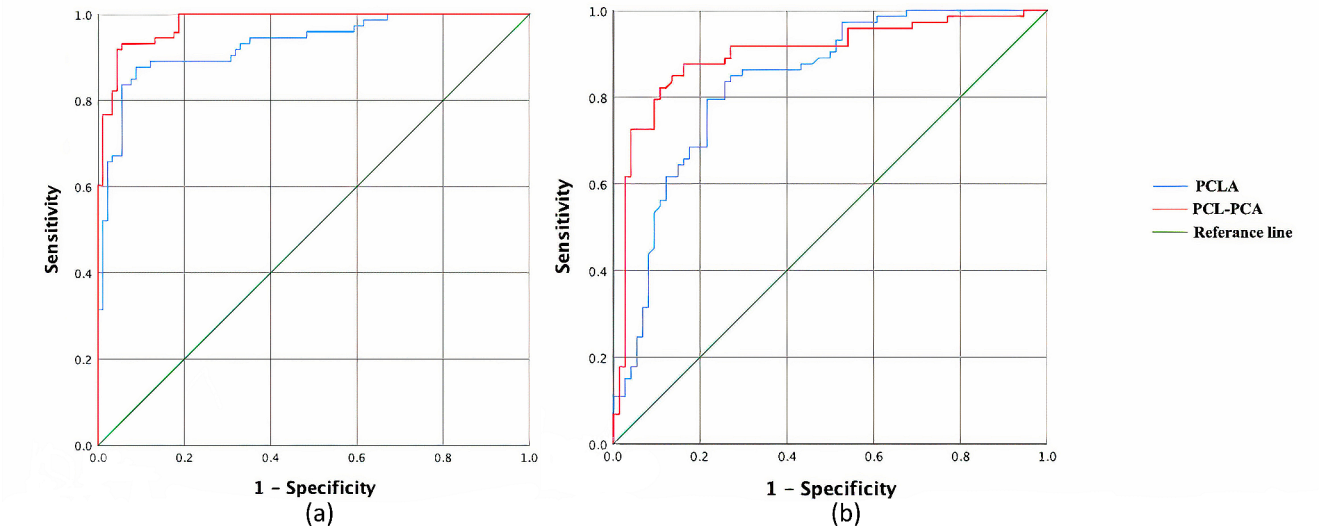

Fig. 2 ROC curves to compare the ability of the PCLA and PCL–PCA methods to discriminate between group 1- group 3 **(a)** and group 1- group 2 **(b)**

Table 2 Comparison of the PCLA and PCL–PCA methods in their ability to discriminate between groups

	AUC (95% CI)	p	Cut-off	Sensitivity (%)	Specificity (%)	+LHR	PPV (%)	NPV (%)	SEM	ES
Partial ACL Tear - Intact ACL										
PCLA	0.930 (0.890–0.970)	< 0.001	123.13°	86.8	89.9	7.92	86.8	89.0	0.020	0.93
PCL-PCA	0.980 (0.963–0.996)	< 0.001	23.77°	94.5	93.2	13.64	94.5	93.2	0.008	0.98
Partial ACL Tear - Complete ACL Tear										
PCLA	0.835 (0.770–0.901)	< 0.001	113.88°	79.5	78.4	3.67	79.5	78.4	0.033	0.83
PCL-PCA	0.899 (0.844–0.953)	< 0.001	16.39°	86.1	85.3	6.28	84.9	86.5	0.028	0.89

ACL: Anterior Cruciate Ligament, PCLA: Posterior Cruciate Ligament Angle, PCL-PCA: Posterior Cruciate Ligament-Posterior Cortex Angle, +LHR: Positive Likelihood Ratio, PPV: Positive Predictive Value, NPV: Negative Predictive Value, SE: Standart Error of Measurement, ES: Effect Size

The mean values of the PCLA and PCL-PCA were found to be significantly different among the three groups of patients ($p < 0.05$) (Table 1). There was no significant difference in the mean values of PCLA and PCL-PCA between group 1A and group 1B ($p = 0.24$) (Table 1). The analysis of MPTS and LPTS results by group revealed no statistically significant correlation between PCLA and PCL-PCA with both medial or lateral PTS ($p > 0.05$ for all values) (Table 1).

When evaluating knees with partial tears and intact ligaments, both the PCLA and PCL-PCA methods were found to differentiate partial tears with high sensitivity and specificity by determining specific cut-off values (PCLA: < 123.13°, PCL-PCA: < 23.77°). Similarly, the same methods could be used to differentiate partial tears from complete tears (Cut-off values; PCLA: > 113.88°, PCL-PCA: > 16.39°). The PCL-PCA angle is slightly more effective at making this distinction (Fig. 2; Table 2).

Discussion

The most important finding of this study is that the PCL buckling phenomenon, which is used to diagnose complete ACL tears, can also be a useful method for differentiating partial tears. PCLA between 113°- 123° and PCL-PCA between 16°- 24° could be a sign for a partial ACL tears. The differentiation between partial tears with an intact ACLs and complete tears is crucial for determining patient prognosis and treatment methods. Conservative treatment can be effective for partial tears in children, adolescents and adults without high activity levels, especially for those with an intact synovial sheath and without symptomatic knee instability [10–12]. In these patients, distinguishing between a partial tear and a complete tear may be crucial in avoiding unnecessary surgery. On the other hand, conservative treatment may give less satisfactory results for high-demand young patients who are performing contact sports and want to return to sports in the short term. In these patients, if a partial tear is diagnosed early, repair may be performed without progression to a complete tear, and better clinical results can be achieved [14, 30–32]. As physical examination findings may not be clear in patients with partial tears, diagnostic imaging is usually necessary to diagnose and determine treatment decisions.

Despite the need for imaging in diagnosis, studies in the literature suggest that MRI, which is the gold standard method for determining ACL injuries, is inadequate for diagnosing partial tears. Van Dyck et al. investigated whether the findings used for the diagnosis of complete tears by MRI could also be applied to patients with partial tears [20]. This study revealed that abnormal ligament signal intensity can contribute to diagnosis with a sensitivity of 71%, but findings such as discontinuity and abnormal morphology have low sensitivity in assessing partial tears. In addition, the same study indicated that secondary MR signs, which are valuable in diagnosing ACL injuries, are not sufficient for differentiating between partial and complete tears. Lefevre et al. suggested that the appearance of a mobile stump resulting from a partial tear on MR imaging could be useful in the diagnosis [21]. Despite the high specificity of this finding, its sensitivity was found to be quite low. Günaydin et al. reported that partial tears were more easily diagnosed on MR images taken while the patient was in the prone position and with the knee flexed [33]. Although this method provides better images for assesing the ACL, the challenge of standardization may make its general use difficult. Other studies on this topic have also noted the difficulty of diagnosing partial ACL tears by using MRI and have stated that there is a need for new perspectives and research on this subject [1, 9].

We suggest that the utilization of the PCL buckling phenomenon holds promise as a valuable method for assessment. PCLA is commonly used to evaluate this phenomenon. Different cut-off values of this angle were previously defined (< 105–118°) and found to be useful for diagnosis with a sensitivity of 52–74% and a specificity of 71–94% [23, 24, 34, 35]. In our study, similar to the values in the literature, the probability of diagnosing a complete tear increased significantly when the PCLA decreased below 113°. In the differential diagnosis of partial tears, which is our main objective, this method was able to detect tears significantly between 113–123°.

Siboni et al. described the PCL-PCA method in a study evaluating PCL buckling phenomenon in 24 patients with ACL injury [23]. In this study, when ACL injuries were not categorized as partial or complete, the PCL-PCA cut-off value was found to be 22.65°, and it has been reported that ACL injuries can be diagnosed with 71% sensitivity and 88% specificity in knees with values less than this cut-off. An important result of this study was that the PCL-PCA method gave better results than did the PCLA method in evaluating the buckling phenomenon. The main difference between our study and this one is that we categorized ACL tears as partial and complete, and we included a larger number of patients. Our results support the findings of Siboni et al. because the PCL-PCA method has greater sensitivity and specificity than PCLA method for differentiating partial tears from complete tears and from intact ACLs.

The present study revealed no relationship between PCLA or PCL-PCA values and tibial slope. This may be because the tibial slope was correlated with preoperative anterior knee laxity, whereas the buckling phenomenon was not correlated with the degree of laxity [36–40]. Since there is limited information on this subject in the literature, more studies are needed to evaluate the PCL buckling phenomenon in relation to femur and tibia morphology.

Zantop et al. demonstrated that there was a significant increase in ATT at 60° and 90° of flexion in patients who underwent AM bundle transection, and this increase was significant at 30° of flexion in patients who underwent PL bundle transection [41]. On the basis of our study, we believe that the reason for the nonsignificant difference in the mean PCLA and PCL-PCA between patients with AM and PL bundle tears is that the MRI were taken during knee extension.

One of the main advantages of these methods is that they are easy to assess on MRI. Unlike secondary signs of ACL tears, which can be challenging to identify on MRI, PCL buckling is readily visible in the sagittal view. This clear visualization of PCL buckling on MRI scans can be highly beneficial for diagnosing partial tears.

There are several limitations of our study. This is a retrospective study in which the data were collected prospectively. The results of the Lachman test, pivot shift test and laxity measurements of the patients under anesthesia are not available in our study. Therefore, no correlation analysis could be performed between these clinical instability tests and PCLA or PCL-PCA values. However, Chang et al. did not find any relationship between PCL buckling with Lachman test and pivot shift test in their study [42]. The PCL buckling phenomenon becomes more noticeable with chronic ACL injury [23]. Unfortunately, we did not have enough information about the date of the patients' injuries in our study. Therefore, we do not have information on the time between the injury and the dates of the MRI examination and surgery in the conducted study. Another limitation of presented study is that we did not investigate the relationship between the morphological structure of the tibia and femur with the PCLA or PCL-PCA methods, except for the PTS. Further studies are needed to investigate the relationship between measurement methods that examine the PCL buckling phenomenon and knee ligaments and bone morphology.

Conclusion

Evaluation of the PCL buckling phenomenon using the PCLA and PCL-PCA methods may be useful in the differential diagnosis of partial tears. PCLA between 113° – 123° and PCL-PCA between 16° – 24° could indicate a partial ACL tear. With these methods, it is possible to distinguish partial tears from healthy knees and reduce missed diagnoses. In addition, the differentiation of partial and complete tears by these methods may prevent unnecessary surgical interventions.

Supplementary Information The online version contains supplementary material available at https://doi.org/10.1007/s00402-024-05270-0.

Funding No funding was disclosed by the authors.
Open access funding provided by the Scientific and Technological Research Council of Türkiye (TÜBİTAK).

Ethical approval The study protocol was approved by Gazi University Ethics Committee (Decision E-77082166-604.01.02-673921, research code: 2023 – 649).

Conflict of interest The authors and any research foundation with which they are affiliated have not received any financial payments or other benefits from any commercial entity related to the subject of this article.

Open Access This article is licensed under a Creative Commons Attribution 4.0 International License, which permits use, sharing, adaptation, distribution and reproduction in any medium or format, as long as you give appropriate credit to the original author(s) and the source, provide a link to the Creative Commons licence, and indicate if changes were made. The images or other third party material in this article are included in the article's Creative Commons licence, unless indicated otherwise in a credit line to the material. If material is not included in the article's Creative Commons licence and your intended use is not permitted by statutory regulation or exceeds the permitted use, you will need to obtain permission directly from the copyright holder. To view a copy of this licence, visit http://creativecommons.org/licenses/by/4.0/.

References

1. Colombet P, Dejour D, Panisset JC, Siebold R (2010) Current concept of partial anterior cruciate ligament ruptures. Orthop Traumatol Surg Res 96. https://doi.org/10.1016/j.otsr.2010.09.003
2. Sonnery-Cottet B, Barth J, Graveleau N et al (2009) Arthroscopic identification of isolated tear of the posterolateral bundle of the anterior cruciate ligament. Arthroscopy 25:728–732. https://doi.org/10.1016/J.ARTHRO.2008.12.018
3. DeFranco MJ, Bach BR (2009) A comprehensive review of partial anterior cruciate ligament tears. J Bone Jt Surg 91:198–208. https://doi.org/10.2106/JBJS.H.00819
4. Noyes FR, Mooar LA, Moorman CT, McGinniss GH (1989) Partial tears of the anterior cruciate ligament. Progression to complete ligament deficiency. J Bone Joint Surg Br 71:825–833. https://doi.org/10.1302/0301-620X.71B5.2584255
5. Hong SH, Choi JY, Lee GK et al (2003) Grading of anterior cruciate ligament injury. Diagnostic efficacy of oblique coronal magnetic resonance imaging of the knee. J Comput Assist Tomogr 27:814–819. https://doi.org/10.1097/00004728-200309000-00022
6. Jog AV, Smith TJ, Pipitone PS et al (2020) Is a partial anterior cruciate ligament tear truly partial? A clinical, arthroscopic, and histologic investigation. Arthrosc J Arthrosc Relat Surg 36:1706–1713. https://doi.org/10.1016/J.ARTHRO.2020.02.037
7. Li K, Du J, Huang LX et al (2017) The diagnostic accuracy of magnetic resonance imaging for anterior cruciate ligament injury in comparison to arthroscopy: a meta-analysis. Sci Rep 7. https://doi.org/10.1038/S41598-017-08133-4
8. Steckel H, Vadala G, Davis D et al (2007) 3-T MR imaging of partial ACL tears: a cadaver study. Knee surgery. Sport Traumatol Arthrosc 15:1066–1071. https://doi.org/10.1007/s00167-007-0337-5
9. Dejour D, Ntagiopoulos PG, Saggin PR, Panisset JC (2013) The diagnostic value of clinical tests, magnetic resonance imaging, and instrumented laxity in the differentiation of complete versus partial anterior cruciate ligament tears. Arthrosc - J Arthrosc Relat Surg 29:491–499. https://doi.org/10.1016/j.arthro.2012.10.013
10. DeFranco MJ, Bach BR (2009) A comprehensive review of partial anterior cruciate ligament tears. J Bone Joint Surg Am 91:198–208. https://doi.org/10.2106/JBJS.H.00819
11. Kocher MS, Micheli LJ, Zurakowski D, Luke A (2002) Partial tears of the anterior cruciate ligament in children and adolescents. Am J Sports Med 30:697–703. https://doi.org/10.1177/03635465020300051201
12. Blanke F, Trinnes K, Oehler N et al (2023) Spontaneous healing of acute ACL ruptures: rate, prognostic factors and short-term outcome. Arch Orthop Trauma Surg 143:4291–4298. https://doi.org/10.1007/S00402-022-04701-0
13. Moon HS, Choi CH, Kim S et al (2023) Outpatient-based diagnostic criteria for partial ACL injury: clinical outcomes of non-operative treatment and radiographic predictor. Arch Orthop Trauma Surg 143:2027–2036. https://doi.org/10.1007/S00402-022-04467-5/TABLES/4

14. Colombet P, Dejour D, Panisset JC, Siebold R (2010) Current concept of partial anterior cruciate ligament ruptures. Orthop Traumatol Surg Res 96:S109–S118. https://doi.org/10.1016/J.OTSR.2010.09.003
15. Sonnery-Cottet B, Lavoie AF, Ogassawara AR et al Selective anteromedial bundle reconstruction in partial ACL tears: a series of 36 patients with mean 24 months follow-up. https://doi.org/10.1007/s00167-009-0855-4
16. Siebold R, Fu FH (2008) Assessment and Augmentation of symptomatic anteromedial or posterolateral bundle tears of the anterior cruciate ligament. Arthroscopy 24:1289–1298. https://doi.org/10.1016/J.ARTHRO.2008.06.016
17. Basad E, Stürz H, Ishaque B, Spor L (2012) Arthroscopic primary repair of fresh partial ACL tears. Sport Inj Prev Diagnosis Treat Rehabil379–385.https://doi.org/10.1007/978-3-642-15630-4_52/COVER
18. Tapasvi SR, Shekhar A, Patil SS (2018) Primary anterior cruciate ligament repair with augmentation. Arthrosc Tech 7:e139–e145. https://doi.org/10.1016/J.EATS.2017.08.063
19. Gobbi A, Whyte GP (2018) Long-term outcomes of primary repair of the Anterior Cruciate Ligament Combined with Biologic Healing Augmentation. 3368–3377. https://doi.org/101177/0363546518805740 46. to Treat Incomplete Tears
20. Van Dyck P, Vanhoenacker FM, Gielen JL et al (2011) Three tesla magnetic resonance imaging of the anterior cruciate ligament of the knee: can we differentiate complete from partial tears? Skeletal Radiol 40:701–707. https://doi.org/10.1007/s00256-010-1044-8
21. Lefevre N, Naouri JF, Bohu Y et al (2014) Sensitivity and specificity of bell-hammer tear as an indirect sign of partial anterior cruciate ligament rupture on magnetic resonance imaging. Knee surgery. Sport Traumatol Arthrosc 22:1112–1118. https://doi.org/10.1007/s00167-013-2511-2
22. Gali JC, Almeida TA, de Moraes Miguel DC et al (2022) The posterior cruciate ligament inclination angle is higher in anterior cruciate ligament insufficiency. Knee Surg Sport Traumatol Arthrosc 30:124–130. https://doi.org/10.1007/s00167-021-06789-0
23. Siboni R, Pioger C, Mouton C, Seil R (2023) The posterior cruciate ligament–posterior femoral cortex angle: a reliable and accurate MRI method to quantify the buckling phenomenon of the PCL in ACL-deficient knees. Knee Surg Sport Traumatol Arthrosc 31:332–339. https://doi.org/10.1007/s00167-022-07145-6
24. McCauley TR, Moses M, Kier R et al (1994) MR diagnosis of tears of anterior cruciate ligament of the knee: importance of ancillary findings. Am J Roentgenol 162:115–119. https://doi.org/10.2214/ajr.162.1.8273648
25. Sonnery-Cottet B, Chambat P (2007) Arthroscopic identification of the anterior cruciate ligament posterolateral bundle: the figure-of-four position. Arthroscopy 23. https://doi.org/10.1016/J.ARTHRO.2006.11.028. :1128.e1-1128.e3
26. Schweitzer ME, Cervilla V, Kursunoglu-Brahme S, Resnick D (1992) The PCL line: an indirect sign of anterior cruciate ligament injury. Clin Imaging 16:43–48. https://doi.org/10.1016/0899-7071(92)90090-V
27. Hudek R, Schmutz S, Regenfelder F et al (2009) Novel measurement technique of the tibial slope on conventional MRI. Clin Orthop Relat Res. https://doi.org/10.1007/S11999-009-0711-3. 467:2066
28. Böhning D, Holling H, Patilea V (2011) A limitation of the diagnostic-odds ratio in determining an optimal cut-off value for a continuous diagnostic test. Stat Methods Med Res 20:541–550. https://doi.org/10.1177/0962280210374532
29. Metz CE (1978) Basic principles of ROC analysis. Semin Nucl Med 8:283–298. https://doi.org/10.1016/S0001-2998(78)80014-2
30. Rai SK, Gupta TP, Singh VB et al (2022) Retrospective analysis and risk of progression of partial anterior cruciate ligament injuries in a young population. Arch Orthop Trauma Surg 143:2063–2071. https://doi.org/10.1007/s00402-022-04519-w
31. Fayard JM, Sonnery-Cottet B, Vrgoc G et al (2019) Incidence and risk factors for a partial anterior cruciate ligament tear progressing to a complete tear after nonoperative treatment in patients younger than 30 years. Orthop J Sport Med 7. https://doi.org/10.1177/2325967119856624
32. Stone AV, Marx S, Conley CW (2021) Management of partial tears of the anterior cruciate ligament: a review of the anatomy, diagnosis, and treatment. J Am Acad Orthop Surg 29:60–70. https://doi.org/10.5435/JAAOS-D-20-00242
33. Gunaydin B, Sahin GG, Sari A et al (2019) A new method for diagnosis of anterior cruciate ligament tear: MRI with maximum flexion of knee in the prone position: a case control study. Int J Surg 68:142–147. https://doi.org/10.1016/j.ijsu.2019.06.017
34. Gentili A, Seeger LL, Yao L, Do HM (1994) Anterior cruciate ligament tear: indirect signs at MR imaging. Radiology 193:835–840. https://doi.org/10.1148/RADIOLOGY.193.3.7972834
35. Mellado JM, Calmet J, Olona M et al (2004) Magnetic resonance imaging of anterior cruciate ligament tears: reevaluation of quantitative parameters and imaging findings including a simplified method for measuring the anterior cruciate ligament angle. Knee Surg Sports Traumatol Arthrosc 12:217–224. https://doi.org/10.1007/S00167-003-0431-2
36. Dejour D, Pungitore M, Valluy J et al (2019) Preoperative laxity in ACL-deficient knees increases with posterior tibial slope and medial meniscal tears. Knee Surg Sports Traumatol Arthrosc 27:564–572. https://doi.org/10.1007/S00167-018-5180-3
37. Wang D, Kent RN, Amirtharaj MJ et al (2019) Tibiofemoral Kinematics during Compressive Loading of the ACL-Intact and ACL-Sectioned knee: roles of tibial slope, medial eminence volume, and Anterior Laxity. J Bone Joint Surg Am 101:1085–1092. https://doi.org/10.2106/JBJS.18.00868
38. Oronowicz J, Mouton C, Pioger C et al (2023) The posterior cruciate ligament-posterior femoral cortex angle (PCL-PCA) and the lateral collateral ligament (LCL) sign are useful parameters to indicate the progression of knee decompensation over time after an ACL injury. Knee Surg Sports Traumatol Arthrosc 31:5128–5136. https://doi.org/10.1007/S00167-023-07583-W
39. Yoo JD, Lim HM (2012) Morphologic changes of the posterior cruciate ligament on magnetic resonance imaging before and after Reconstruction of Chronic Anterior Cruciate Ligament ruptures. Knee Surg Relat Res 24:241–244. https://doi.org/10.5792/KSRR.2012.24.4.241
40. Yang CP, Hung SF, Lin KY et al (2023) The increased lateral tibial slope may result in inferior long-term clinical outcome after DB-ACL reconstruction. Arch Orthop Trauma Surg. https://doi.org/10.1007/s00402-023-05114-3
41. Zantop T, Herbort M, Raschke MJ et al (2007) The role of the anteromedial and posterolateral bundles of the anterior cruciate ligament in anterior tibial translation and internal rotation. Am J Sports Med 35:223–227. https://doi.org/10.1177/0363546506294571
42. Chang MJ, Chang CB, Choi JY et al (2014) Can magnetic resonance imaging findings predict the degree of knee joint laxity in patients undergoing anterior cruciate ligament reconstruction? BMC Musculoskelet Disord 15:1–12. https://doi.org/10.1186/1471-2474-15-214/TABLES/3

Publisher's Note Springer Nature remains neutral with regard to jurisdictional claims in published maps and institutional affiliations.