© 2016 Chinese Orthopaedic Association and John Wiley & Sons Australia, Ltd

CASE REPORT

Musculoskeletal Hydatid Cysts Resembling Tumors: A Report of Five Cases

Güray Toğral, MD[1], Şefik M Arıkan, MD[1], Timur Ekiz, MD[2], Ahmet F Kekeç, MD[1], Mehmet F Ekşioğlu, MD[1]

[1]*Department of Orthopaedics and Traumatology, Oncology Training and Research Hospital and* [2]*Department of Physical and Rehabilitation Medicine, Ankara Physical Medicine and Rehabilitation Training and Research Hospital, Ankara, Turkey*

Although challenges in treatment of musculoskeletal hydatid cysts (HC) lesions have been documented, data regarding the musculoskeletal HC lesions resembling tumor is scarce. This paper presented 5 patients (3 males, 2 females) with a mean age of 41.6 years with tumor-like lesions of HC. Three of them had left ilium and acetabulum involvement, one involved left femur, and one involved left thigh muscle compartments. Pain was the main symptom and was seen in all patients. Clinical examination, radiologic evaluation, and histologic analysis were performed for diagnosis. Patients were treated through different surgical options, including simple debridement, bone cement filling with or without internal fixation, hip arthrodesis, reconstruction using hemipelvic replantation with femoral prosthesis and distal femur endoprosthetic replacement. After surgery, the operation region was washed by 20% hypertonic saline, and debridement was performed carefully without contamination. All patients received albendazole treatment. Cases were followed up 1 to 9 years for the recurrence. Walking difficulty and pain were the main symptoms during the follow-up. One patient was symptom-free. A reoccurrence in the perioperative soft tissue was detected in only one patient and control visits with antihelmintic treatment were recommended. We would like to emphasize that HC should be kept in mind for the differential diagnosis of the cystic or tumoral lesions of the musculoskeletal system, particularly in the endemic regions. Prompt diagnosis is of paramount importance for preventing destruction and complications.

Key words: Hydatic cyst; Echinococcosis granulosus; Iliac wing; Muscle hydatidosis

Introduction

Echinococcosis is a parasitic and zoonotic disease of animals and humans that is usually caused by *Echinococcus granulosus* but occasionally by *E. multilocularis*[1–3]. Liver and lung involvements are the most common manifestations, musculoskeletal involvement by hydatid cysts (HCs) being found in less than 5% of cases[1].

Treatment of bone and muscle involvement by HCs is challenging. First, because the clinical presentation can be insidious, the diagnosis can initially be missed and the correct diagnosis not made until the disease is in its late stages[3–5]. Second, the bony lesions of HC can spread to the articular surface and present like malignant tumors, including resulting in pathological dislocation and total joint destruction[4]. Because of the invasive nature of this infection, eradication of the parasite cannot be guaranteed by surgery, recurrence rates reportedly being as high as 48%[5]. Third, although removal of the cysts combined with an antihelminthic drug (usually albendazole) is otherwise the optimal treatment choice, there are currently no drugs that are effective for treating HCs that are invading bone and muscle[3–6].

As to reports of HC lesions resembling tumors, various manifestations such as disseminated alveolar echinococcosis with bone involvement, peritoneal involvement and thoracic wall with soft tissue involvement have been reported[7–9]. Although some challenges associated with musculoskeletal HC lesions have been documented in case reports and reviews, there are few published data regarding musculoskeletal HC lesions resembling tumors[10–13].

Accordingly, the objectives of this paper were (i) to present the clinical features of tumor-like HC lesions with musculoskeletal involvement treated by our clinic; (ii) to compare the clinical features of HC with those of tumors; (iii) to discuss imaging and treatment options for musculoskeletal HC; and (iv) highlight the importance of prompt

Address for correspondence Timur Ekiz, MD, Department of Physical and Rehabilitation Medicine, Ankara Physical Medicine and Rehabilitation Training and Research Hospital, Türkocağı St. No 3 Sıhhiye, Ankara, Turkey 06230 Tel: 0090-312-3103230; Fax: 0090-312-3118054; Email: timurekiz@gmail.com

Disclosure: All authors declare no conflicts of interest.
Received 12 January 2015; accepted 13 February 2016

Orthopaedic Surgery

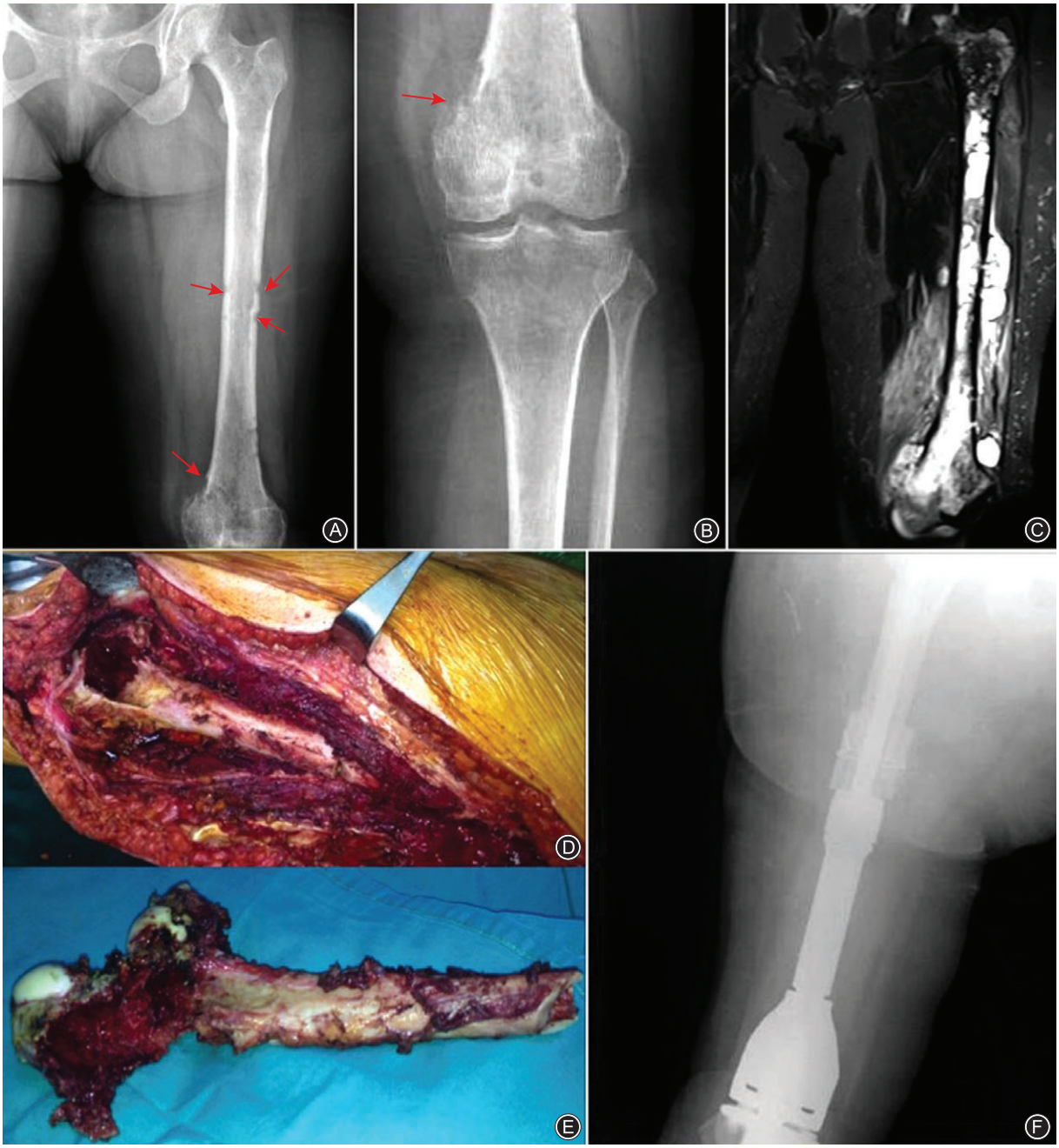

Fig. 1 Illustrative case of a 45-year-old woman who presented with left thigh pain for 8 months. (A, B) X-ray films of the femur showing cortical erosions (arrows). (C) T2-weighted MRI (coronal view showing multiple contrast-enhanced (peripheral and septal) intra- and extra-medullary cystic lesions, extending into the vastus intermedius muscle and causing cortical destruction. (D, E) Debridement was performed and (F) a distal femur resection prosthesis inserted.

diagnosis and treatment in preventing destruction and complications.

Case Reports

Informed consent was obtained from each patient to report details of their case.

Case 1

A 45-year-old woman presented with left thigh pain for 8 months. A dog had bitten her in the lateral distal part of that thigh 17 years previously. The pain increased with weight-bearing activities. Physical examination revealed swelling and tenderness on deep palpation of the left thigh.

No pathologically enlarged lymph nodes were detected by palpation. Laboratory findings, including erythrocyte sedimentation rate (ESR), C-reactive protein (CRP), and complete blood count were within normal limits. Plain radiography showed cortical erosions of the distal femur and radiodense areas in the proximal and distal diaphyseal–metaphyseal part of the femur. (Fig. 1A,B). Magnetic resonance imaging (MRI) of the femur demonstrated multiple contrast-enhanced (peripheral and septal) intra- and extramedullary cystic lesions that were invading the muscle compartments and causing cortical destruction (Fig. 1C). Indirect hemagglutination for HC was positive (1/1280). Abdominal ultrasonography showed calcified HCs in the liver. Under spinal anesthesia, the patient was placed in a supine position on the operating table and a long medial incision made, beginning in the mid-thigh, crossing the knee along the medial patellar area and distal to the tibial tubercle, and then curving slightly posteriorly to the pes anserine tendons. The popliteal space was approached by detaching the ligaments and retracting the medial hamstrings. The distal femur was then approached via the gap between the rectus femoris and vastus medialis, leaving the intact vastus intermedius over the distal femur. Distal femur osteotomy was performed at the appropriate location according to preoperative imaging studies. The operation region was then washed with 20% hypertonic saline, following which a tibial osteotomy was performed to allow introduction of the prosthetic tibial component. The canal was reamed 2 mm larger than the chosen stem diameter. Thereafter, a definitive modular prosthesis was assembled. The cementing technique involved pulsatile lavage, use of an intramedullary cement restrictor, reduction of the cement by centrifugation, use of a cement gun, and pressurization of the cement. Special attention was given to covering the prosthesis completely with muscle tissue. The remaining vastus medialis was sutured to the rectus femoris (Fig. 1D,E). Immobilization was applied for 1 month postoperatively. Albendazole 10 mg/kg/day was given for 6 months. At the second month visit, the patient was diagnosed with a superficial wound infection and *Staphylococcus Epidermidis* was identified by culture. This wound infection was successfully treated with 4 months of antibiotic therapy. No HCs had recurred at the 1-year follow-up.

Case 2

A 45-year-old man was admitted with left hip pain. Physical examination revealed restriction of the left hip joint and pain during movement. Plain radiography showed radiolucency in the left iliac wing (Fig. 2A). MRI of the left hip showed multiple cystic lesions of the left iliac wing consistent with HCs (Fig. 2B,C). The patient was operated on in a supine position under spinal anesthesia utilizing an extended iliofemoral approach. After securing the neurovascular bundle, the cysts were excised with a wide surgical margin. After type III pelvic resection, the defects were reconstructed with a fresh-frozen hemipelvis allograft. The allograft was initially thawed in a saline solution and then shaped to the defect. Following this, the graft was rigidly fixed using pelvic reconstruction plates and cancellous screws. After rigid fixation of the allograft, its acetabulum was reamed and a cementless polyethylene acetabular component inserted, followed by insertion of a femoral component (Fig. 2D,E). Total hip arthroplasty was thus performed (Fig. 2F). The patient was also treated with anti-helminthic drugs for 6 months postoperatively (albendazole 15 mg/kg/day). Bone union was confirmed at the 1-year follow-up visit, when there was no evidence of recurrence. A soft tissue recurrence was detected at the postoperative 16th month follow-up visit and treated with albendazole; no further surgery was planned.

Case 3

A 51-year-old man was referred to our clinic because of left thigh and groin pain and a provisional diagnosis of malignant tumor. He stated that the pain had started 4 years previously and worsened over time. Physical examination revealed a 7 cm × 5 cm mass over the antero-medial left thigh. Ultrasonographic imaging of the abdomen was normal. Plain X-ray films were unremarkable (Fig. 3A). MRI showed multiple peripherally contrasted cystic lesions with lobulated contours within the muscle compartments of the anterior thigh without bone involvement (Fig. 3B,C). Under spinal anesthesia, the left thigh was incised approximately 10 cm anteromedial to the cysts. The cysts were totally excised and the operative field washed with 20% hypertonic saline. No visceral involvement was detected. An anti-helminthic drug was given for 6 months postoperatively. A 3 cm × 2 cm cystic lesion had recurred at the second year follow-up visit. Because this lesion was asymptomatic, it was not excised; rather, anti-helminthic drugs for a further 6 months (albendazole 15 mg/kg/day) were recommended.

Case 4

A 45-year-old woman was admitted because of pain and swelling of her left hip. The pain was initially insidious and had worsened over time. She gave a history of having undergone surgical excision of HCs in the left iliac wing 7 years previously and had received albendazole treatment for 6 months. The patient also stated that debridement had been performed four times for recurrences. Plain radiographs of the pelvis showed radiolucency of the left iliac wing (Fig. 4A, B). MRI showed a contrast-enhanced cystic lesion (HC) that had destroyed the left iliac wing and extended into the iliogluteal muscles (Fig. 4D,E). Under spinal anesthesia, the patient underwent surgical excision of the cyst (Fig. 4C) followed by washing of the operative field with hypertonic saline. Postoperatively, the patient was treated with albendazole 15 mg/kg/day for 6 months. Her pain improved moderately after the surgery. No recurrence was detected during a further 2-years of follow-up.

Case 5

A 22-year-old male animal breeder) was referred to our clinic because of a mass in the left iliac wing. Pelvic X-ray films

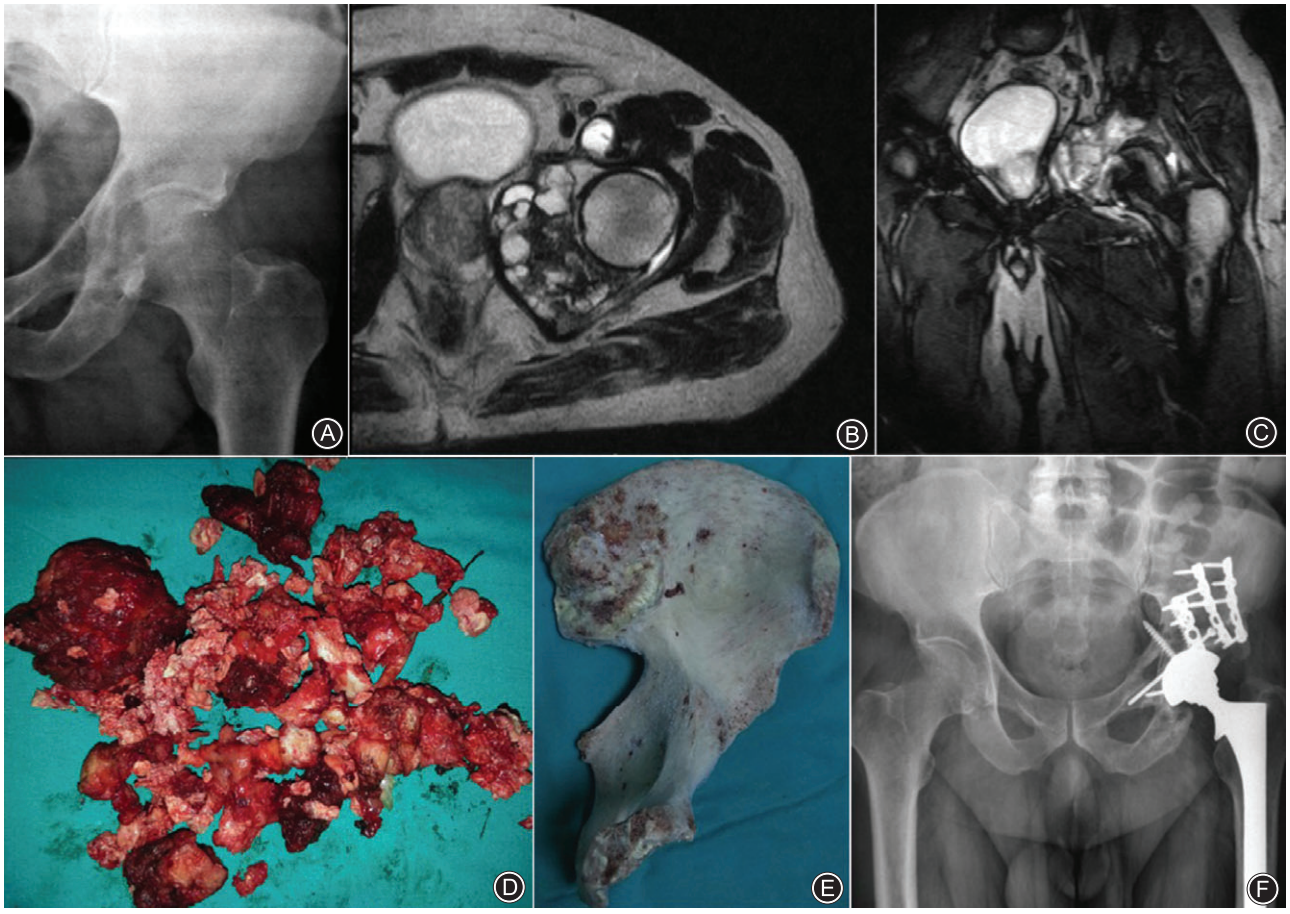

Fig. 2 Illustrative case of a 45-year-old man who was admitted with left hip pain. (A) X-ray film of the pelvis showing radiolucency of the left iliac bone. (B) T2-weighted axial and(C) coronal MRI showing multiple cystic lesions in the left iliac wing on T2-weighted axial and coronal views. (D, E) Hemipelvectomy and cyst excision were performed. (F) Postoperative radiograph showing total arthroplasty of the left hip joint.

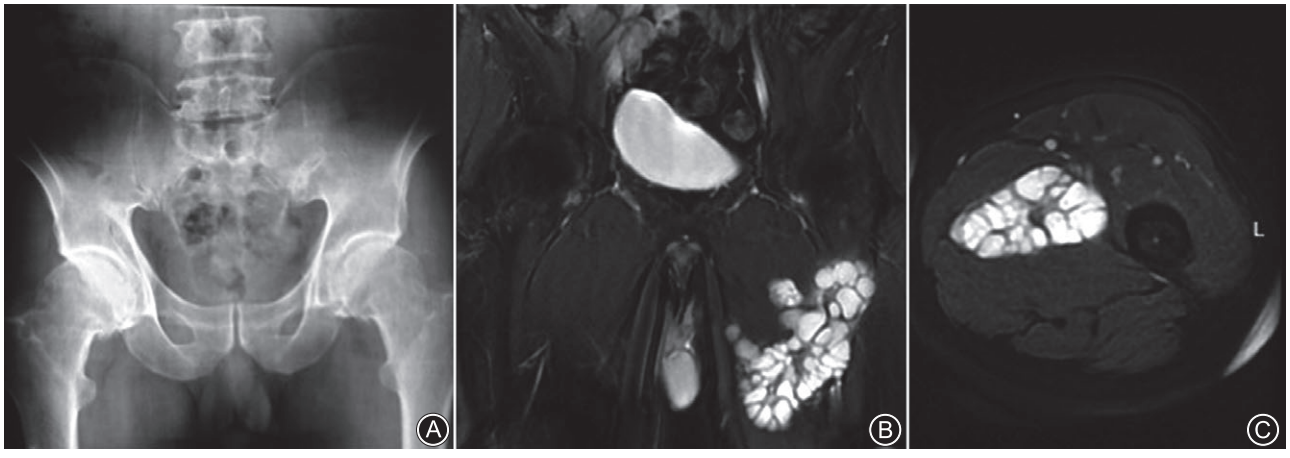

Fig. 3 Illustrative case of a 51-year-old man who presented with left thigh and groin pain. Physical examination revealed a 7 cm × 5 cm mass over the anteromedial aspect of the left thigh. (A) Anterior-posterior pelvic X-ray film is unremarkable. (B, C) MRI of the left thigh showing multiple cystic lesions (hyperintense) involving the pectineus, iliopsoas, and adductor magnus/brevis muscles on T2 weighted coronal and axial views. There is contrast enhancement in the periphery of the cysts.

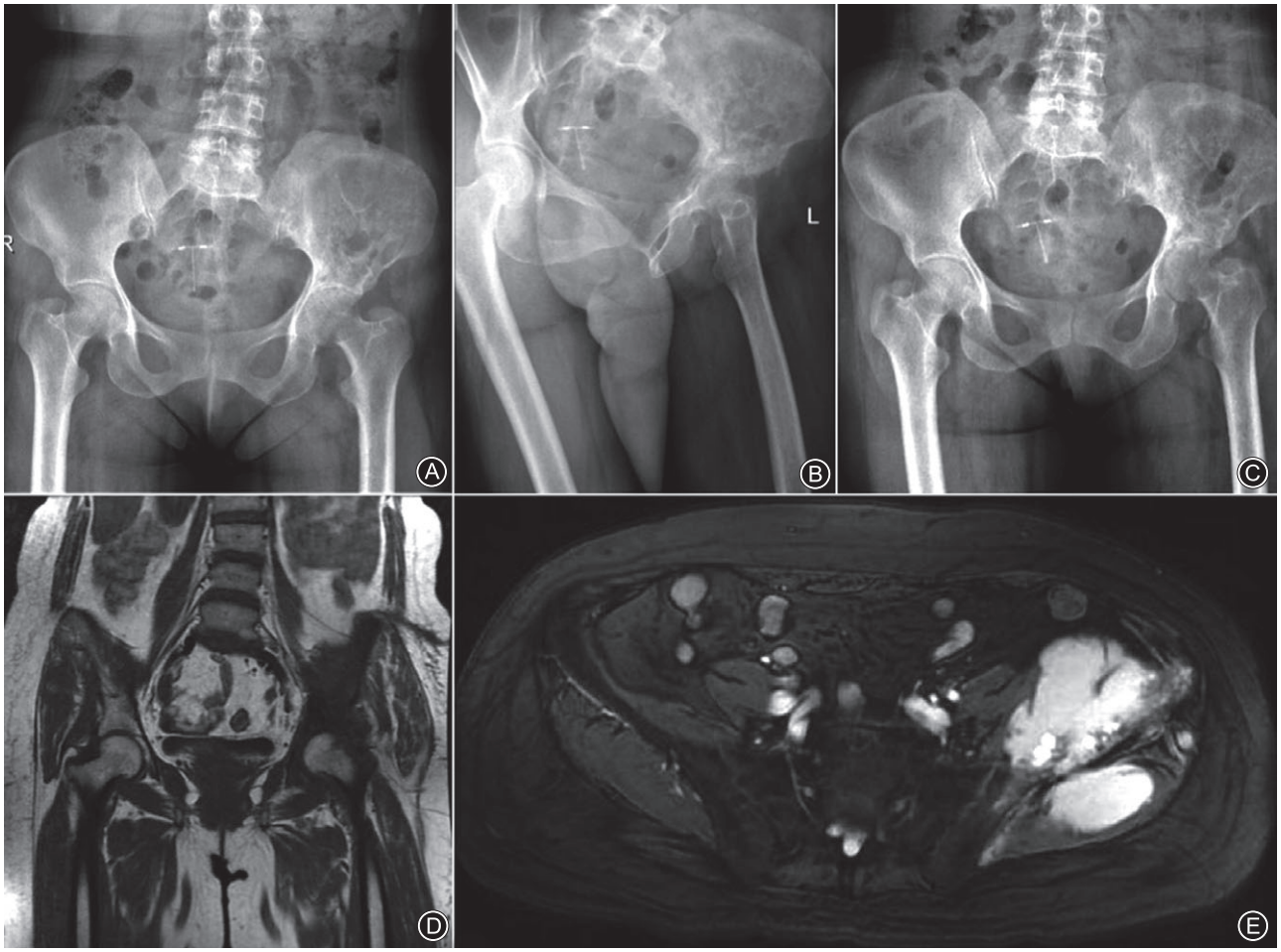

Fig. 4 Illustrative case of a 22-year-old male animal breeder who presented with a mass in the left iliac wing. (A, B) Anterior and lateral plain radiographs showing radiolucency of the left iliac bone (destruction). (C) X-ray belongs to the postoperative image of the pelvis after performing cystectomy. (D, E) T1-weighted coronal and T2-weighted axial MRI showing multiple cystic lesions causing destruction of the left iliac wing. The cysts have extended into the gluteal and iliac muscles and contain some include calcification.

showed a lytic lesion in the left iliac wing. Computed tomography (CT) showed a 4 cm × 4 cm multi-lobulated cyst causing destruction and extending into the left gluteal muscles. An abdominal ultrasound examination was normal. Indirect hemagglutination for HC was positive (1/2048). Under spinal anesthesia, the patient was treated by curettage of the mass and cementation with arthrodesis of the left hip joint and subsequently received albendazole for 6 months. Reoccurrence in the superior margin of acetabulum and adjacent soft tissues was detected at the 2-year follow-up visit. The patient was treated with albendazole; surgery was not performed. This patient had some difficulty with walking.

Discussion

Presentation of Musculoskeletal Hydatid Cysts

Bone echinococcosis is a rare parasitic infestation (less than 3% of cases) and is difficult to treat. Cystic or lytic lesions present in trabecular bone and may extend to other subcortical areas. Spongy tissue constitutes favorable ground for spreading of HCs. Slow growth of multiple vesicles results in replacement by the parasites of osseous tissue between the trabeculae. Over time, the parasites reach and destroy the cortex, with subsequent spread of the disease to surrounding tissues[4–6]. Hydatid disease is slowly progressive and presents with nonspecific lesions in the pelvic region. Pelvic involvement can present with pain, swelling and compression of various adjacent organs. Diagnosis of hydatid disease by radiological means may be difficult and its symptoms are often nonspecific. Four of our cases had bone and muscle involvement, the remaining one having only muscle involvement. Three of them had involvement of the iliac wing it and one proximal femur involvement.

Differential Diagnosis, Laboratory Investigations, and Imaging

Tumors and tumor-like lesions of bone, tuberculosis and some fungal infections should be considered in the

differential diagnosis. Differentiation between bone tumors and bone HCs i based on a detailed patient history, symptoms, radiological findings (ultrasound, X-ray, CT, MRI), and *Echinococcus* antibodies[14–17].

Patients with HCs may have mild and nonspecific increases in ESR, CRP concentration and eosinophil counts. Serological tests are important for differentiating HCs from conditions; however, they are not 100% reliable. Because there is high rate of false negative results, they only have confirmatory role. Imaging therefore plays the key role in both diagnosis and staging[18]. Ultrasound can be used as the first imaging tool; its advantages include its ease of application, lack of ionizing radiation, repeatability and that it is patient-friendly and cheaper than MRI and CT. Additionally, it is a good modality for detecting HCs[1]. Nonetheless, further investigation with MRI and CT are required to differentiate HCs from other soft tissue masses, cysts, infections and tumors[1,18]. Radiologically, musculoskeletal HCs mimic tumors and inflammatory conditions. Osteolytic and inflammatory changes may mimic osteomyelitis. Erosions and destructive changes in bone can resemble malignant tumors. CT and MRI can accurately delineate the borders of any lesions and extraosseous/soft tissue spread of HCs[10]. The definitive diagnosis is generally made during surgery and confirmed histologically. Histological examination of the cyst wall usually reveals an outer chitinous (or fibrous laminar) and an inner germinal layer, surrounded by either granulation tissue or a fibrous capsule[15–17]. In our cases, in whom bone involvement predominated, ultrasound was unsuitable and the diagnoses were made by MRI.

Treatment

There is a consensus that a combination of surgical and medical approaches is optimal; however, there is still disagreement about the details[13,19–28]. Surgery mainly comprises resection of infected tissue[5,22–26]. Despite the risk of recurrence and reinvasion, simple drainage or debridement are treatment options that are readily accepted by many patients[19,22–28]. Alternatively, sites of resection or infected spaces can be filled with cement, bone grafts or endoprostheses[5]. Bone cement filling reduces the recurrence rate according to Yildiz *et al.*[19] Polymerizing cement has a necrotizing impact associated with increased temperature that may kill daughter cysts. Scolicidal agents are routinely used during surgery and percutaneous treatment of visceral HCs to sterilize the cysts, 95% ethanol and 20% hypertonic saline being the most frequently used solutions. Higher concentrations and longer exposure times reportedly achieve greater and more rapid scolicidal effects[22]. Albendazole is generally preferred over mebendazole because of its superior pharmacokinetic properties and efficacy. Six months of oral albendazole 15 mg/kg/day is recommended along with surgical treatment[5,6,14,15]. Our cases all received albendazole for at least 6 months. Furthermore, radiotherapy has recently been proposed as a new treatment option for bone involvement by HCs[26]. The spillage of cyst contents during surgery may result in hypersensitivity reactions ranging from pruritus, urticaria, rash, edema, bronchospasm, and gastrointestinal symptoms to hypotension, and even fatal anaphylactic shock[5]. Among our cases, Cases 1 and 2 received endoprostheses. Case 2 underwent allograft reconstruction and Case 5 cementation. None of our cases had allergic reactions.

In conclusion, we have here presented five unusual cases and would like to highlight once again that HCs should be included in the differential diagnosis of cystic or tumoral lesions of the musculoskeletal system, particularly in endemic regions. Prompt diagnosis is of paramount importance in minimizing destruction and complications. Complete resection is the most effective treatment and should be combined with antihelminthic treatment.

References

1. Duman A, Yeti□gin A, Tosun A, Ekiz T. Primary subcutaneous hydatid cyst presenting with low back pain. Pm R, 2015, 7: 218–219.
2. Küçük□en S, Kaçıra BK, Bağcacı S, Albayrak □, Ya□ar O. Sacroiliac joint hydatidosis mimicking ankylosing spondylitis: a case report. Arch Rheumatol, 2014, 29: 138–142.
3. Sreeramulu PN, Krishnaprasad, Girish Gowda SL. Gluteal region musculoskeletal hydatid cyst: case report and review of literature. Indian J Surg, 2010, 72: 302–305.
4. Pedrosa I, Saíz A, Arrazola J, Ferreirós J, Pedrosa CS. Hydatid disease: radiologic and pathologic features and complications. Radiographics, 2000, 20: 795–817.
5. Neumayr A, Tamarozzi F, Goblirsch S, Blum J, Brunetti E. Spinal cystic echinococcosis–a systematic analysis and review of the literature: part 2. Treatment, follow-up and outcome. PLoS Negl Trop Dis, 2013, 7: e2458.
6. Xie Z, Chen L, Xie Q, *et al.* Surgery or radiotherapy for the treatment of bone hydatid disease: a retrospective case series. Int J Infect Dis, 2015, 33: 114–119.
7. Ozkok A, Gul E, Okumus G, *et al.* Disseminated alveolar echinococcosis mimicking a metastatic malignancy. Intern Med, 2008, 47: 1495–1497.
8. Pandya JS, Bhambare MR, Waghmare SB, Patel AR. Primary hydatid cyst of peritoneum presented as abdominal lump: a rare presentation. Clin Case Rep, 2015, 3: 331–332.
9. Zeybek A, Erdoğan A, Akdeniz S, Kenar G, Dertsiz L, Demircan A. Atypical giant hydatid cyst at the thoracic wall causing bone and soft tissue destruction: report of a case. Iran Red Crescent Med J, 2013, 15: 529–531.
10. Arkun R, Mete BD. Musculoskeletal hydatid disease. Semin Musculoskelet Radiol, 2011, 15: 527–540.
11. Erol B, Onay T, Çalışkan E, Okay E. Oncological approach with antihelminthic chemotherapy and wide resection in the treatment of musculoskeletal hydatidosis. A review of 10 cases with mean follow-up of 64 months. Acta Orthop Belg, 2015, 81: 530–537.
12. Pazarci O, Oztemur Z, Bulut O. Treatment of bifocal cyst hydatid involvement in right femur with Teicoplanin added bone cement and albendazole. Case Rep Orthop, 2015, 2015: 824824.
13. Lone YA, Mumtaz I, Mushtaq E, Sarmast AH, Kachroo MY. Recurrent primary hydatid disease of the tibia. West Indian Med J, 2013, 62: 866–868.
14. Grosso G, Gruttadauria S, Biondi A, Marventano S, Mistretta A. Worldwide epidemiology of liver hydatidosis including the Mediterranean area. World J Gastroenterol, 2012, 18: 1425–1437.
15. Mandal S, Mandal MD. Human cystic echinococcosis: epidemiologic, zoonotic, clinical, diagnostic and therapeutic aspects. Asian Pac J Trop Med, 2012, 5: 253–260.
16. Torgerson PR, Deplazes P. Echinococcosis: diagnosis and diagnostic interpretation in population studies. Trends Parasitol, 2009, 25: 164–170.
17. Lewall DB. Hydatid disease: biology, pathology, imaging and classification. Clin Radiol, 1998, 53: 863–874.

18. Stojkovic M, Rosenberger K, Kauczor HU, Junghanss T, Hosch W. Diagnosing and staging of cystic echinococcosis: how do CT and MRI perform in comparison to ultrasound? PLoS Negl Trop Dis, 2012, 6: e1880.
19. Yildiz Y, Bayrakci K, Altay M, Saglik Y. The use of polymethylmethacrylate in the management of hydatid disease of bone. J Bone Joint Surg Br, 2001, 83: 1005–1008.
20. Liang Q, Wen H, Yunus A, Tian Z, Jiang F, Song X. Treatment experiences of pelvic bone hydatidosis. Int J Infect Dis, 2014, 18: 57–61.
21. Khan MS, Hashmi PM, Khan D. Eradication of advanced pelvic hydatid bone disease after limb salvage surgery – 5-year follow-up: a case report. J Med Case Reports, 2015, 9: 21, doi:10.1186/1752-1947-9-21.
22. Caglar R, Yuzbasioglu MF, Bulbuloglu E, Gul M, Ezberci F, Kale IT. In vitro effectiveness of different chemical agents on scolices of hydatid cyst. J Invest Surg, 2008, 21: 71–75.
23. Ekinci Y, Duygulu F, Vatansever F, Gürbüz K. A giant hydatid cyst localized in pelvis and thigh. Eklem Hastalik Cerrahisi, 2014, 25: 121–124.
24. Babitha F, Priya PV, Poothiode U. Hydatid cyst of bone. Indian J Med Microbiol, 2015, 33: 442–444.
25. Bouzaïdi K, Daghfous A, Chelli Bouaziz M, Sahli H, Rezgui Marhoul L, Fethi LM. Rare cause of symptomatic lumbosciatica: pelvic bone hydatidosis. Presse Med, 2015, 44: 541–544.
26. Neumayr A. Radiotherapy of osseous echinococcosis: where is the evidence? Int J Infect Dis, 2015, 33: 75–78.
27. Kassa BG, Yeshi MM, Abraha AH, Gebremariam TT. Tibial hydatidosis: a case report. BMC Res Notes, 2014, 7: 631, doi:10.1186/1756-0500-7-631.
28. Abdelhakim K, Khalil A, Haroune B, Oubaid M, Mondher M. A case of sacral hydatid cyst. Int J Surg Case Rep, 2014, 5: 434–436.