[Downloaded free from http://www.njcponline.com on Friday, September 23, 2022, IP: 194.27.11.135]

Original Article

Investigation of the Effects of Marsupialization on Histomorphological and Immunohistochemical Markers of Odontogenic Keratocysts

E Barış, I Atak Seçen, Ş Karabulut[1], SE Gültekin

Department of Oral Pathology, Gazi University Faculty of Dentistry, Ankara, [1]Department of Medical Microbiology, Gulhane Institute of Health Sciences, University of Health Sciences, Ankara, Turkey

Received: 07-Feb-2022;
Revision: 23-Mar-2022;
Accepted: 19-Apr-2022;
Published: 22-Sep-2022

Abstract

Background: Despite its extensive bone resorption and high recurrence rate, marsupialization is the preferred option in the treatment of odontogenic keratocysts (OKCs). **Aim:** We aimed to assess the effect of marsupialization on histomorphological and biochemical markers of OKCs. **Materials and Methods:** The study is conducted on 48 paraffin blocks of 24 OKC cases between the years 2012 to 2018. The main clinical, radiographic, and histomorphometric measurements were recorded. Immunohistochemical staining with E-cadherin, Ki67, IL1α, TNFα, Slug, and Snail were performed and compared for pre-marsupialization and post-marsupialization values. **Results:** OKCs mostly located in the mandibular posterior region. The mean marsupialization period was 8.8 ± 6.5 (3-25) months. The mean radiographic size of OKC (57.1 ± 53.5 mm) was significantly reduced after marsupialization (22.6 ± 19.9 mm, $P = 0.002$). Histologically, significantly increased thickness of the OKC epithelium ($p = 0.002$) and collagen production ($p = 0.034$) was detected after marsupialization. The post-marsupialization group showed positive correlation of inflammation score to both TNFα (r: 0.69, $P < 0.001$) and IL-1α (r: 0.58, $P = 0.008$) expressions in connective tissue. Among immunohistochemical parameters, only Slug expression was significantly higher after marsupialization ($p = 0.019$). **Conclusion:** Our study suggests that increased Slug expression may enable the second surgery by increasing fibrosis in the cyst wall.

Keywords: *EMT, keratocyst, marsupialization, slug, snail*

Introduction

Odontogenic keratocysts (OKCs), the third most common odontogenic cyst, reach large dimensions, create extensive bone destruction, and have high recurrence rate. Except for sporadic cases, OKCs can be seen together with the nevoid basal cell carcinoma syndrome, in which the Patched (PTCH) gene mutation is found.[1] Studies have shown that OKC epithelium has intrinsic growth potential, genomic DNA mutations, and loss of heterozygosity in tumor suppressor genes.[2,3]

The treatment of OKC, which has a more aggressive biological behavior than other odontogenic cysts, may differ according to the clinical feature of the cyst. Treatment modalities may vary depending on the tendency of recurrence or the difficulty of surgical procedure. While conservative approaches include enucleation, marsupialization, and curettage, there are also aggressive treatment options such as local ostectomy, resection, and chemical curettage using Carnoy's solution.[4] According to WHO 2017 Blue Book, the recurrence rate following enucleation was 25%, with enucleation + Carnoy's solution 8%, and <2% in resected cases.[1] Marsupialization treatment is based on the principle of making the cystic cavity continuous with the oral cavity by removing a part of the intraosseous lesion via an incision. This leads

Access this article online

Quick Response Code:

Website: www.njcponline.com

DOI: 10.4103/njcp.njcp_103_22

Address for correspondence: Dr. E Barış, Department of Oral Pathology, Gazi University Faculty of Dentistry, Bişkek Cd. (8.Cd.) 1.Sk. No: 4 06490 Emek, Ankara, Turkey.
E-mail: emrebaris@gazi.edu.tr

This is an open access journal, and articles are distributed under the terms of the Creative Commons Attribution-NonCommercial-ShareAlike 4.0 License, which allows others to remix, tweak, and build upon the work non-commercially, as long as appropriate credit is given and the new creations are licensed under the identical terms.

For reprints contact: WKHLRPMedknow_reprints@wolterskluwer.com

How to cite this article: Barış E, Seçen IA, Karabulut Ş, Gültekin SE. Investigation of the effects of marsupialization on histomorphological and immunohistochemical markers of odontogenic keratocysts. Niger J Clin Pract 2022;25:1548-56.

[Downloaded free from http://www.njcponline.com on Friday, September 23, 2022, IP: 194.27.11.135]

to enlargement of the fibrous capsule and it becomes difficult to disperse after marsupialization, thus making total enucleation easier and reducing the recurrence rate of OKC.[5,6] The case series and meta-analyses reported conflicting results concerning the effective surgical approach. Some clinicians recommend total enucleation or resection for OKCs due to the possibility of in-situ pathological remnants in the cavity.[4] On the other hand, there are also approaches suggesting that removing the entire lesion with a second surgical procedure after reducing the size of the cyst with marsupialization is the most appropriate treatment.[7] Until now, there is no consensus in the literature regarding the optimal treatment method for OKC treatment.

Cytokines are proteins secreted by leukocytes and other cell types that regulate the immune response. Among these cytokines, TNFα is responsible for local bone resorption that occurs during the inflammatory process.[8] TNFα stimulates osteoclastic differentiation by inducing RANKL expression together with IL 1. IL1α stimulates epithelial cell proliferation either directly or indirectly by interacting with fibroblasts.[9] Immunohistochemical studies have shown that IL1α and TNFα expressed in OKC epithelium may play an important role in the development of OKC.[9,10] To the knowledge of the authors, there is no study in the English literature comparing the cytokine levels associated with marsupialization treatment of OKCs. Demonstration of proliferation markers in many tumors is the most commonly used method to explain the biological behavior and prognosis of the lesion. The proliferation ability of epithelial cells is directly responsible for the proliferation of OKC and the aggressive biological behavior of the cyst. Ki67 is a well-known proliferation marker that is widely used in the diagnosis of many pathological lesions.[11]

The epithelial-mesenchymal transition (EMT) is a complex process that begins with the loss of polarization in epithelial cells and followed by cytoskeletal re-organization, acquisition of mesenchymal phenotype, and finally increased migration.[12] Epithelial-mesenchymal interaction plays an important role in the growth regulation of odontogenic cysts and tumors.[13] Snail is one of the key regulators that contributes to EMT and increased Snail expression induces morphological changes by reducing E-cadherin expression.[14] Beside Snail, another transcription factor, Slug may play distinct roles in mediating local invasiveness in odontogenic tumors.[15] There is limited information in the literature regarding the effect of EMT on the biological behavior and prognosis of odontogenic cysts, especially in OKCs.

In this study, we aimed to assess the effect of marsupialization on histomorphological and immunohistochemical markers of OKCs.

Material and Methods

Specimens, clinical, histological, and radiological data

The study was conducted on 48 paraffin blocks of 24 OKC cases between the years 2012 and 2018 retrieved from the archive of the Department of Oral Pathology. Cases with nevoid-basal cell carcinoma syndrome were excluded from the study. The materials included both incisional biopsy (pre-marsupialization) and total enucleation (post-marsupialization) specimens of each patient. The study was approved by the Ethics Committee for Clinical Research. Main clinical characteristics including the age, gender, localization, radiographic size, recurrence, and follow-up period were recorded for OKC samples. Radiologically, 17 of 24 cases could be assessed on orthopantomography. Orthopantomographs were taken with a digital panoramic X-ray unit (Sirona Dental Systems, Bensheim, Germany) in JPEG format. OKC lesions were measured before marsupialization and total enucleation on two dimensions with Image J 1.48v software (National Institutes of Health, USA) program. All two-dimensional measurements were calculated in square centimeters.

Histological and histomorphometric analysis

Two oral pathologists (EB and SEG) previously reviewed all OKC slides, stained with hematoxylin-eosin (HE). Histopathological evaluation and measurements were made on the pre-marsupialized epithelium and connective tissue of the OKC specimens. Epithelial thickness was measured in five different areas at x200 magnification with the Leica QWinV3 (Leica-Westlar-Germany) image analysis program and the mean values were calculated. Connective tissue was assessed regarding collagenization texture. The scoring was made as follows: 0, loose/myxoid; 1, cellular/thin collagen fibers; and 2, acellular, thick-collagen fibers. The presence of satellite cyst was also noted as 0: absent, 1: present. Inflammation intensity was scored as 0: no inflammation, 1: mild, 2: moderate, and 3: intense.

Immunohistochemical analysis

4 μm thick sections of formalin-fixed paraffin OKC sections were taken from the same block as the histomorphometry evaluation. The sections were incubated with primary antibodies E-cadherin, Ki67, IL1β, TNFα, Slug, and Snail [Table 1]. BOND Polymer Refine Detection Kit (catalog #DS9800, Leica Biosystems Buffalo Grove-USA,) and BOND Polymer Refine Red Detection Kit (catalog #DS9390, Leica Biosystems,

[Downloaded free from http://www.njcponline.com on Friday, September 23, 2022, IP: 194.27.11.135]

Buffalo Grove-USA) were used as a protocol on Leica BOND-MAX fully automated IHC and ISH staining system (Leica microsystems, Buffalo Grove-USA). Both E-cadherin-Ki67 and IL1α–TNFα were double-stained while Slug and Snail were single-stained. For double staining, sections were baked and dewaxed after heat-induced EDTA antigen retrieval for 20 minutes and hydrogen peroxide for 10 minutes. The first primary antibody was incubated for 30 minutes, post-polymer for 8 minutes, polymer for 8 minutes, and DAB chromogen for 8 minutes. Subsequently, the second primary antibody was incubated for 30 minutes, post-polymer AP for 30 minutes, polymer AP for 20 minutes, red chromogen for 15 minutes, and hematoxylin for 10 minutes. Finally, sections were dehydrated and mounted to an aqueous medium.

For evaluation of immunostaining score, five representative high power fields at x200 magnification with light microscope were counted by two blind oral pathologists (EB & SEG). The intensity of staining for E-cadherin (membranous staining), IL-1α (nuclear staining), TNFα (cytoplasmic staining), Slug (nuclear staining), and Snail (nuclear staining) was measured semi-quantitatively by using the full H-score system for the whole epithelial layer and connective tissue. The scores were all noted for the staining intensity (0: no staining, 1: weak staining, 2: moderate staining and 3: strong staining) and the percentage of positive cells (0: 0-10% of cells stained, 1: 11-25% of cells stained, 2: 26-50% of cells stained, 3: 51-100% of cells stained). The full H score was calculated by the equation: H score = staining intensity score x percentage of positive cells score.[16] On the other hand, the proliferation index (Pi) score was calculated for Ki67 staining (nuclear staining). Total epithelial cell number and total Ki67 positive cell number were counted five representative high power fields at x200 magnification under the image analyzing program. Pi was calculated using the following equation: Pi = Ki67 positive cell number/total epithelial cell number.[17]

Statistical analysis

Statistical analyze was carried out by IBM SPSS Statistics 21.0 (IBM Corp., IBM SPSS Statistics for Windows, Version 21.0, Armonk, NY: IBM Corp). The comparison between the "pre-marsupialization" and the "post-marsupialization" values for each variable was performed by Wilcoxon Signed Ranks Test. Non-parametric correlation test (Spearman's correlation test) was used to analyze immunohistochemistry antibody expression status correlation with clinical, radiological, and histological parameters. An overall 5% Type-I error level was used to infer statistical significance.

Results

Clinical characteristics

Main clinical characteristics of the cases were summarized at Table 2. The mean age of the patients was 35.7 ± 16.7 years (range: 18-79 years). There were equal numbers of females and males. The majority (70.8%) of OKC cases were located in the mandibular posterior region. The mean marsupialization period was 8.8 ± 6.5 months (range: 3-25 months). The mean radiographic size of OKC (57.1 ± 53.5 mm) was significantly reduced after marsupialization (22.6 ± 19.9 mm, $P = 0.002$). The maximum follow-up period was 48 months, which was recorded for 14 cases (mean: 23.4 ± 13.1 months) and recurrence was observed in 3 of 24 cases.

Histological and histomorphometric findings

Histologically, the pre-marsupialization materials consisted of parakeratinized squamous epithelium, usually 6-8 cell rows and without rete formation. Although post-marsupialization materials showed similar features, an increase in epithelial thickness was observed [Figure 1a and b]. The thickness of the OKC epithelium significantly increased in the post-marsupialization group ($p = 0.002$). The connective tissue structure of OKCs generally consisted of cellular, thin collagen fibers (17 cases cellular/thin collagenized, 7 cases loose/myxoid) in the pre-marsupialization group. Seven of twenty-four cases, showed the transformation of the loose myxoid connective tissue into a cellular thin collagen structure after marsupialization. There was a significant collagen production in post-marsupialization specimens when compared to that in the pre-marsupialization group ($p = 0.034$). The numerical increase of the satellite cysts in the post-marsupialization specimens compared to that of the pre-marsupialization was not

Table 1: Summary of immunohistochemistry antibodies

Antibody	Host	Brand	Catalog number	Clone	Dilution	Control tissue
E-cadherin	Mouse monoclonal	Leica	NCL-L-E-Cad	36B5	1:25	Human tonsil
Ki-67	Rabbit monoclonal	Thermo Fisher Scientific	MA5-14520	SP6	1:200	Human tonsil
IL-1α	Rabbit polyclonal	Abcam	Ab9614	-	1μg/ml	Human liver tissue
TNF- α	Rabbit polyclonal	Abcam	ab182896	-	1:100	Human gastric carcinoma
Slug	Mouse monoclonal	Thermo Fisher Scientific	MA5-38634	4B6D5	1:200	Human cervical cancer tissue
Snail	Goat polyclonal	Thermo Fisher Scientific	PA5-18574	-	1:25	Human kidney tissue

[Downloaded free from http://www.njcponline.com on Friday, September 23, 2022, IP: 194.27.11.135]

Table 2: Clinical characteristics of the patients with treatment via marsupialization

Patient Number	Age	Sex	Localization	Marsupialization period	Follow-up period	Recurrence	2D Radiographic size (mean cm²)	
							pre-marsupialization	post-marsupialization
1	45	M	right mandible posterior	7 months	NA	N	7,44	0,99
2	38	M	right mandible posterior	5 months	2 years	N	108,24	60,48
3	19	F	mandible anterior	3 months	4 years	N	68,32	52,92
4	20	F	right mandible posterior	10 months	3 years	N	93,62	32,2
5	23	F	left mandible posterior	3 months	NA	N	48,45	NA
6	27	M	right mandible posterior	4 months	NA	N	67,13	33,25
7	19	F	right mandible posterior	7 months	3 years	Y	97,6	26,13
8	47	M	right mandible posterior	15 months	1 year	N	2,4	1,98
9	37	M	left mandible posterior	2 months	1 year	N	5,4	NA
10	19	F	right mandible posterior	5 months	NA	N	16,32	11,34
11	29	M	right mandible posterior	24 months	3 years	N	100,64	54
12	34	M	left mandible posterior	12 months	NA	N	1,82	NA
13	39	M	left mandible posterior	8 months	3 years	N	48,06	0,81
14	79	M	left maxilla posterior	2 months	NA	N	23,52	NA
15	24	F	mandible anterior	5 months	1 year	N	11,97	7,5
16	70	M	mandible anterior	18 months	2 years	N	42,84	10,15
17	17	F	mandible anterior	8 months	NA	N	NA	NA
18	35	F	left mandible posterior	10 months	NA	N	NA	NA
19	57	M	left mandible posterior	13 months	2 years	Y	148,23	27,28
20	39	F	mandible anterior	7 months	1 year	N	19,84	6,51
21	47	F	left mandible posterior	1 month	1 year	N	33,32	8,12
22	53	F	left mandible posterior	25 months	NA	N	NA	NA
23	21	M	right mandible posterior	14 months	3 months	Y	198,97	27,3
24	18	F	left mandible posterior	3 months	NA	N	NA	NA

(N: No, Y: Yes, F: Female, M: Male, NA: Not available)

Table 3: The data of histopathological and immunohistochemical parameters

Parameter	Pre-marsupialization mean/SD *n*: 24	Post marsupialization - mean/SD *n*: 24	*P* * * *P*<0.01 * *P*<0.05
Inflammation scoring grade	1.36±1.21	1.73±1.24	0,374
Epithelium size (μm)	83.46±45.05	167.39±110.08	0,002**
Satellite cyst presence	1.96±0.20	1.83±0.38	0,18
Connective tissue structure	1.32±0.48	1.05±0.21	0,034*
Ki-67 Pi	0.10±0.065	0.09±0.05	0,317
E-cadherin	3.0±0	3.0±0	1
TNF-α epithelium	1.45±0.10	1.55±0.69	0,666
TNF-α connective tissue	1.1±0.89	1.05±0.74	1
Interleukin-1α epithelium	3.0±0	2.85±0.37	0,083
Interleukin-1α connective tissue	2.15±0.91	1.95±1.07	0,497
Snail epithelium	1.74±1.098	2.05±1.03	0,13
Snail connective tissue	1.74±1.098	2.05±1.02	0,13
Slug epithelium	0.52±0.51	0.81±0.75	0,13
Slug connective tissue	0.64±0.66	1.14±0.89	0,019*

statistically significant (rho: -0.93; P = 0.67). While inflammation scores of 0 and 1 were dominant in the pre-marsupialization group, severe inflammation was observed in the post-marsupialization group, although with no difference [Table 3].

Immunohistochemical findings

Strong and diffuse membranous E-cadherin positivity was seen in the OKC epithelium of both pre- and post-marsupialization groups [Figure 1c and d]. There were no significant staining differences between the groups. Ki67 staining was observed especially in the suprabasal layer in the pre-marsupialization group whereas in the basal layer in the post-marsupialization group [Figure 1c and d].

IL-1α, TNFα, Slug, and Snail stainings were seen in both epithelium and connective tissue of pre- and post-marsupialization groups. Nuclear IL-1α and cytoplasmic TNFα expression were localized both in all layers of epithelium and in mononuclear inflammatory cells in connective tissue, irrespective of treatment modality. Nuclear Snail and Slug positivity were seen in all layers of epithelium except the basal layer [Figure 1e-j].

Descriptive statistical data of histopathological parameters were presented in Table 3. The slight reductions observed

[Downloaded free from http://www.njcponline.com on Friday, September 23, 2022, IP: 194.27.11.135]

in either Ki67 Pi or IL-1α H score in epithelial and connective tissue of the post-marsupialization group compared to that of the pre-marsupialization group were not statistically significant. Slug expression in the connective tissue was significantly higher in the post-marsupialization group (p = 0.019).

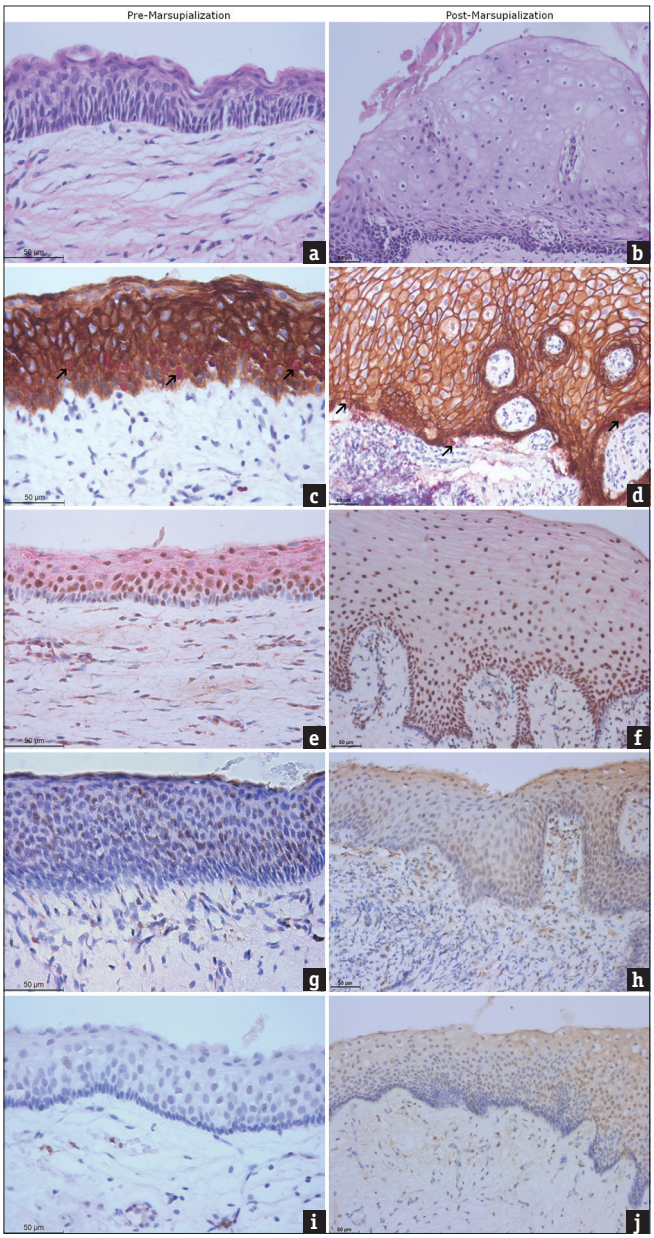

Figure 1: Histologic sections of groups before (Pre-MG) and after (Post-MG) marsupialization. While the OKC Pre-MG (Figure 1a, HE) had parakeratinized and corrugated epithelium; acanthosis was observed in the smooth-surfaced epithelium in the post-MG (Figure 1b, HE). E-cadherin immunoexpression was strong and membranous for both groups (Figures 1c and d, brown). While Ki67 (arrow) was localized in the suprabasal layer in the Pre-MG; it was limited to the basal layer in the Post-MG (Figures 1c and d, red). Expression of IL-1α and TNFα was observed in both epithelial and inflammatory cells in both groups. (Figs. 1e and f; IL-la: brown, TNFα: red). Nuclear Snail (Pictures 1g and h, brown) and Slug (Pictures 1i and j, brown) were positive in all layers of the epithelium except the basal layer. (Original magnification: a, c, e, g, i x 200, b, d, f, h, j x 400

Correlations

The associations between immunoexpression status and clinical parameters were shown in Figure 2. Two immunohistochemistry markers showed statistically significant correlation with clinical parameters in the pre-marsupialization group as follows: We found higher expression of TNFα in the connective tissue with decreased radiographic size (rho: -0.625; P = 0.007) [Figure 2a] and increased Ki67 Pi with long follow-up period (rho: 0.576; P = 0.031). We further determined that the expression of Slug increased in both epithelium (rho: 0.600; P = 0.002) and connective tissue (rho: 0.413; P = 0.034) as the period of marsupialization was prolonged in the post-marsupialization group [Figure 2b]. There was no significant correlation between other immunohistochemistry markers and clinical variables in the post-marsupialization group.

Correlation between immunohistochemical staining with histological parameters was shown in Figure 3. There was no significant correlation between immunohistochemical staining and histological parameters except TNFα in the pre-marsupialization group. Increased TNFα expression in the epithelium was associated with increased fibrosis of the cyst wall (rho: 0.440; P = 0.046), [Figure 3a]. In the post-marsupialization group, only TNFα and IL-1α showed significant correlations with histological parameters. Positive correlations were noted between inflammation score with TNFα (rho: 0.688; P < 0.001) and IL-1α (rho: 0.582; p: 0.008) expressions in connective tissue [Figure 3b]. The number of satellite cysts showed negative correlation with TNFα immunoreactivity in connective tissue (rho: -0.406; P = 0.049), [Figure 3c].

Correlation between histological and clinical variables was shown in Figure 4. Inflammation was the only histological parameter that had significant correlation to clinical data in both groups. In the pre-marsupialization group, increased inflammation scores were observed with reduced radiographic size (rho: -0.483; P = 0.042), [Figure 4a]. A positive correlation was found between epithelial thickness and inflammation score in the pre-marsupialization group (rho: 0.454; P = 0.038), [Figure 4b]. On the other hand, inflammation was found to be positively associated with follow-up period in the post-marsupialization group (rho: 0.781; P = 0.001), [Figure 4c].

Discussion

Marsupialization is one of the most preferred surgical approaches in the treatment of OKCs. However, the success criteria for the treatment are still unclear due to the presence of recurrences or the aggressive biological behavior of the lesion. In addition, there are

[Downloaded free from http://www.njcponline.com on Friday, September 23, 2022, IP: 194.27.11.135]

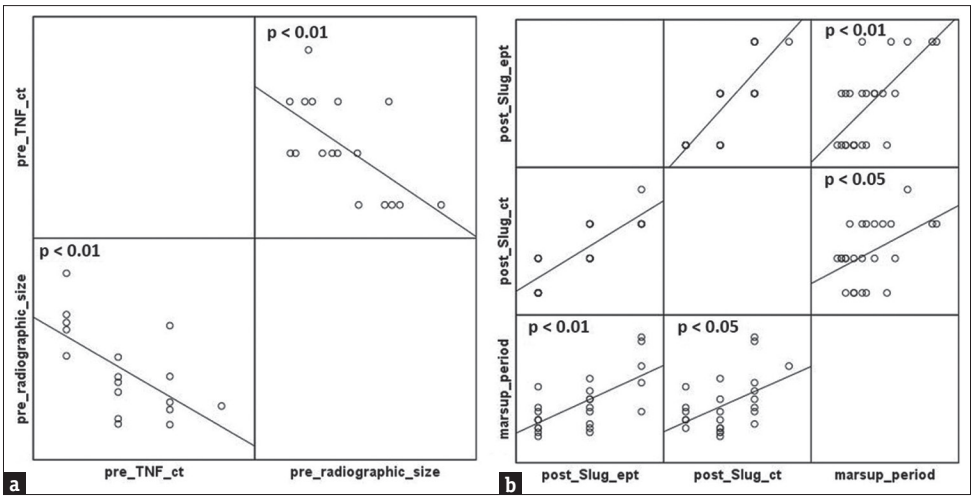

Figure 2: Spearman's correlations in scatterplot matrix between immunoexpression status with clinical data. (a) Negative correlation betweenTNFα in connective tissue and radiographic size in the pre MG (b) Positive correlation between marsupialization period and Slug expression in the post MG. (pre_TNF_ct: TNFα expression in the connective tissue inpre marsupialization group, pre_radiographic_size: radiographic size in pre marsupialization group, post_Slug_ept: Slug expression in the epithelium in the post marsupialization group, post_Slug_ct: Slug expression in the connective tissue in the post marsupialization group, marsup_period: marsupialization period)

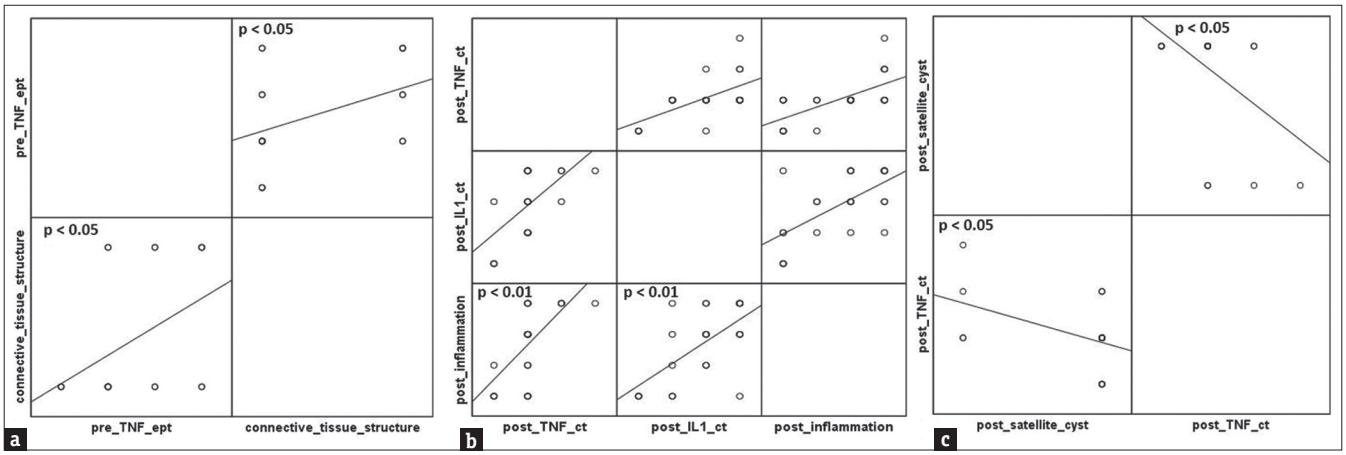

Figure 3: Spearman's correlations in scatterplot matrix between immunohistochemical staining and histological parameters. (a) Positive correlation between TNFα expression in the epithelium and cyst wall structure in the Pre-MG. (b) Inflammation score was showed positive correlations between both TNFα and IL-1α expressions in the connective tissue in the the Post-MG. (c) Negative correlation between TNFα expression in the connective tissue and the number of satellite cysts in the the Post-MG. *(pre_TNF_ept: TNFα expression in the epithelium in the pre-marsupialization group, connective_tissue_stucture: connective tissue structure of the cyst wall in the pre-marsupialization group, post_TNF_ct: TNFα expression in the connective tissue in the post-marsupialization group, post_IL_ct: IL-1α expression in the connective tissue in the post-marsupialization group, post_inflammation: Inflammation score in the connective tissue in the post-marsupialization group. post_satellite_cyst: The number of satellite cysts in the the post-marsupialization group)*

no histological criteria and/or biomarkers that predict the success of marsupialization. Therefore, the aim of our study was to assess the epithelial/connective tissue changes in OKCs through the use of histomorphological parameters and expression of proliferation, inflammatory and EMT markers before and after marsupialization treatment to determine whether the effect of treatment modality can reduce the aggressiveness of OKCs.

The most important clinical criteria that indicate the success of marsupialization is the reduction of the lesion on radiographic examination. The results of the present study indicated the statistically significant radiographic size reduction after marsupialization. Moreover, radiographic size showed negative correlation with histological inflammation score and TNFα expression in the connective tissue. Alterations in inflammation induced by marsupialization are well documented in the literature which is the main goal for success in the treatment.[18] Systematic reviews and meta-analyses revealed that decreased recurrences were detected in delayed enucleation treatment subsequent to marsupialization compared to enucleation alone.[19,20] This was also supported by our results where the mean

[Downloaded free from http://www.njcponline.com on Friday, September 23, 2022, IP: 194.27.11.135]

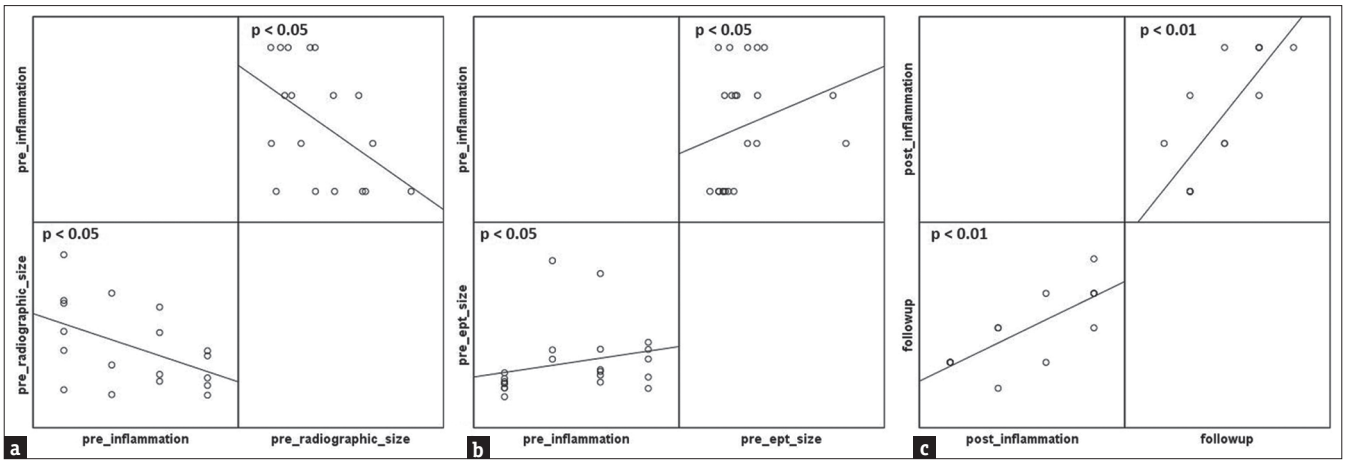

Figure 4: Spearman's correlations in scatterplot matrix between histological parameters with clinical data (a) Negative correlation between inflammation scores and radiographic size in the pre-MG. (b) Positive correlation between inflammation scores and the epithelium size in the pre-MG. **c:** Positive correlation between inflammation scores and follow-up period in the post-MG. *(pre_inflammation: Inflammation score in the connective tissue in the pre-marsupialization group., pre_radiographic_size: Radiographic size in pre-marsupialization group., pre_ept_size: The epithelial thickness of the pre-marsupialization group. Follow-up: follow-up period. post_inflammation: Inflammation score in the connective tissue in the post-marsupialization group.)*

marsupialization period was 8.8 months with a recurrence rate of 12.5%. In addition, the post-marsupialization group had a slightly higher inflammation score than the pre-marsupialization. The outcomes in our study may be explained by the influence of the long marsupialization period on the continuation of the chronic inflammatory process which may have stimulated fibrosis and generated a thick cyst wall.

Another striking finding of our study was improved collagenization of connective tissue and increased thickness of cyst epithelium after marsupialization. Studies have reported that hyperplastic epithelial changes and fibrosis were seen due to inflammation after marsupialization.[5,18,21] When tissue is wounded, inflammatory responses occur, leading to EMT activation.[22] Prolonged and increased EMT stimulates fibroblast proliferation, resulting in hyperplasia.[23] Limited studies reported EMT marker expression profiles in OKCs,[13,24] emphasizing higher Slug expression among the other markers. In our study, statistically significant Slug expression was found in the connective tissue of the post-marsupialization group. Zhong, Chen *et al*.[24] reported that MMP-9 was closely related with Slug expression in OKCs. MMP-9 was proposed as a crucial protein for fibrosis and remodeling via the cross-talk with pro-inflammatory cytokines.[25] Accordingly, we may hypothesize that Slug may have a crucial role for the epithelial and cyst wall alterations in marsupialization treatment through activating MMP-9 expression which is responsible for fibrosis.

Ki67 is a well-known proliferation marker that is widely used in OKCs in order to predict its biological behavior. Recent studies reported a decrease in Ki67 Pi in OKCs after marsupialization,[9,18] which was confirmed by the results of our study.

IL-1α expression in keratinocytes is increased by mechanical forces and bacterial endotoxins. It has been shown that intracystic fluid pressure in odontogenic cysts is reduced by marsupialization treatment, thus reducing the mechanical stress on the cyst epithelium.[8] Ninomiya *et al*.[9] reported that OKC's IL-1α expression in epithelial cells could be partially regulated by changes in intracystic pressure. Considering our findings, we may suggest that IL-1α may have decreased in the post-marsupialization group in accordance with the interpretation of the literature.

Expressions of adhesion molecules, including E-cadherin, were investigated to understand their role in tumorigenesis,[14] cell differentiation, and invasion[26,27] in odontogenic tumors. Although previous reports proposed that decreased E-cadherin expression might have a role in the invasive development of OKC[27]; there was no E-cadherin immunoexpression difference between pre- and post-marsupialization groups in our study specimens. Studies with similar results to our work reported that epithelial E-cadherin expression alone may not sufficient to explain the biological behavior of OKC.[13,26]

IL-1α and TNFα were found in odontogenic jaw cysts[8,28] and tumors[29]; therefore, these cytokines are thought to have important roles in the expansion of odontogenic lesions. While only epithelial TNFα was positively correlated with fibrosis of cyst wall (r: 0.44, P = 0.046) in the pre-marsupialization group, post-marsupialization group showed positive correlation

[Downloaded free from http://www.njcponline.com on Friday, September 23, 2022, IP: 194.27.11.135]

of inflammation score to both TNFα (rho: 0.69, $P < 0.001$) and IL-1α (rho: 0.58, $P = 0.008$) expressions in connective tissue. In addition, the inflammation score was increased after marsupialization.

Conclusion

In this study, an increase in collagenization and Slug expression in the cyst wall, together with the increase in epithelial thickness was observed after marsupialization. Those findings may indicate that marsupialization can effect cyst wall alteration through the EMT activity with special reference to higher slug expression. Therefore, we may speculate that increased Slug expression may enable the second surgery by increasing fibrosis in the cyst wall.

Ethical consideration

Ethical approval was granted according to the Gazi University Faculty of Dentistry, Clinical Research Committee (21071282-050.99-E.18602).

Financial support and sponsorship

This study was funded by the Gazi University Scientific Research Committee (03/2019-12).

Conflicts of interest

There are no conflicts of interest.

References

1. El-Naggar AK, Chan JK, Takata T, Grandis JR, Slootweg PJ. The fourth edition of the head and neck World Health Organization blue book: Editors' perspectives. Hum Pathol 2017;66:10-2.
2. Cha YH, Cho ES, Kang HE, Ko J, Nam W, Kim HJ, *et al.* Frequent oncogenic BRAF V600E mutation in odontogenic keratocyst. Oral Oncol 2017;74:62-7.
3. Gomes CC, Guimaraes LM, Diniz MG, Gomez RS. Molecular alterations in odontogenic keratocysts as potential therapeutic targets. J Oral Pathol Med 2017;46:877-82.
4. Morgan TA, Burton CC, Qian F. A retrospective review of treatment of the odontogenic keratocyst. J Oral Maxillofac Surg 2005;63:635-9.
5. Telles DC, Castro WH, Gomez RS, Souto GR, Mesquita RA. Morphometric evaluation of keratocystic odontogenic tumor before and after marsupialization. Braz Oral Res 2013;27:496-502.
6. Pogrel MA, Jordan RC. Marsupialization as a definitive treatment for the odontogenic keratocyst. J Oral Maxillofac Surg 2004;62:651-5; discussion 5-6.
7. Wushou A, Zhao YJ, Shao ZM. Marsupialization is the optimal treatment approach for keratocystic odontogenic tumour. J Craniomaxillofac Surg 2014;42:1540-4.
8. Muglali M, Komerik N, Bulut E, Yarim GF, Celebi N, Sumer M. Cytokine and chemokine levels in radicular and residual cyst fluids. J Oral Pathol Med 2008;37:185-9.
9. Ninomiya T, Kubota Y, Koji T, Shirasuna K. Marsupialization inhibits interleukin-1alpha expression and epithelial cell proliferation in odontogenic keratocysts. J Oral Pathol Med 2002;31:526-33.
10. Sa MC, de Matos FR, Conceicao TS, Leitao AC, Freitas RA. Immunoexpression of tumour necrosis factor-alpha, interleukin-1alpha and interleukin-10 on odontogenic cysts and tumours. Int Endod J 2017;50:437-45.
11. Abdel-Aziz A, Amin MM. EGFR, CD10 and proliferation marker Ki67 expression in ameloblastoma: Possible role in local recurrence. Diagn Pathol 2012;7:14.
12. Huber MA, Kraut N, Beug H. Molecular requirements for epithelial-mesenchymal transition during tumor progression. Curr Opin Cell Biol 2005;17:548-58.
13. Porto LP, dos Santos JN, Ramalho LM, Figueiredo AL, Carneiro Junior B, Gurgel CA, *et al.* E-cadherin regulators are differentially expressed in the epithelium and stroma of keratocystic odontogenic tumors. J Oral Pathol Med 2016;45:302-11.
14. Zhao D, Tang XF, Yang K, Liu JY, Ma XR. Over-expression of integrin-linked kinase correlates with aberrant expression of Snail, E-cadherin and N-cadherin in oral squamous cell carcinoma: Implications in tumor progression and metastasis. Clin Exp Metastasis 2012;29:957-69.
15. Siar CH, Ng KH. Differential expression of transcription factors Snail, Slug, SIP1, and Twist in ameloblastoma. J Oral Pathol Med 2014;43:45-52.
16. Karatas O, Balci Yuce H, Taskan MM, Gevrek F, Ucan Yarkac F, Keskin A, *et al.* The effect of vanillic acid on ligature-induced periodontal disease in Wistar rats. Arch Oral Biol 2019;103:1-7.
17. Gultekin SE, Senguven B, Klussmann JP, Dienes HP. P16(INK 4a) and Ki-67 expression in human papilloma virus-related head and neck mucosal lesions. Invest Clin 2015;56:47-59.
18. Awni S, Conn B. Decompression of keratocystic odontogenic tumors leading to increased fibrosis, but without any change in epithelial proliferation. Oral Surg Oral Med Oral Pathol Oral Radiol 2017;123:634-44.
19. Slusarenko da Silva Y, Stoelinga PJ, Naclerio-Homem MD. Recurrence of nonsyndromic odontogenic keratocyst after marsupialization and delayed enucleation vs. Enucleation alone: A systematic review and meta-analysis. Oral Maxillofac Surg 2019;23:1-11.
20. Tabrizi R, Hosseini Kordkheili MR, Jafarian M, Aghdashi F. Decompression or Marsupialization; Which conservative treatment is associated with low recurrence rate in keratocystic odontogenic tumors? A systematic review. J Dent (Shiraz) 2019;20:145-51.
21. Kuroyanagi N, Sakuma H, Miyabe S, Machida J, Kaetsu A, Yokoi M, *et al.* Prognostic factors for keratocystic odontogenic tumor (odontogenic keratocyst): Analysis of clinico-pathologic and immunohistochemical findings in cysts treated by enucleation. J Oral Pathol Med 2009;38:386-92.
22. Kalluri R, Weinberg RA. The basics of epithelial-mesenchymal transition. J Clin Invest 2009;119:1420-8.
23. Zhao YL, Zhu RT, Sun YL. Epithelial-mesenchymal transition in liver fibrosis. Biomed Rep 2016;4:269-74.
24. Zhong WQ, Chen G, Zhang W, Ren JG, Wu ZX, Zhao Y, *et al.* Epithelial-mesenchymal transition in keratocystic odontogenic tumor: Possible role in locally aggressive behavior. Biomed Res Int 2015;2015:168089.
25. Medeiros NI, Gomes JA, Correa-Oliveira R. Synergic and antagonistic relationship between MMP-2 and MMP-9 with fibrosis and inflammation in Chagas' cardiomyopathy. Parasite Immunol 2017;39. doi: 10.1111/pim. 12446.
26. Mello LA, Figueiredo AL, Ramos EA, Gurgel CA, Martins MD, de Figueiredo CR, *et al.* CD1a-positive Langerhans cells and their relationship with E-cadherin in ameloblastomas and keratocystic odontogenic tumors. J Oral Pathol Med 2013;42:454-61.

[Downloaded free from http://www.njcponline.com on Friday, September 23, 2022, IP: 194.27.11.135]

27. Hakim SG, Kosmehl H, Sieg P, Trenkle T, Jacobsen HC, Attila Benedek G, *et al.* Altered expression of cell-cell adhesion molecules beta-catenin/E-cadherin and related Wnt-signaling pathway in sporadic and syndromal keratocystic odontogenic tumors. Clin Oral Investig 2011;15:321-8.
28. Senguven B, Oygur T. Investigation of interleukin-1 alpha and interleukin-6 expression and interleukin-1 alpha gene polymorphism in keratocystic odontogenic tumors and ameloblastomas. Med Oral Patol Oral Cir Bucal 2011;16:e467-72.
29. Kolokythas A, Karas M, Sarna T, Flick W, Miloro M. Does cytokine profiling of aspirate from jaw cysts and tumors have a role in diagnosis? J Oral Maxillofac Surg 2012;70:1070-80.