Childs Nerv Syst
DOI 10.1007/s00381-017-3454-6

ORIGINAL PAPER

The efficacy of orbital ultrasonography and magnetic resonance imaging findings with direct measurement of intracranial pressure in distinguishing papilledema from pseudopapilledema

Zeynep Ozturk[1] · Tuba Atalay[2] · Ebru Arhan[1] · Kursad Aydin[1] · Ayse Serdaroglu[1] · Tugba Hirfanoglu[1] · Cengiz Havali[3] · Yilmaz Akbas[1] · Duygu Yalinbas[2]

Received: 13 March 2017 / Accepted: 11 May 2017
© Springer-Verlag Berlin Heidelberg 2017

Abstract
Introduction The goal of this study was to evaluate the utility of orbital ultrasonography and magnetic resonance imaging in the diagnosis of idiopathic intracranial hypertension (IIH).
Method We reviewed the medical records of patients referred to our department for suspected IIH.
Results Seven children were diagnosed with IIH. Nine children revealed pseudopapilledema by optic coherence tomography and/or orbital ultrasonography. When the axial sequences were reexamined, patients with papilledema had optic nerve sheath (ONS) enlargement (6.62 ± 0.70 mm); patients with pseudopapilledema had ONS diameter as 4.62 ± 0.64 mm. There was a significant correlation between the CSF opening pressure and ONS diameter ($p < 0.005$, $r = 0.661$). In the papilledema group, the presence of proposed subtle markers as increased tortuosity in the optic nerve was found in six patients. Five of seven patients had a target sign, intraocular protrusion of the optic nerve, and posterior globe flattening.
Discussion Ophthalmological review is important to avoid unnecessary procedures for detection of true papilledema. ONS diameter is a reliable neuroimaging marker as other subtle markers.

✉ Zeynep Ozturk
zeynep1220@yahoo.com

[1] Faculty of Medicine, Department of Pediatric Neurology, Gazi University, 06510 Ankara, Besevler, Turkey

[2] Faculty of Medicine, Department of Ophthalmology, Gazi University, Ankara, Turkey

[3] Department of Pediatric Neurology, Bursa Sevket Yilmaz Training and Research Hospital, Bursa, Turkey

Keywords Papilledema · Pseudopapilledema · Drusen · Idiopathic intracranial hypertension · Orbital ultrasonography

Introduction

Papilledema is a hallmark finding in patients with idiopathic intracranial hypertension (IIH) who frequently present with headache, vomiting, and visual symptoms due to elevated intracranial pressure (ICP) in the absence of a space-occupying lesion, venous sinus thrombosis, or central nervous system inflammation [1, 2]. Early diagnosis of papilledema enables timely evaluation and management. IIH is typically treated with pharmacotherapy, repeated lumbar punctures, and/or surgical intervention, in order to prevent visual disability, a risk associated with IIH [3, 4]. However, the diagnosis is not always straightforward. Pseudopapilledema is a benign elevation of the optic nerve head which can be congenital anomalies associated with disc elevation, hyperopic disc, or optic nerve head drusen. The discrimination between papilledema and pseudopapilledema can be a challenging yet critical distinction to make [1, 2]. Therefore, a substantial number of patients undergo various procedures for diagnostic purposes of IIH. These techniques include magnetic resonance imaging (MRI) of the brain and orbits, orbital ultrasonography (USG), and lumbar puncture to measure intracranial pressure [5–7]. Among these procedures, orbital USG is a reliable tool to assess buried drusen; that is rapid, noninvasive, cost effective, and poses minimal risk to patient safety [6].

MRI is the imaging of choice in IIH, in excluding other causes of ICP. MRI signs associated with papilledema include posterior flattening of the globe, protrusion of the optic nerve, widening of the optic nerve sheath, tortuosity of the optic nerve, and presence of optic nerve head hyperintensity on diffusion-weighted imaging [5, 8, 9]. Whether these findings

Published online: 22 May 2017

truly assist clinicians in establishing the diagnosis of IIH or generate a number of overdiagnoses remains unclear.

To the best of our knowledge, no studies thus far have examined the correlation between orbital USG and MRI signs and direct ICP measurements in the differentiation of pseudopapilledema from papilledema in pediatric patients. The goals of this study were to evaluate the correlation between the orbital USG and MRI signs and optic nerve sheath diameter (ONSD) measurement and direct ICP measurements, and to test the sensitivity and specificity of ONSD measurement by MRI.

Method

We performed a retrospective, blinded, observational study in pediatric patients who were referred to our tertiary pediatric neurology department for suspected IIH and/or papilledema. The institutional board of Gazi University approved the study.

Study setting and population

This study was conducted at a tertiary center University Hospital Pediatric Neurology Department. Patients were enrolled between March 2014 and January 2016.

Study protocol

We retrospectively reviewed the medical records of all patients referred to our tertiary pediatric neurology department for suspected IIH and/or papilledema between 2014 and 2016. Patients with either papilledema or pseudopapilledema whether having any of the following complaints of headache, vomiting associated with IIH, visual disturbances with brain MRI, and lumbar cerebrospinal fluid (CSF) opening pressure are included the study. Brain MRI was performed without anesthesia. All patients underwent lumbar punction before being examined in detail by an ophthalmologist in our tertiary center.

We noted the history and performed the systemic and neurological examination of the children. Data including demographic features, clinical symptoms, physical examination, brain imaging, CSF analysis, diagnosis, treatment, and clinical outcome after treatment were collected. Patients with papilledema or pseudopapilledema were reevaluated with MRI by one of the authors (KA) who is the most experienced and educated physician on MRI interpretation in the group. The reviewer was blinded to the results of all other clinical information. (1) Enlargement of the optic nerve sheath was measured at the point 5 mm posterior to the globe on an axial T2-weighted image and proposed a “target sign” was also performed on coronal T2 sequences. If the mean ONSD was greater than 5 mm in diameter, it was considered as abnormal and meaningful for IIH [10, 11]. (2) Posterior globe flattening was described as loss of normal curvature and straightening of the globe. (3) Intraorbital protrusion of the optic nerve was described as a concave appearance of the globe. (4) Increased tortuosity in the optic nerve was described as horizontal tortuosity of the optic nerve on an axial T2-weighted image.

Detailed ophthalmologic evaluation including best corrected visual acuity, slit lamp and fundus examination, B-mode USG, optic coherence tomography (OCT), color fundus photographs and fundus autofluorescence (FAF) imaging, and visual field assessment was also performed by the pediatric ophthalmology department.

The statistical analyses were performed using SPSS version 20.0 software (SPSS, Inc., Chicago, IL, USA). Correlation coefficient values were calculated for comparing the CSF opening pressure and the mean width of the optic nerve sheath.

Results

During the study period, 20 children aged 3–17 years were referred to us with a putative diagnosis of IIH and/or papilledema. Four patients were excluded due to insufficient data or inadequate follow-up. A total of 16 children were included in this study. Initial clinical symptoms presented before referral and opthalmological review and details of investigations performed are shown in Table 1.

The diagnoses were confirmed following tertiary opthalmological review. Seven children were finally diagnosed with IIH. An ophthalmologic examination in nine children with pseudopapilledema revealed asymmetric disc swelling in one, optic disc drusen in four, crowding of nerve fibers in the small disc in two, and nonspecific or normal appearances in two children by FAF, OCT, and/or B-scan USG.

In the seven children with confirmed diagnosis of IIH, complaints and symptoms included headaches, visual disturbances, and vomiting. Headache was continuous in the majority of children (4 out of 7.57%) and followed by diplopia (3 out of 7.42%) and vomiting-associated IIH (3 out of 7.42%). Two patients were asymptomatic and had relapsed after 1 year. The duration of symptoms before presentation was less than 1 month in all symptomatic children. Obesity was seen in only one patient. Among the children diagnosed with IIH, lumbar puncture to measure opening CSF pressures had a mean of 55 cm H_2O (range of 34–95 cm H_2O). CSF biochemistry and cytology were normal. Brain MRI revealed the absence of an intracranial mass lesion or ventricular dilatation, and magnetic resonance venography (MRV) was unremarkable in all patients. Laboratory investigations including biochemical profile, thyroid and parathyroid hormones, ANA, rheumatoid factor, and vitamin B12 and vitamin D levels were within normal limits.

Table 1 Demographics and clinical and neuroimaging findings of the patients

Age (years)/ sex		Presenting complaints	Pediatric ophthalmology in our tertiary center	ONDS R/L	CSF pressure (cmH_2O)	Final diagnosis	Management
1	7y/F	Headaches for 2 months	Crowding of nerve fibers	4.4/4	23	Pseudopapilledema	Reassured and discharged
2	8y/M	Headaches, diplopia, and vomiting for 1 month	Bilateral papilledema	5.9/6.4	95	IIH	Acetazolamide
3	3y/M	No symptoms, 1 year ago IIH	Bilateral papilledema	6.8/7.2	34	IIH	Acetazolamide
4	11y/M	No symptoms	Drusen	5.5/5.5	14	Pseudopapilledema	Reassured and discharged
5	17y/F	Headaches, tinnitus, vomiting for 1 month, obesity	Bilateral papilledema	5.9/6.6	56	IIH	Acetazolamide
6	13y/F	Facial numbness on the right side for 1 month	Crowding of nerve fibers	4.8/4.8	13	Pseudopapilledema	Reassured and discharged
7	11y/F	Diplopia for 1 week	Bilateral papilledema	6.8/6.3	55	IIH	Acetazolamide
8	13y/F	Headaches and facial numbness for 3 months	Asymmetric disc swelling	4.7/4.2	18	Pseudopapilledema	Reassured and discharged
9	12y/F	No symptoms	Drusen	5.5/5.8	13	Pseudopapilledema	Reassured and discharged
10	7y/F	Headaches, diplopia, and vomiting for 1 week	Bilateral papilledema	6.1/6	30	IIH	Acetazolamide
11	13y/M	No symptoms	Normal appearance	3.9/3.7	15	Normal	Reassured and discharged
12	12y/M	Nausea for few days	Drusen	4.9/4.8	12	Pseudopapilledema	Reassured and discharged
13	16y/F	No symptoms	Normal appearance	4.2/4.6	11	Normal	Reassured and discharged
14	17y/F	Left-sided headaches and photophobia for 2 years	Drusen	4.1/3.8	21	Pseudopapilledema, migraine	Reassured and discharged, flunarizine
15	16y/M	Headaches, diplopia, and vomiting for 10 days	Bilateral papilledema	6.5/6.2	50	IIH	Acetazolamide
16	7y/M	No symptoms, 1 year ago IIH	Bilateral papilledema	8.4/7.7	60	IIH	Acetazolamide

Abbreviations: *F* female, *M* male, *y* years, *CSF* cerebrospinal fluid, *ONSD* optic nerve sheath diameter, *L* left, *R* right, *IIH* idiopathic intracranial hypertension

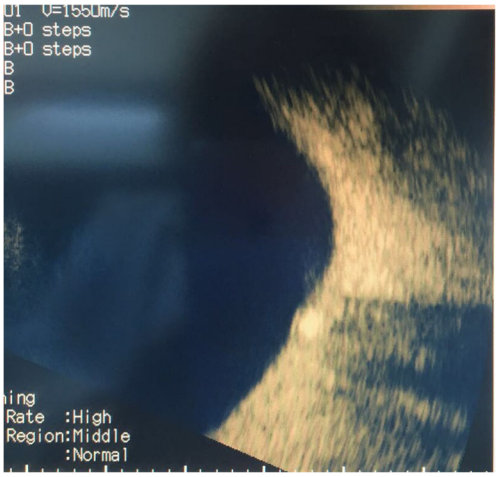

Fig. 1 Orbital ultrasonography confirmed diagnoses of pseudopapilledema due to optic disc drusen

Of the seven children, five children were cooperative for normal visual acuity testing by Snellen chart and field assessment. Visual acuity and field assessment were normal in five children. Acetazolamide was started in all children. Five patients were asymptomatic within 1 week of treatment. Papilledema resolved by 1 month in all patients. Drugs were tapered and stopped over 6 months and none of the patients had relapse at follow-up.

After further ophthalmologic review at our tertiary care center, four children received confirmed diagnoses of pseudopapilledema due to optic disc drusen (Fig. 1). Two children had no complaints nor any symptoms including headache or visual deficiencies. Of the two children, one patient had nonspecific vomiting and nausea, and the other patient had headache and photophobia for 2 years. She was diagnosed with migraine and treatment was initiated for migraine. All patients underwent lumbar puncture under the initial diagnosis of IIH, with a normal mean opening pressure and without an intracranial mass or ventricular dilatation in brain MRI. The other five patients with pseudopapilledema or normal examination findings had also normal opening CSF pressure and brain imaging. Their symptoms were the occasional headaches and resolved at follow-up.

When the axial sequences were reexamined, patients with papilledema had optic nerve sheath enlargement (6.62 ± 0.70 mm); patients with pseudopapilledema had ONSD as 4.62 ± 0.64 mm. There was a significant correlation between CSF opening pressure and ONSD ($p < 0.005$, $r = 0.661$). See Table 1 and Fig. 2.

In the papilledema group, the presence of proposed subtle markers—increased tortuosity in the optic nerve—was found to be the most (6/9 patients, 66.6%) common finding; five of seven patients had target sign on T2-coronal slices, intraocular protrusion of the optic nerve, and posterior globe flattening (Table 2, Figs. 2 and 3). In the pseudopapilledema group, there were no subtle markers.

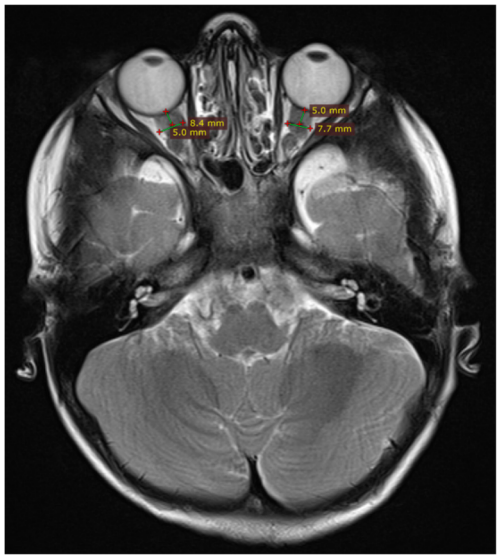

Fig. 2 Axial T2-weighted image demonstrates optic nerve sheath enlargement, posterior globe flattening, and intraocular protrusion of optic nerve

All patients showed significant improvement in objective neuroradiological testing at follow-up for 1 year. Follow-up MRI scans demonstrated normalization of optic nerve sheath enlargement (4.60 ± 0.67), posterior globe flattening, intraocular protrusion of the optic nerve, target sign, and tortuosity of the optic nerve in the five cases examined (Fig. 4).

Discussion

True papilledema is characterized by the swollen optic disc due to elevated intracranial pressure. Careful examination of the optic disc is essential to prevent unnecessary procedures. The part of the disc margin is disruption, the vessels are swollen, and the optic nerve is elevated with surrounding hemorrhage and exudates. In pseudopapilledema, the optic disc appears to be elevated but there is a lack of edema surrounding peripapillary vessels. Optic nerve drusen, which are deposits in the optic nerve caused by calcified hyaline bodies, can cause or mimic papilledema [12, 13]. Pseudopapilledema is also observed in many conditions including hyperopia, congenital structural anomalies, and optic neuritis. In our study, nine children with pseudopapilledema revealed asymmetric

Table 2 Magnetic resonance imaging findings in patients with papilledema

MRI findings	Papilledema ($n = 7$)
Tortuosity of the optic nerve	6
Target sign	5
Posterior globe flattening	5
Intraocular protrusion of the optic nerve	5

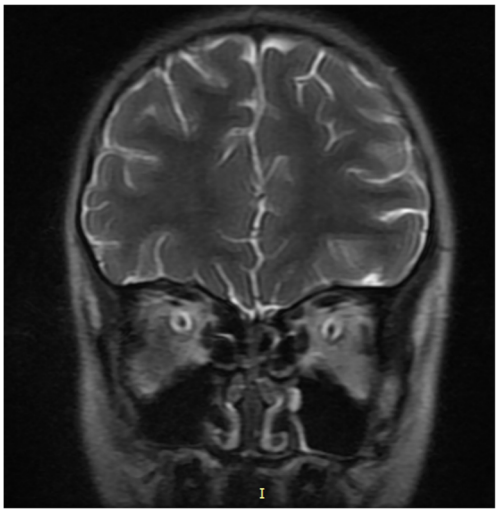

Fig. 3 Coronal T2-weighted image shows a target sign

disc swelling in one, optic disc drusen in four, crowding of nerve fibers in the small disc in two, and nonspecific or normal appearances in two children by OCT and/or orbital USG.

Various factors have been documented as predisposing to IIH, especially in adults. Unlike other reports, our study indicates that obesity does not seem to be a common association [14, 15]. In our study group, headache was the most common presenting symptom in patients, whether or not they had papilledema. However, headache features concerning for increased ICP were rarely seen in patients with pseudopapilledema. Patients with papilledema also presented with signs or symptoms of elevated intracranial pressure, such as nausea, vomiting, or diplopia. However, a substantial number of our patients were asymptomatic (28% of patients with papilledema). This is in line with previous studies and correlates with asymptomatic IIH which may be more common in children and suggests that the prevalence of IIH is underestimated [16]. Furthermore, two patients who had asymptomatic clinical presentation relapsed IIH. It is important to consider that recurrence rate is not as low as in previous studies [17, 18]. Therefore, long-term follow-up is recommended.

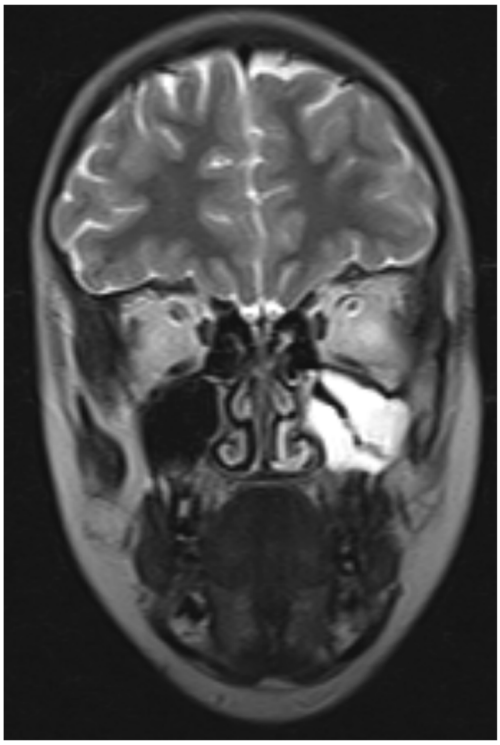

Fig. 4 Coronal T2-weighted image shows improvement of target sign

The diagnosis of IIH is conventionally comprised by normal CSF content with an increased CSF opening pressure [1]. However, this measurement can be affected by factors such as age, posture, diurnal fluctuation, and effect of anesthesia [19]. Previous studies have recently recommended the assessment of average CSF pressure over more than 20 min, "steady state" in children and adolescents which may help reduce negative/positive rate of CSF pressure measurement [20, 21]. However, in clinical practice, this can be impractical according to our study and similar studies [22]. Furthermore, diagnosing based on the lumbar CSF opening pressure is not always reliable. A recent study showed that lumbar puncture opening pressure overestimates the intracranial pressure when compared to the intracranial pressure monitoring [23].

Excluding other causes such as sinus venous thrombosis and cerebral mass with MRI or CT is prerequisite for the diagnosis of IIH [2]. However, there is a need for a more precisely defined method for assessment of IIH as ONSD on MRI. According to previous studies, the diameter of the optic nerve sheath behind the optic globe >5 mm is considered abnormal [8, 24, 25]. MRI may also show various signs of raised ICP, such as optic nerve tortuosity, optic nerve head protrusion, and flattening of the posterior aspect of the globe [8, 11, 26, 27]. However, this requires a detailed analysis of the neuroimaging signs by a very experienced examiner. Limited and controversial studies, mostly case reports, have been reported in children about the signs of IIH [2, 11, 27]. Several studies dealing with both adults and children showed that ONSD was significantly enlarged in IIH patients compared to that of healthy controls [10, 11, 28, 29]. Similarly, our findings showed that CSF opening pressure had a significant correlation with ONSD in patients who were diagnosed with true papilledema.

We observed tortuosity of the optic nerve, posterior globe flattening, and intraocular protrusion of the optic nerve are higher in patients with papilledema than in patients with pseudopapilledema in concordance with the literature [11]. We found the target sign, which was first described in the study by Hirfanoglu et al. in 71% of papilledema and 11% of pseudopapilledema patients [30]. The target sign can be used as an indicator marker in the diagnosis of IIH. Therefore, our results suggest that these MRI findings can

provide useful markers for diagnosis of IIH in pediatric patients. Furthermore, there was a trend toward good outcome in both neuroradiological and ophthalmological findings at last follow-up. These findings may be relevant to the clinical outcome as well as predictors of outcome in IIH. Clinical presentation of IIH can manifest without papilledema in children [31]. Clinical features often cannot reliably distinguish IIH without papilledema from other chronic daily headaches. We suggest that subtle markers on MRI can be useful tools for the estimation of IIH in these patients. Additionally, persistence or resolution of these markers on MRI at follow-up can be helpful for the management of IIH.

Although children presenting with papilledema require urgent intervention, not every child with symptomatic or asymptomatic clinical presentation needs to undergo an urgent invasive and high costly diagnostic work-up. Some examination findings may help to make a distinction between papilledema and pseudopapilledema. Fundus photography, autofluorescence, B-mode USG, and OCT remain sufficient information to distinguish disc drusen from true papilledema. A recent study showed that ocular ultrasound was the most sensitive method for diagnosing pseudopapilledema and was suggested to be used as a screening tool for determining papilledema [32]. Furthermore, the diameter of the optic nerve has been shown to correlate with the CSF pressure and could be measured by ocular ultrasound [33, 34]. Padayachy et al. examined ONSD by transorbital ultrasound prior to the invasive measurement of intracranial pressure in children. The study demonstrated a good relationship between transorbital ultrasound measurement of the ONSD and intracranial pressure [35]. Another study showed that ONSD was significantly higher in children with increased intracranial pressure than in patients without [36]. Liu et al. found that 34.6% of the children were misdiagnosed and had pseudopapilledema secondary to optic nerve drusen [37]. Also, Kovarik et al. detected pseudopapilledema or a normal variant in 76% of patients who were referred for suspected papilledema [38]. Similarly, in our study population, more than half of the children (56% of patients) referred for suspected papilledema were diagnosed with pseudopapilledema or a normal variant. Excessive unnecessary procedures including brain imaging and lumbar puncture were performed. The incidence of true papilledema among children referred for suspected papilledema based on fundus examination is very low. A detailed history and examination coupled with noninvasive testing, such as USG and OCT, will help distinguish pseudopapilledema from papilledema [38]. We emphasize the importance of a multidisciplinary approach and invasive procedures including lumbar punctures should be avoided before a detailed opthalmological examination.

The limitations of our study include a retrospective collection of data and a single-center design. Furthermore, we used a single instrument of a diagnostic ultrasound without measuring the ONSDs.

Conclusion

When determining the etiology of papilledema, it is important to keep in mind that many conditions can cause or mimic optic disc edema. Therefore, tertiary ophthalmological review is extremely important to avoid invasive and excessive unnecessary procedures for the detection of true papilledema. Although there is no ancillary test that can replace an accurate detailed history and neurological and opthalmological examinations to distinguish papilledema and pseudopapilledema, orbital USG serves as a valuable adjunct to clinical diagnosis. ONSD is a reliable neuroimaging marker as target sign, tortuosity of optic nerve, posterior globe flattening, and intraocular protrusion of the optic nerve to diagnose IIH in childhood.

Compliance with ethical standards The institutional board of Gazi University approved the study.

Conflict of interest On behalf of all authors, the corresponding author states that there is no conflict of interest.

References

1. Friedman DI, Liu GT, Digre KB (2013) Revised diagnostic criteria for the pseudotumor cerebri syndrome in adults and children. Neurology 13:1159–1165
2. Soler D, Cox T, Bullock P, Calver DM, Robinson RO (1998) Diagnosis and management of benign intracranial hypertension. Arch Dis Child 1:89–94
3. Savino PJ, Glaser JS (1977) Pseudopapilledema versus papilledema. Int Ophthalmol Clin 1:115–137
4. Hoyt WF, Pont ME (1962) Pseudopapilledema: anomalous elevation of optic disk. Pitfalls in diagnosis and management. JAMA 181:191–196
5. Agid R, Farb RI, Willinsky RA, Mikulis DJ, Tomlinson G (2006) Idiopathic intracranial hypertension: the validity of cross-sectional neuroimaging signs. Neuroradiology 8:521–527
6. Atta HR (1988) Imaging of the optic nerve with standardised echography. Eye 2:358–366
7. Biousse V, Bruce BB, Newman NJ (2012) Update on the pathophysiology and management of idiopathic intracranial hypertension. J Neurol Neurosurg Psychiatry 5:488–494
8. Passi N, Degnan AJ, Levy LM (2013) MR imaging of papilledema and visual pathways: effects of increased intracranial pressure and pathophysiologic mechanisms. AJNR Am J Neuroradiol 5:919–924
9. Brodsky MC, Vaphiades M (1998) Magnetic resonance imaging in pseudotumor cerebri. Ophthalmology 9:1686–1693
10. Maralani PJ, Hassanlou M, Torres C, Chakraborty S, Kingstone M, Patel V et al (2012) Accuracy of brain imaging in the diagnosis of idiopathic intracranial hypertension. Clin Radiol 7:656–663
11. Shofty B, Ben-Sira L, Constantini S, Freedman S, Kesler A (2012) Optic nerve sheath diameter on MR imaging: establishment of norms and comparison of pediatric patients with idiopathic intracranial hypertension with healthy controls. AJNR Am J Neuroradiol 2:366–369
12. Auw-Haedrich C, Staubach F, Witschel H (2002) Optic disk drusen. Surv of ophthalmol 6:515–532

13. Lam BL, Morais CG Jr, Pasol J (2008) Drusen of the optic disc. Curr Neurol Neurosci Rep 5:404–408
14. Balcer LJ, Liu GT, Forman S, Pun K, Volpe NJ, Galetta SL et al (1999) Idiopathic intracranial hypertension: relation of age and obesity in children. Neurology 4:870–872
15. Genizi J, Lahat E, Zelnik N, Mahajnah M, Ravid S, Shahar E (2007) Childhood-onset idiopathic intracranial hypertension: relation of sex and obesity. Pediatr Neurol 4:247–249
16. Bassan H, Berkner L, Stolovitch C, Kesler A (2008) Asymptomatic idiopathic intracranial hypertension in children. Acta Neurol Scand 4:251–255
17. Kesler A, Hadayer A, Goldhammer Y, Almog Y, Korczyn AD (2004) Idiopathic intracranial hypertension: risk of recurrences. Neurology 9:1737–1739
18. Johnston I, Paterson A (1974) Benign intracranial hypertension. I. Diagnosis and prognosis. Brain 2:289–300
19. Eidlitz-Markus T, Stiebel-Kalish H, Rubin Y, Shuper A (2005) CSF pressure measurement during anesthesia: an unreliable technique. Paediatr Anaesth 12:1078–1082
20. Schuhmann MU, Sood S, JP MA, Jaeger M, Ham SD, Czosnyka Z et al (2008) Value of overnight monitoring of intracranial pressure in hydrocephalic children. Pediatr Neurosurg 4:269–279
21. Czosnyka M, Pickard JD (2004) Monitoring and interpretation of intracranial pressure. J Neurol Neurosurg Psychiatry 6:813–821
22. Krishnakumar D, Pickard JD, Czosnyka Z, Allen L, Parker A (2014) Idiopathic intracranial hypertension in childhood: pitfalls in diagnosis. Dev Med Child Neurol 8:749–755
23. Cartwright C, Igbaseimokumo U (2015) Lumbar puncture opening pressure is not a reliable measure of intracranial pressure in children. J Child Neurol 2:170–173
24. Seitz J, Held P, Strotzer M, Muller M, Volk M, Lenhart M et al (2002) Magnetic resonance imaging in patients diagnosed with papilledema: a comparison of 6 different high-resolution T1- and T2(*)-weighted 3-dimensional and 2-dimensional sequences. J Neuroimaging 2:164–171
25. Watanabe A, Kinouchi H, Horikoshi T, Uchida M, Ishigame K (2008) Effect of intracranial pressure on the diameter of the optic nerve sheath. J Neurosurg 2:255–258
26. Degnan AJ, Levy LM (2011) Pseudotumor cerebri: brief review of clinical syndrome and imaging findings. AJNR Am J Neuroradiol 11:1986–1993
27. Mandelstam S, Moon A (2004) MRI of optic disc edema in childhood idiopathic intracranial hypertension. Pediatr Radiol 4:362
28. Lim MJ, Pushparajah K, Jan W, Calver D, Lin JP (2010) Magnetic resonance imaging changes in idiopathic intracranial hypertension in children. J Child Neurol 3:294–299
29. Hoffmann J, Huppertz HJ, Schmidt C, Kunte H, Harms L, Klingebiel R et al (2013) Morphometric and volumetric MRI changes in idiopathic intracranial hypertension. Cephalalgia 13: 1075–1084
30. Hirfanoglu T, Aydin K, Serdaroglu A, Havali C (2015) Novel magnetic resonance imaging findings in children with intracranial hypertension. Pediatr Neurol 2:151–156
31. Aylward SC, Aronowitz C, Roach ES (2016) Intracranial hypertension without papilledema in children. J Child Neurol 2:177–183
32. Neudorfer M, Ben-Haim MS, Leibovitch I, Kesler A (2013) The efficacy of optic nerve ultrasonography for differentiating papilloedema from pseudopapilloedema in eyes with swollen optic discs. Acta Ophthalmol 4:376–380
33. Newman WD, Hollman AS, Dutton GN, Carachi R (2002) Measurement of optic nerve sheath diameter by ultrasound: a means of detecting acute raised intracranial pressure in hydrocephalus. Br J Ophthalmol 10:1109–1113
34. Mehrpour M, Shams-Hosseini NS, Rezaali S (2014) Effect of scuba-diving on optic nerve and sheath diameters. Med J Islam Repub Iran 28:89
35. Padayachy LC, Padayachy V, Galal U, Gray R, Fieggen AG (2016) The relationship between transorbital ultrasound measurement of the optic nerve sheath diameter (ONSD) and invasively measured ICP in children: part I: repeatability, observer variability and general analysis. Childs Nerv Syst 10:1769–1778
36. Steinborn M, Friedmann M, Makowski C, Hahn H, Hapfelmeier A, Juenger H (2016) High resolution transbulbar sonography in children with suspicion of increased intracranial pressure. Childs Nerv Syst 4:655–660
37. Liu B, Murphy RK, Mercer D, Tychsen L, Smyth MD (2014) Pseudopapilledema and association with idiopathic intracranial hypertension. Childs Nerv Syst 7:1197–1200
38. Kovarik JJ, Doshi PN, Collinge JE, Plager DA (2015) Outcome of pediatric patients referred for papilledema. J AAPOS 4:344–348