Rom J Leg Med [24] 277-280 [2016]
DOI: 10.4323/rjlm.2016.277
© 2016 Romanian Society of Legal Medicine

The first fatal dengue virus infection case in Turkey: Autopsy findings

Bülent Değirmenci[1], Taner Akar[2,], Sait Özsoy[3], Mehtap Özdemir[1], Bora Özdemir[1], Birol Demirel[2]*

Abstract: Dengue is the fastest spreading arboviral infection in the world. It is responsible for about 50 to 200 million infections annually. Turkey is accepted in the World Health Organization European region and dengue is now endemic in all World Health Organization regions except for the European region, but people can travel anywhere in the world and they can catch a disease easily. Approximately 2.5 billion people live in dengue endemic countries; therefore, it may be endemic in Europe as well in the near future. It might be seen with increasing frequency in forensic mortuaries soon. In such a situation, the autopsy staff have to keep dengue virus infections in mind to protect themselves from contamination and to detect the cause of death.
A case of a 65-year old Thailand citizen male who died in Turkey is presented. He had skin rashes all over the body. His internal examination revealed, 1900 ml, 1700 ml and 80 ml sero-hemorrhagic fluid in the right chest, left chest and pericardial cavities respectively. The sectional cuts of the lungs showed hemorrhagic fluid leakage. Ecchymosis due to intubation was found in the upper tracheal region. Mesocolon transversum showed hemorrhage as well. Blood test results showed Dengue Virus Immunoglobulin G (IFA) and Immunoglobulin M (IFA) positive, Japanese encephalitis virus Immunoglobulin M (IFA) negative and Immunoglobulin G (IFA) positive.
Key Words: Dengue virus, autopsy, Turkey.

The Flaviviridae family is divided into four genera; Flavivirus, Pestivirus, Pegivirus, and Hepacivirus [1]. The Flavivirus genus can be further divided into four categories; the mosquito-borne, tick-borne, no-known vector and insect-specific viruses [1, 2]. Dengue, Zika, West Nile, Yellow Fever, Japanese Encephalitis, Saint Louis Encephalitis and Murray Walley Encephalitis viruses all belong to the mosquito borne Flavivirus genus [1-4].

Self-limitted classic dengue fever, dengue haemorrhagic fever and dengue schock syndrome are caused by the dengue virus which is usually transmitted by the female mosquito Aedes aegypti and sometimes by Aedes albopictus [4-13]. Dengue diseases are the second most prevalent mosquito-borne infections after malaria [14]. Symptoms of severe dengue haemorrhagic fever and dengue schock syndrome are cold and sweaty skin, gastrointestinal bleeding and spontaneous bleeding from gums and nose. Dengue shock syndrome is characterized by increased vascular permeability [6]. The fluid in the blood vessels leaks to the skin, the spaces around the lungs and the abdomen. The fluid leaks and bleedings give rise to hypotension and shock with a mortality rate of 5% [5, 15]. Byard suggests that the untreated dengue shock syndrome has more than 20% mortality rate [4].

In Turkey, the dengue virus infection was seen only in one non-fatal case who had a travel history to risky regions. Our case was the first and only fatal dengue virus infection in Turkey. Therefore, the autopsy staff have to keep this rare case in mind to protect themselves from

1) Council of Forensic Medicine, Ankara, Turkey
2) Gazi University School of Medicine, Department of Forensic Medicine, Ankara, Turkey
** Corresponding author: Gazi University School of Medicine Department of Forensic Medicine, Mevlana Boulevard, 06510, Besevler, Ankara, Turkey, Tel: 00905065981816, Fax: 00903122230528, E-mail: tanerakar@yahoo.com*
3) Gülhane Military Medical Academy, Department of Forensic Medicine, Ankara, Turkey

contamination and in suspected cases they have to demand dengue virus specific antibodies in either serum or plasma during autopsies for detection of causes of death.

CASE

In April 2014, a 65-year old Thailand citizen male had a diabetes mellitus (DM) came to Turkey for a five-day trip. On the fourth day of the trip, he told the tour guide that he felt inappetence, extreme tiredness and dyspnea for a few days. He had a fever of 39 °C. On the fifth day, the tour ended and the group reached the airport. Then, his condition deteriorated and the tour guide called an ambulance. Physicians determined the bradycardia, bradypnea and high blood glucose level (495 mg/dL). He was intubated and afterwards, he was brought to hospital with cardio-pulmonary arrest. He died after a 45 minute-resuscitation attempt.

An external examination revealed skin rashes all over the body (Fig. 1) and injection marks on the bilateral antecubital fossa. An internal examination revealed, 1900 mL, 1700 mL and 80 mL sero-haemorrhagic fluid in the right chest, left chest and pericardial cavities respectively (Fig. 2). The left lung was measured 327 g and the right lung was measured 451 g. Both lung surfaces showed haemorrhagic spots. The sectional cuts of the lungs showed haemorrhagic fluid leakage and microscopic examinations of the lungs revealed micro haemorrhages (Fig. 3). Ecchymosis (4x1 cm) due to intubation was found in the upper tracheal region. Mesocolon transversum showed haemorrhage (8x6 cm) as well. Toxicological test results of blood showed 375 ng/mL gliclazide and 466 ng/mL metformin and urine showed gliclazide, metformin and tolbutamide. We suspected of a dengue virus infection during the autopsy and we sent the deceased's blood samples to the Ministry of Health Viral Infections Unit for the purpose of dengue virus serologic investigation. The deceased's blood test results showed Dengue Virus IgG (IFA) and IgM (IFA) positive, Japanese encephalitis virus IgM (IFA) negative and IgG (IFA) positive.

On the basis of autopsy findings and serologic test results, we declared the cause of death as "Dengue Haemorrhagic Fever".

DISCUSSION

Dengue is the fastest spreading arboviral infection in the World [7, 9, 16, 17]. It is responsible for about 50 to 200 million infections annually [7, 18]. Its incidence has increased 30-fold during the past 50 years [4, 7, 9]. Turkey is accepted in the WHO European region and dengue is now endemic in all WHO regions except for the European region [7]. Approximately 2.5 billion people live in dengue endemic countries [7]; therefore, it may be endemic in Europe as well in the near future. Dengue is determined in 16% of returning travellers with febrile illness [4].

Although Ergünay's and Tezcan's seroepidemiological studies showed the presence of dengue virus in Turkey [19, 20], the first and the last non-fatal dengue fever cases were reported in 2013. A forty-year old Swiss citizen male moved to India from Dubai two weeks ago. One week later, he was admitted to a hospital in India with high fever. The test results showed NS1 antigen positive [21]. The dengue virus genome encodes 3 structural (capsid, membrane and envelope) and 7 non-



Figure 1. Skin rashes all over the body.

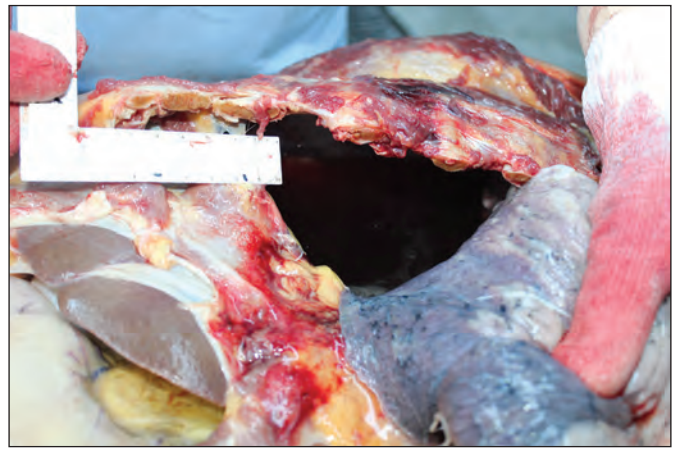

Figure 2. Sero-haemorrhagic fluid in the right chest cavity (1900 mL).

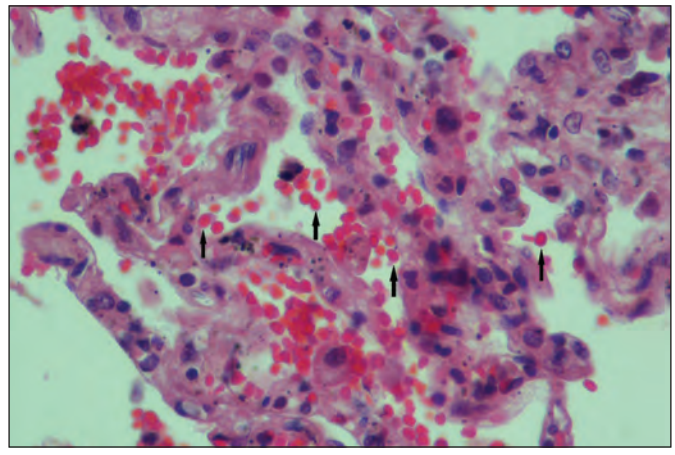

Figure 3. Microphotograph showing pulmonary haemorrhage (400X, H&E).

structural proteins (NS1, NS2A, NS2B, NS3, NS4A, NS4B, NS5) [4]. These nonstructural proteins play a role in viral replication and assembly [21]. So he was diagnosed with dengue fever. In Turkey, he went to hospital for control. He revealed only skin rashes on his lower extremities and no fever. The serum sample showed the Dengue Virus IgG and IgM positive. Then, he was discharged from hospital [21]. After this non-fatal case, our case was the first fatal dengue virus infection in Turkey.

Dengue patients with co-morbidities are prone to fatal complications [14, 22-25]. Saqib *et al.* and Leo *et al.* reported that 58% and 75% of dengue patients were suffering from co-morbidities respectively [14,22]. Our case also suffered from diabetes mellitus. In Leo *et al.*'s study, diabetes mellitus was the third most seen co-morbidity after hypertension and cardiovascular diseases in dengue patients [22]. Figueiredo *et al.* concluded that dengue patients with allergies or diabetes mellitus have 2.5 times more risk of developing dengue haemorrhagic fever [23]. Diabetes mellitus, sickle cell anemia, asthma and peptic ulcer are associated with severe Dengue [4].

An organ failure, including acute respiratory failure requiring mechanical ventilation or hematologic failure (active bleeding requiring blood transfusion) is among the major fatal complications in dengue patients [26]. In our case, we found the possible evidence of these two complications such as massive sero-haemorrhagic fluid in both chest cavities and pericardial cavity (total 3680 mL), haemorrhagic fluid leakage from both lung sections, hemorrhage at the mesocolon transversum and ecchymosis due to intubation in the upper trachea.

Dengue infection's clinical symptoms are analogous with many other acute febrile illnesses [27]. For example, Chikungunya and dengue skin lesions are similar and difficult to differentiate. Rash is a common lesion in both diseases as seen in our case [28]. Therefore, diagnosis relies on serological tests based on the detection of dengue specific IgM antibodies during the acute phase of infection [27]. However, antibodies of other flaviviruses, especially the Japanese encephalitis virus, may cross-react and cause a false-positive result [27]. The blood test results of our case showed the Dengue Virus IgM (IFA) and IgG (IFA) positive, the Japanese encephalitis virus IgM (IFA) negative and IgG (IFA) positive.

In Turkey, the dengue virus and all other viral serological tests are not routine at autopsies today. In forensic practice, forensic examiners rarely know the deceased's ante mortem health condition, especially infections which have a transmission risk to autopsy staff during autopsies as the dengue virus. Therefore, autopsy staff have to keep these rare cases in mind to protect themselves from contamination and to detect the cause of death. All autopsies must be performed in a Biosafety Level-2 (BSL-2) precautions augmented by Biosafety Level-3 (BSL-3) facility ventilation and respiratory precautions [29]. According to Centers for Disease Control and Prevention (CDC) Morbidity and Mortality Weekly Report published on June 11, 2004, dengue viruses are accepted in the probable biological terrorism agents [30]. Many infections such as tuberculosis, blastomycosis, coccidioidomycosis, acquired immuno-deficiency syndrome, hepatitis B and C (or non-A, non-B), rabies, tularemia, diphtheria, erysipeloid fever, and some of the viral haemorrhagic fevers are transmitted through direct inoculation during autopsies [3, 29]. According to the "Biosafety in Microbiological and Biomedical Laboratories" developed by the American Committee on Arthropod-Borne Viruses (ACAV), the Subcommittee on Arbovirus Laboratory Safety (SALS), the Center for Disease Control and Prevention (CDC) and the National Institute of Health, all dengue viruses are in biohazard group 2. Thus, the autopsy of a deceased dying of the dengue virus must be performed in a BSL-2 laboratory conditions [31, 32]. Despite all the international biosafety rules, the forensic examiner was diagnosed with autopsy-transmitted CCHF in Turkey. She cut her hand by scalpel during the autopsy of the deceased whose cause of death was unknown. 10-15 days after the incident, she was admitted to the hospital with complaint of fatigue and fever of 39-40 °C. Then she was diagnosed with Crimean-Congo haemorrhagic fever (CCHF). After treatment, she was discharged and she completely recovered. The examination on the deceased blood revealed CCHF RNA PCR (+), IgM ELISA (-) and the cause of his death was identified as the CCHF infection (3).

CONCLUSION

The dengue virus seems to be non-endemic in the WHO European region, but people can travel anywhere in the world and they can catch a disease easily. Nowadays the refugee issue is one of the most important health problem in Middle East and Europe. In 2007, mosquito Aedes Albopictus was reported from Syria for the first time. Today total 4.840.659 Syrian refugees registered by United Nations Refugee Agency and the Government of Turkey [33]. Turkey acts as the bridge between Europe and Asia where the Dengue is endemic. There is a real risk of the emergence of dengue fever in Syria, Turkey and Europe under the present conditions [34].

It is hard to diagnose the actual cause of disease as the dengue virus based on its symptoms. When the patient gives the travel history to endemic regions, physicians have to suspect of the virus. Otherwise, those patients may die before a diagnosis can be made. It might be seen with increasing frequency in forensic mortuaries in the near future. In such a situation, the autopsy staff have to keep dengue virus infections in mind to protect themselves from contamination and to detect the cause of death.

Conflict of interest. The authors declare that they have no conflict of interest concerning this article.

References

1. Salas-Benito JS, De Nova-Ocampo M. Viral interference and persistence in mosquito-borne Flaviviruses. J Immunol Res. 2015; 2015:873404.
2. Villordo SM, Carballeda JM, Filomatori CV, Gamarnik AV. RNA Structure Duplications and Flavivirus Host Adaptation. Trends Microbiol. 2016;24:270-283.
3. Ozsoy S, Gokmen A, Ozdemir M, Akduman B, Korkusuz I, Javan GT. Medical examiners and Crimean-Congo Hemorrhagic Fever contamination risk. J Forensic Legal Med. 2015;36:32-36.
4. Byard RW. Lethal Dengue Virus Infection: A Forensic Overview. Am J Forensic Med Pathol. 2016;37:74-78.
5. AAye KS, Charngkaew K, Win N, Wai KZ, Moe K, Punyadee N, Thiemmeca S, Suttitheptumrong A, Sukpanichnant S, Prida M, Halstead SB. Pathologic highlights of dengue hemorrhagic fever in 13 autopsy cases from Myanmar. Hum Pathol. 2014;45:1221-1233.
6. Rathi KR, Arora MM, Sahai K, Tripathi S, Singh SP, Raman DK, Anand KB. Autopsy findings in fatal dengue haemorrhagic fever-06 cases. Med J Armed Forces India. 2013;69:254-259.
7. WHO. Dengue: Guidelines for Diagnosis, Treatment, Prevention and Control. New Geneva: WHO; 2009.
8. Araújo SA, Moreira DR, Veloso JM, Silva JO, Barros VL, Nobre V. Fatal staphylococcal infection following classic dengue fever. Am J Trop Med Hyg. 2010;83:679-682.
9. Wong JG, Thein TL, Leo YS, Pang J, Lye DC. Identifying adult dengue patients at low risk for clinically significant bleeding. PLoS One.2016;11:e0148579.
10. Forshey BM, Reiner RC, Olkowski S, Morrison AC, Espinoza A, Long KC, Vilcarromero S, Casanova W, Wearing HJ, Halsey ES, Kochel TJ, Scott TW, Stoddard ST. Incomplete protection against dengue virus type 2 re-infection in Peru. PLoS Negl Trop Dis. 2016;10: e0004398.
11. Alera MT, Srikiatkhachorn A, Velasco JM, Tac-An IA, Lago CB, Clapham HE, Fernandez S, Levy JW, Thaisomboonsuk B, Klungthong C, Macareo LR, Nisalak A, Hermann L, Villa D, Yoon IK. Incidence of dengue virus infection in adults and children in a prospective longitudinal cohort in the Philippines. PLoS Negl Trop Dis. 2016;10:e0004337.
12. Sarti E, L'Azou M, Mercado M, Kuri P, Siqueira JB Jr, Solis E, Noriega F, Ochiai RL. A comparative study on active and passive epidemiological surveillance for dengue in five countries of Latin America. Int J Infect Dis. 2016;44:44-49.
13. Shrestha R, Pant ND, Gc G, Thapa S, Neupane B, Shah Y, Gautam I, Pandey BD. Serological and entomological study of dengue in Dang and Chitwan districs of Nepal. PLoS One. 2016;11:e0147953.
14. Saqib MA, Rafique I, Bashir S, Salam AA. A retrospective analysis of dengue fever case management and frequency off co-morbidities associated with deaths. BMC Res Notes. 2014;7:205.
15. Neri M, Othman SM, Cantatore S, De Carlo D, Pomara C, Riezzo I, Turillazzi E, Fineschi V. Sudden infant death in an 8-month-old baby with dengue virus infection: searching for virus in postmortem tissues by immunohistochemistry and western blotting. Pediatr Infect Dis J. 2012;31:878-880.
16. Cheng Q, Jing Q, Spear RC, Marshall JM, Yang Z, Gong P. Climate and the timing of imported cases as determinants of the dengue outbreak in Guangzhou, 2014: Evidence from a mathematical model. PLoS Negl Trop Dis. 2016;10:e0004417.
17. Kim Lien PT, Briant L, Tang TB, Trang BM, Gavotte L, Cornillot E, Duoc VT, Duong TN, Frutos R, Nga PT. Surveillance of dengue and chikungunya infection in Dong Thap, Vietnam: A 13-month study. Asian Pac J Trop Med. 2016;9:39-43.
18. Khan J, Khan I, Amin I. A comprehensive entomological, serological and molecular study of 2013 dengue outbreak of Swat, KhyberPaktunkhwa, Pakistan. PLoS One. 2016;11:e0147416.
19. Ergünay K, Saygan MB, Aydoğan S, Litzba N, Niedrig M, Pınar A, Us D. Investigation of dengue virus and yellow fever virus seropositivities in blood donors from Central/Northern Anatolia, Turkey. Mikrobiyol Bul. 2010;44:415-424. (Article in Turkish)
20. Tezcan S, Kızıldamar S, Ulger M, Aslan G, Tiftik N, Ozkul A, Emekdaş G, Niedrig M, Ergünay K. Flavivirus seroepidemiology in blood donors in Mersin province, Turkey. Mikrobiyol Bul. 2014;48:606-617. (Article in Turkish)
21. Uyar Y, Aktaş E, Yağcı Çağlayık D, Ergönül O, Yüce A. An imported dengue Fever case in Turkey and review of the literature. Mikrobiyol Bul. 2013;47:173-180. Review. (Article in Turkish)
22. Leo YS, Thein TL, Fisher DA, Low JG, Oh HM, Narayanan RL, Gan VC, Lee VJ, Lye DC. Confirmed adult dengue deaths in Singapore: 5-year multicenter retrospective study. BMC Infect Dis. 2011;11:123.
23. Figueiredo MA, Rodrigues LC, Barreto ML, Lima JW, Costa MC, Morato V, Blanton R, Vasconcelos PF, Nunes MR, Teixeira MG. Allegies and diabetes as risk factors for dengue hemorrhagic fever: result of a case control study. PLoS Negl Trop Dis. 2016;4:e699.
24. Moraes GH, de Fátima DE, Duarte EC. Determinants of mortality from severe dengue in Brazil: a population-based case-control study. Am J Trop Med Hyg. 2013;88:670–676.
25. Tomashek KM, Gregory CJ, Rivera Sánchez A, Bartek MA, Garcia Rivera EJ, Hunsperger E, Muñoz-Jordán JL, Sun W. Dengue Deaths in Puerto Rico: Lessons Learned from the 2007 Epidemic. PLoS Negl Trop Dis. 2012;6:e1614.
26. Laoprasopwattana K, Chaimongkol W, Pruekprasert P, Geater A. Acute respiratory failure and active bleeding are the important fatality predictive factors for severe dengue viral infection. PLoS One. 2014;9:e114499.
27. Blacksell SD, Doust JA, Newton PN, Peacock SJ, Day NP, Dondorp AM. A systematic review and meta-analysis of the diagnostic accuracy of rapid immunochromatographic assays fort he detection of dengue virus IgM antibodies during acute infection. Trans R Soc Trop Med Hyg. 2006;100:775-784.
28. Korzenlewski K, Juszczak D, Jerzemowski J. Skin lesions in returning travellers. Int Marit Health. 2015;66:173-180.
29. Nolte KB, Taylor DG, Richmond JY. Biosafety considerations for autopsy. Am J Forensic Med Pathol. 2002;23:107-122.
30. Nolte KB, Hanzlick RL, Payne DC, Kroger AT, Oliver WR, Baker AM, McGowan DE, DeJong JL, Bell MR, Guarner J, Shieh WJ, Zaki SR. Medical examiners, coroners and biologic terrorism a guidebook for surveillance and case management. MMWR Recomm Rep. 2004;53:1-27.
31. World Health Organization. Laboratory biosafety manual. 3rd edition, Geneva 2004.
32. U.S. Department of Health and Human Services Public Health Service Centers for Disease Control and Prevention National Institutes of Health. Biosafety in Microbiological and Biomedical Laboratories. 5th edition, 2009.
33. http://data.unhcr.org/syrianrefugees/regional.php (Accessed October 28, 2016)
34. Petersen E, Baekeland S, Memish ZA, Leblebicioglu H. Infectious disease risk from the Syrian conflict. Int J Infect Dis. 2013;17:e666-e667.