OPEN

PRS GLOBAL OPEN

REVIEW ARTICLE

Hand/Peripheral Nerve

Getting Better Results in Flexor Tendon Surgery and Therapy

Egemen Ayhan, MD*
Zeynep Tuna, PT, PhD†
Cigdem Oksuz, PT, PhD‡

Summary: Recently, better outcomes have been reported when up-to-date developments in flexor tendon surgery and therapy were followed. Slightly tensioned multistrand repairs, judicious venting of pulleys, and early active motion are widely accepted principles. In addition to these principles, tailoring of the repair according to intraoperative active movement with wide awake local anesthesia no tourniquet (WALANT) surgical setting is recommended for better results. We aimed to describe our up-to-date approach to flexor tendon surgery and therapy with the help of visual communication tools of this age. The ideal primary repair of flexor tendons, the management of delayed presentation flexor tendon injuries, the key steps to achieve better results with flexor tendon therapy, and the tele-rehabilitation experience during COVID-19 pandemic will be highlighted. Zone 2 flexor tendon injuries are the most demanding part and will be focused on. *(Plast Reconstr Surg Glob Open 2021;9:e3432; doi: 10.1097/GOX.0000000000003432; Published online 18 February 2021.)*

GOALS OF THE PROCEDURE

- To describe the ideal primary flexor tendon repair with recent evolutions;
- To present management of delayed presentation flexor tendon injuries;
- To emphasize custom-made tendon surgery with WALANT;
- To describe key steps to achieve better results with flexor tendon therapy;
- To report tele-rehabilitation experience during the COVID-19 pandemic.

DESCRIPTION OF MOST-EFFECTIVE PROCEDURES

In the last decade, flexor tendon surgery and therapy details have significantly evolved and outcomes are encouraging, with rare ruptures and low tenolysis rates (5%–10%).[1–6] Currently, 2-strand or tension-free repairs with weak core sutures and passive rehabilitation protocols like Kleinert (rubber-band traction) or Duran have been widely abandoned, and better outcomes were reported with slightly tensioned multistrand repairs, judicious venting of pulleys, and early active motion.[1–8] Moreover, tailoring of the repair according to intraoperative active movement with wide awake local anesthesia no tourniquet (WALANT) surgical setting was recommended.[1,7,9–12] However, to follow up-to-date guidelines may not always be easy for any busy surgeon of the hand trauma, and unsatisfactory outcomes still exist in today's practice. In this article, we aimed to enlighten the readers about our approach achieve better results in flexor tendon surgery and therapy with the help of visual communication tools of this age. Zone 2 flexor tendon injuries are the most demanding part and will be focused.

There are two fundamental basics for "getting better results in flexor tendon surgery and therapy":

1. To perform an ideal surgical repair according to up-to-date guidelines;
2. To manage the patient carefully in the postoperative therapy period.

The Ideal Flexor Tendon Repair

A step-by-step ideal flexor tendon repair is as follows:

1. Minimal but satisfactory exposure;
2. A solid 4- to 6-strands core suture repair with slight bulkiness on the repair site;
3. Tailoring of particular finger's flexor tendon repair with WALANT surgical setting.

*From the *Department of Orthopaedics and Traumatology, Diskapi Yildirim Beyazit Training and Research Hospital, University of Health Sciences Turkey, Ankara, Turkey; †Department of Physiotherapy and Rehabilitation, Faculty of Health Sciences, Gazi University, Ankara, Turkey; and ‡Department of Occupational Therapy, Faculty of Health Sciences, Hacettepe University, Ankara, Turkey.*

Received for publication September 29, 2020; accepted December 23, 2020.

Copyright © 2021 The Authors. Published by Wolters Kluwer Health, Inc. on behalf of The American Society of Plastic Surgeons. This is an open-access article distributed under the terms of the Creative Commons Attribution-Non Commercial-No Derivatives License 4.0 (CCBY-NC-ND), where it is permissible to download and share the work provided it is properly cited. The work cannot be changed in any way or used commercially without permission from the journal.

DOI: 10.1097/GOX.0000000000003432

Disclosure: *The authors have no financial interest to declare in relation to the content of this article. No funding was received for this study.*

Related Digital Media are available in the full-text version of the article on www.PRSGlobalOpen.com.

Downloaded from http://journals.lww.com/prsgo by BhDMf5ePHKav1zEoum1tQfN4a+kJLhEZgbsIHo4XMi0hCywCX1AWnYQp/IlQrHD3i3D0OdRyi7TvSFl4Cf3VC1y0abggQZXdgGj2MwlZLeI= on 03/09/2021

1. Minimal but Satisfactory Exposure

The skin incisions are better if they are as minimal as possible in order to decrease postoperative finger edema and potential adhesions.[1] However, if the surgeon is not comfortable, it is sensible not to insist on a mini-incision, but to insist on ideal repair with satisfactory exposure. Bruner or rectangular incisions are mostly preferred. We prefer meticulous and sharp scalpel dissection throughout tendon surgery to prevent postoperative adhesions and very rarely use cautery for coagulation. The skin flaps are sewn back to the finger dorsum, which stops bleeding without using a coagulator, especially when the vessels were already vasoconstricted with WALANT. (**See Video 1 [online],** which displays the exposure technique of flexor tendons in zone 2.) In an animal model, bipolar coagulators and CO_2 lasers were shown to be associated with significantly increased adhesion formation because of thermal damage compared with sharp scalpel dissection alone in tendon surgery.[13] The retracted tendon ends can be found by an additional distal palm incision at the A1 level and pushed distally by using 2 forceps. If it was not possible to push the tendon end distally, one can advance a catheter distal to proximal, and then retrieve the tendon by tying tendon to tube and pulling them distally. The retrieved proximal end can be fixed with a needle. (**See Video 2 [online],** which displays flexor tendon retrieval under A2 pulley.)

2. Solid Repair with Slight Bulkiness

We try to perform a locking 4- to 6-strand flexor tendon repair with a suture purchase of 0.7–1.0 cm.[1,14] This creates a slight bulkiness (20%–30% of tendon size) on the repair site and makes the repair slightly tensioned to encourage early active rehabilitation. (**See Video 3 [online],** which displays delayed primary repair of small finger flexor digitorum profundus (FDP5) tendon at 40th day post-injury.) We add running and locking peripheral sutures to smooth volar and lateral sites of the repair, but we do not attempt dorsal site if it is not readily accessible. We use 3:0 or 4:0 nonabsorbable Prolene or absorbable polydioxanone (PDS) for core suturing, and 5:0 or 6:0 Prolene or PDS for peripheral suturing.

3. Tailoring of Particular Finger's Flexor Tendon Repair

We regularly prefer WALANT for flexor tendon surgery because it allows us to make necessary adjustments on repaired tendons.[11] After the repair, we ask the patient to actively flex and extend his/her finger to observe free tendon gliding and any gapping at the repair site.[9,11] If there is any gapping, we strengthen the repair with additional core sutures. (**See Video 4 [online],** which displays active digital flexion-extension test and gapping of the repair site.) If there is any constricting pulley to block smooth tendon gliding, we judiciously vent. We sometimes end up with total venting of C1, A3, C2, A4, C3 pulleys, and re-evaluate particular finger's active movement. Although mild bowstringing may occur in such extended pulley releases, it may not always affect finger flexion clinically.[1,3] **(See Video 5 [online],** which displays small finger flexor digitorum profundus (FDP5) tendon repair with extended pulley release.)

However, in rare instances, if we observe any clinically significant bowstringing during active movement, we do reconstruct a pulley. For better dexterity and when it is straightforward, we prefer to repair at least 1 slip of flexor digitorum superficialis (FDS) tendon. When the intraoperative active movement shows proximal interphalangeal joint (PIPJ) hyperextension deformity, we repair the other FDS slip, as well. Simply, we check each repair or reconstruction with intraoperative active movement and allow the patient to guide us for better tailoring of his/her flexor tendon repair. (**See Video 6 [online],** which displays tailoring of flexor tendon injuries in long, ring, and small fingers according to intraoperative active movement with WALANT.)

Delayed Presentation of Flexor Tendon Injuries

We prefer to perform primary repair whenever possible, even a few months after the injury.[1,15] However, the decision for delayed primary repair, primary grafting, or secondary reconstruction is based on the intraoperative judgment with WALANT surgical setting, and the patient must be prepared for possible procedures preoperatively. We check the delayed primary repair with active flexion-extension test and do nothing if the active movement of the repaired tendon satisfies both the patient and us **(See Video 3 [online],** which displays delayed primary repair of small finger flexor digitorum profundus (FDP5) tendon at 40th day post-injury.) We also accept mild (<30 degrees) flexion deformity and agree with Tang JB that persistent supervised rehabilitation over the subsequent weeks or months relieves myostatic contracture and restores joint motion in months.[7,8,15] If active movement testing reveals that myostatic contracture results in moderate (>30 degrees) finger flexion deformity, we perform an additional fractional lengthening (tendon lengthening by tenotomy at musculotendinous junction) of the particular muscle at distal forearm.[15–17] **(See Video 7 [online],** which displays tailoring after delayed primary repair of index and long flexor digitorum profundus tendons with fractional lengthening and pulley reconstruction.)

We advise flexor digitorum profundus (FDP) muscle fractional lengthening, especially for the index finger because it often has a separate muscle belly. (**See Video 8 [online],** which displays delayed primary repair followed by fractional lengthening of index finger flexor digitorum profundus tendon (FDP2) for the patient in **Video 1**.)

It may also work for the long finger, as in **Video 7** (**See Video 7 [online]**), but as there are more interconnections between the ring and fifth-finger FDPs, it may not work for isolated lengthening of those 2 fingers as well as that of index finger.[16,18] When myostatic contracture is significant and does not allow for delayed primary repair, we perform one-stage grafting if the tendon gliding surface scarring is not significant. Finally, if the scarring is significant, such as following infection or in revision surgeries, we prefer 2-stage flexor tendon reconstruction (Hunter rod). When the Hunter rod was not available, we used a feeding tube in a few cases. **(See Video 9 [online],** which displays Flexor tendon reconstruction second stage with WALANT.) We think that custom-made tendon surgery with WALANT

stands as a paradigm shift for the near future. A particular patient uses his/her particular muscle force, tendon excursion, and joint laxity to generate a specific movement. Therefore, tendon surgery is a "balance" surgery, and we benefit from WALANT to tailor our repair and to adjust the balance according to active movement of the particular patient.

Key Steps to Achieve Better Results with Flexor Tendon Therapy

- **Patient-centered Approach in Flexor Tendon Therapy**

The up-to-date approach in the surgical techniques in flexor tendon repair has been changing our rehabilitation practice from passive methods to more active ones. But we think that getting better results in flexor tendon surgery and therapy depends on a patient-centered approach instead of a strictly structured protocol.[19] We prefer early and controlled active motion methods for their well-known benefits; however, we are obliged to shift to other methods in some patients. For example, in compliant patients, we would choose a true active motion protocol starting within the first postoperative week. Rarely, we could have to use early passive motion protocols in patients who live in the rural area and do not have access to supervised hand therapy. In conclusion, the postoperative hand therapy should be chosen in an agreement among the surgeon, the therapist, and the patient for each case.

- **Stick to Close Communication**

This patient-centered approach requires a close communication with the patient. To achieve it, in our clinical practice, the therapist tries to participate to surgery and patient education starts intraoperatively. (**See Video 10 [online],** which displays meeting of the patient with therapist and intraoperative education.)

In this way, the patient figures out that his/her whole treatment requires a team-work and the patient meets a familiar face in the upcoming therapy sessions. Intraoperative total active movement examination before closure of the skin helps the therapist and the patient to gain confidence to move the repair finger afterward.[20]

- **Prefer Active Rehabilitation Regimes**

Early active motion has been reported to provide better functional outcomes in several reviews and meta-analyses.[12,21,22] In a regular basis, we favor the Saint John protocol.[23]

Starting from the first intraoperative introduction, we advise patients to keep their hands elevated for 1 week. We prefer a static dorsal wrist-hand-finger orthosis with the wrist in neutral, metacarpophalangeal joints in 40 degrees–50 degrees of flexion, and interphalangeal joints in full extension. We wait until the postoperative third to fifth days before starting any exercises to increase swelling and pain.[7,23,24] Each therapy session starts with passive full composite flexion to reduce the work of flexion due to swelling and joint stiffness and to prepare for the active contraction. The patient is reminded that "he/she can move the repaired finger but cannot use it."[23] Patients wear the splint the whole day, and perform the passive exercises of 20 repeats and active exercises of 10 repeats at each awake hour within the splint. Three-finger blocking active distal interphalangeal flexion is allowed by the beginning of the second week and 2-finger blocking (distal and proximal interphalangeal flexion) active exercises are started at the beginning of the third week. Patients can progress into half-fist toward the end of the second week or third week when they can move their fingers pain-free (pain-guided therapy). By the end of the fourth week, patients are allowed to make a "full-fist with no force."[1] Patients are warned that they can remove the splint only if they are in a safe environment between fourth and sixth weeks. Night splinting is continued and patients start to use the hand in light daily-life activities like using mobile devices, eating, and drinking. After 6 weeks, the splint is totally removed. Isolated blocking exercises can be started between 6–8 weeks if tendon excursion is insufficient. (See **Video 11 [online],** which displays the Saint John rehabilitation protocol for the patient in **Video 5**.)

Tele-rehabilitation

Most therapy units were closed down during the COVID-19 pandemic and we used tele-rehabilitation (video-calls) as an alternative approach. Similarly, recent studies showed that the rehabilitation field has been showing a tendency toward digital options.[25,26] Therapists as well as patients are happy to be treated remotely as they can avoid the COVID-19 infection risk because they do not need to visit a clinical environment repeatedly. Moreover, tele-rehabilitation may be a good option also in rural areas where a hand therapist is not available nearby. However, tele-rehabilitation has a few limitations. Firstly, in general, it is more suitable in younger patients who are more familiar to digital technologies. Secondly, a strong internet connection, a camera and a microphone are needed to perform a synchronous video call. Finally, hand therapy requires true touch on the patient's hand and a therapist both heals and examines the patient during a real session through his/her hands. Tele-rehabilitation does not seem to be a replacement for face-to face therapy; however, it seems as a promising method under extraordinary conditions. Our initial experience in 10 patients resulted in acceptable to excellent outcomes. We can conclude that patient compliance is the key factor for good functional outcomes, which is identical to face-to-face hand therapy. (See **Video 12 [online],** which displays tele-rehabilitation.) Some technical tips are considered to be helpful for a video-call hand therapy session.

- Video-call sessions can be scheduled any time during the day via many different applications of a device with a camera and microphone (mobile phone, tablet, and computer).
- The room should be quiet and well-lighted. Sit at a table and adjust your distance that you can fit within the video frame. The patient should also do the same.
- If a tablet or mobile phone is used, a tablet or mobile phone holder is very helpful because it provides the therapist to be hands-free and show the exercises on herself/himself.

- At the beginning of each session, check out the exercises from the previous session to see whether the patient did understand and performed everything correctly.
- Self-treatment videos can be demanded from the patient randomly at any time. On such a self-recorded video from the patient, it can be checked if he/she performs the exercises correctly without any supervision.
- A number of repetitions or any other reminders can be sent as a text message. Screenshots of those messages are very helpful because the patient can store them in his photograph gallery and find them easily whenever he needs, which is easier than finding them among all messages.
- To follow the pain-guided therapy is also logical with tele-rehabilitation.[23]
- While teaching the scar massage, patient's incision can be imitated by the therapist on her/his own hand through drawing a line by a pen during the video conference.

AVOIDING AND MANAGING MOST-DANGEROUS COMPLICATIONS

When an ideal repair is done obeying to up-to-date protocols, ruptures are rare in today's flexor tendon repairs.[2,4,5] To avoid a rupture, we suggest a multistrand solid flexor tendon repair and confirming the no-gapping by intraoperative active movement. If any gapping of the repair was observed, the repair must be strengthened. (**See Video 4**.) The full fist must be disallowed before postoperative 4 weeks during early active rehabilitation. When a rupture is evident, we manage it as in delayed presentation of flexor tendon injuries.

Adhesions are still a problem in today's flexor tendon repairs, especially when there are accompanying bone or severe soft tissue injuries.[1,7] Limited skin incisions, gentle handling of the tendons, and sharp dissections are important surgical tips to decrease adhesion rates. We try not to use cautery especially around tendons and let minor bleeding coagulate naturally. We benefit from intraoperative active movement for tailoring the repair and perform necessary adjustments accordingly to establish free gliding of the tendon. Therapist-supervised early active rehabilitation and close communication with therapist are the mainstays of the postoperative period. When the adhesion is evident by 12th postoperative week, we do not wait anymore and perform a tenolysis with the WALANT method. Long-standing flexor tendon adhesions result in PIPJ flexion contractures and an arthrolysis is generally needed. However, sometimes the patient cannot actively extend PIPJ after arthrolysis despite passive extension is possible. In such situations, we prefer relative motion flexion splints to improve PIPJ extension.[27–30] (See **Video 13 [online],** which displays relative motion flexion splint for proximal interphalangeal joint extension lag.)

PEARLS AND PITFALLS

- The hinges of the zig-zag (Bruner) incisions may be better if they extend well to the sides of finger at the level of volar creases. Otherwise, subsequent scarring of the skin may augment flexion contracture of the finger (Fig. 1). Mid-lateral incision can be preferred, but it causes indirect approach to flexor tendons.

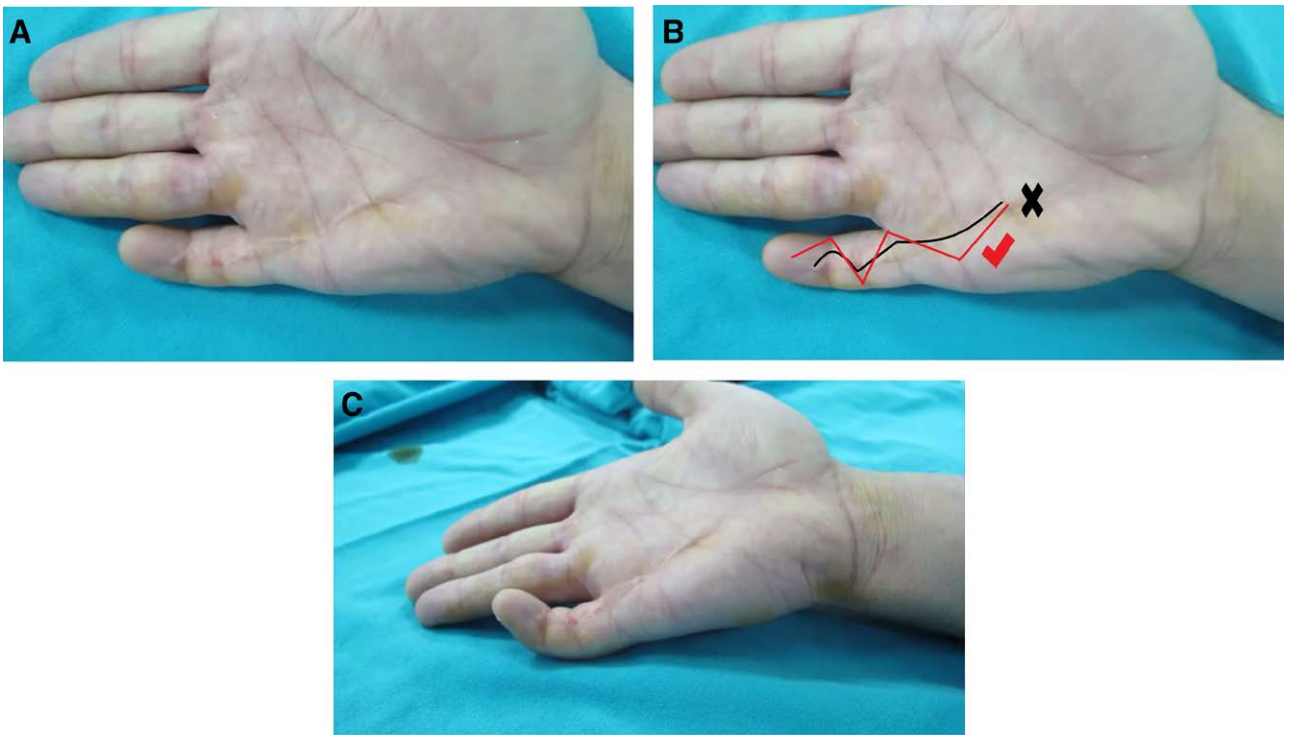

Fig. 1. Zig-zag (Bruner) incision scarring after a flexor tendon repair. A, The hinges of the incision were not extending to the sides of the finger. B, The incision would be better if done as in red lines. C, Flexion contracture of the finger.

- We prefer to repair at least one slip of FDS tendon because it may be important for pinch dexterity in the index and long fingers.[31] If the repair lies within A2 pulley, we prefer to release A2 pulley partially rather than sacrificing all FDS slips for index and long fingers. For the ring finger, we repair FDS slip(s) when it is straightforward or when there is PIPJ hyperextension problem **(See Video 6 [online]**). We almost never repair the FDS tendon of small finger.
- The pulley reconstructions must be appropriately tensioned.[32] Loose pulleys will cause tendon bowstringing, and overtightened pulleys will impede free tendon gliding. These pitfalls predispose a finger to motion restrictions, and once again, intraoperative active movement pearl guides for optimal tensioning.
- When there is apparent edema of the finger, we apply Coban bandage and cold therapy in addition to hand elevation. In such situations, we continue with passive exercises and delay active exercises to the end of second week as the excessive edema results in increased work of flexion due to friction. Taking warning notes on patient's progress and visual recordings (photographs and videos) are critical to guide your therapy progress.
- The decision to progress toward full fist needs more attention due to increased risk of rupture. In the biomechanical studies of Tang et al, they reported that increased curvature of the tendon (ie, as a simulation of increasing finger flexion) caused increased curvilinear tension on the tendon.[33,34] Therefore, progressing to a full fist should be done cautiously and can be postponed to the end of the sixth week.
- The best management of flexor tendon injury depends on teamwork. This team must consist of at least 1 surgeon and therapist who are dedicated to hand surgery and therapy. The dedicated team must follow recent developments about flexor tendon surgery and therapy, and must take care of any complications (eg, stiffness, adhesion, rupture) during the healing period. The surgeon(s) and therapist(s) must feel confident in each other; the surgeon must not worry about the appropriate postoperative rehabilitation process while repairing the tendon, and the therapist must not care about the precise "ideal" repair while applying postoperative hand therapy. The management of whole healing period, which can take several months, needs the cooperation of team members and patient. Therefore, patient compliance is another important factor for success. For noncompliant patients, we try to improve compliance by presenting the team image with therapist colleagues. The therapist attends the operation if possible, and discusses with the surgeon the postoperative therapy protocol simultaneously tailored flexor tendon repair.[10] When a dedicated therapist is not available, the surgeon should take care of the whole postoperative therapy alone. Therefore, intraoperative education of the awake patient by the surgeon is an important tip to improve compliance of the patient in the postoperative period and will be a time-saving approach, as well.

WHAT PATIENTS SHOULD KNOW BEFORE UNDERGOING THIS PROCEDURE

- Return to work can take several months, and patient compliance is very important to reduce the healing period and for the overall functional outcome. The importance of adherence to therapy period must be stressed to the patients.
- Around 10% of the patients may require secondary surgeries for complications.

Egemen Ayhan, MD
Mutlukent Mh. Angora Evleri
No: 2/6, Cankaya
Ankara, Turkey
E-mail: egemenay@yahoo.com

REFERENCES

1. Tang JB. Flexor tendon injuries. *Clin Plast Surg.* 2019;46:295–306.
2. Tang JB, Zhou X, Pan ZJ, et al. Strong digital flexor tendon repair, extension-flexion test, and early active flexion: experience in 300 tendons. *Hand Clin.* 2017;33:455–463.
3. Giesen T, Reissner L, Besmens I, et al. Flexor tendon repair in the hand with the M-Tang technique (without peripheral sutures), pulley division, and early active motion. *J Hand Surg Eur Vol.* 2018;43:474–479.
4. Zhou X, Li XR, Qing J, et al. Outcomes of the six-strand M-Tang repair for zone 2 primary flexor tendon repair in 54 fingers. *J Hand Surg Eur Vol.* 2017;42:462–468.
5. Pan ZJ, Xu YF, Pan L, et al. Zone 2 flexor tendon repairs using a tensioned strong core suture, sparse peripheral stitches and early active motion: results in 60 fingers. *J Hand Surg Eur Vol.* 2019;44:361–366.
6. Moriya K, Yoshizu T, Tsubokawa N, et al. Outcomes of flexor tendon repairs in zone 2 subzones with early active mobilization. *J Hand Surg Eur Vol.* 2017;42:896–902.
7. Tang JB. New developments are improving flexor tendon repair. *Plast Reconstr Surg.* 2018;141:1427–1437.
8. Tang JB. Release of the A4 pulley to facilitate zone II flexor tendon repair. *J Hand Surg Am.* 2014;39:2300–2307.
9. Lalonde D, Higgins A. Wide awake flexor tendon repair in the finger. *Plast Reconstr Surg Glob Open.* 2016;4:e797.
10. Lalonde DH. Wide-awake flexor tendon repair. *Plast Reconstr Surg.* 2009;123:623–625.
11. Lalonde DH, Martin AL. Wide-awake flexor tendon repair and early tendon mobilization in zones 1 and 2. *Hand Clin.* 2013;29:207–213.
12. Khor WS, Langer MF, Wong R, et al. Improving outcomes in tendon repair: a critical look at the evidence for flexor tendon repair and rehabilitation. *Plast Reconstr Surg.* 2016;138:1045e–1058e.
13. Hatano I, Suga T, Diao E, et al. Adhesions from flexor tendon surgery: an animal study comparing surgical techniques. *J Hand Surg Am.* 2000;25:252–259.
14. Tang JB, Zhang Y, Cao Y, et al. Core suture purchase affects strength of tendon repairs. *J Hand Surg Am.* 2005;30:1262–1266.
15. Tang JB. Uncommon methods of flexor tendon and tendon-bone repairs and grafting. *Hand Clin.* 2013;29:215–221.
16. Le Viet D. Flexor tendon lengthening by tenotomy at the musculotendinous junction. *Ann Plast Surg.* 1986;17:239–246.
17. Tang JB, Chang J, Elliot D, et al. IFSSH Flexor Tendon Committee report 2014: from the IFSSH Flexor Tendon Committee (Chairman: Jin Bo Tang). *J Hand Surg Eur Vol.* 2014;39:107–115.
18. Lung BE, Burns B. *Anatomy, Shoulder and Upper Limb, Hand Flexor Digitorum Profundus Muscle.* [Updated 2020 Aug 10]. In: StatPearls [Internet]. Treasure Island, FL: StatPearls Publishing; 2020.

19. Vucekovich K, Gallardo G, Fiala K. Rehabilitation after flexor tendon repair, reconstruction, and tenolysis. *Hand Clin.* 2005;21:257–265.
20. Higgins A, Lalonde DH, Bell M, et al. Avoiding flexor tendon repair rupture with intraoperative total active movement examination. *Plast Reconstr Surg.* 2010;126:941–945.
21. Starr HM, Snoddy M, Hammond KE, et al. Flexor tendon repair rehabilitation protocols: a systematic review. *J Hand Surg Am.* 2013;38:1712–1717.e1.
22. Chesney A, Chauhan A, Kattan A, et al. Systematic review of flexor tendon rehabilitation protocols in zone II of the hand. *Plast Reconstr Surg.* 2011;127:1583–1592.
23. Higgins A, Lalonde DH. Flexor tendon repair postoperative rehabilitation: the saint john protocol. *Plast Reconstr Surg Glob Open.* 2016;4:e1134.
24. Cao Y, Chen CH, Wu YF, et al. Digital oedema, adhesion formation and resistance to digital motion after primary flexor tendon repair. *J Hand Surg Eur Vol.* 2008;33:745–752.
25. Prada V, Bellone E, Schenone A, et al. The suspected SARS-Cov-2 infection in a Charcot-Marie-Tooth patient undergoing postsurgical rehabilitation: the value of telerehabilitation for evaluation and continuing treatment. *Int J Rehabil Res.* 2020;43:285–286.
26. Minghelli B, Soares A, Guerreiro A, et al. Physiotherapy services in the face of a pandemic. *Rev Assoc Med Bras (1992).* 2020;66:491–497.
27. Merritt WH, Jarrell K. A paradigm shift in managing acute and chronic boutonniere deformity: anatomic rationale and early clinical results for the relative motion concept permitting immediate active motion and hand use. *Ann Plast Surg.* 2020;84:S141–S150.
28. Colditz J. Active redirection instead of passive motion for joint stiffness. *IFSSH Ezine.* 2014;4:41–44.
29. Hirth MJ, Howell JW, O'Brien L. Relative motion orthoses in the management of various hand conditions: a scoping review. *J Hand Ther.* 2016;29:405–432.
30. Lalonde DH. Extensor tendon repair of the finger. In: Lalonde DH, ed. *Wide Awake Hand Surgery.* New York, N.Y.: Thieme; 2016:209–212.
31. Nikkhah D, Khanna A. Re: Pan ZJ, Xu YF, Pan L, Chen J. Zone 2 flexor tendon repairs using a tensioned strong core suture, sparse peripheral stitches and early active motion: results in 60 fingers. *J Hand Surg Eur.* 2019;44:871–873.
32. Wehbé MA, Mawr B, Hunter JM, et al. Two-stage flexor-tendon reconstruction. Ten-year experience. *J Bone Joint Surg Am.* 1986;68:752–763.
33. Tang JB, Xu Y, Wang B. Repair strength of tendons of varying gliding curvature: a study in a curvilinear model. *J Hand Surg Am.* 2003;28:243–249.
34. Tang JB, Cao Y, Xie RG. Effects of tension direction on strength of tendon repair. *J Hand Surg Am.* 2001;26:1105–1110.