Downloaded from http://journals.lww.com/retinalcases by BhDMf5ePHKav1zEoum1tQfN4a+kJLhEZgbsIHo4XMi0hCywCX1AWnYQp/IlQrHD3i3D0OdRyi7TvSFl4Cf3VC1y0abggQZXdtwnfKZBYtws= on 10/31/2023

REPAIR OF THE EXIT WOUND OF A PERFORATING GLOBE INJURY WITH THE AMNIOTIC MEMBRANE: A SURGICAL ADJUVANT FOR EARLY VITRECTOMY

Ahmet M. Hondur, MD

Purpose: To describe the use of the amniotic membrane for the repair of the exit wound of a perforating injury involving the retina and the choroid.

Methods: Case report.

Results: A 46-year-old man presented one day after a perforating ocular injury with an exit wound close to the inferior temporal retinal vascular arcade. The next day, the patient underwent a combined vitrectomy and phacoemulsification with intraocular lens implantation. During vitrectomy, a retinochoroidectomy was performed at the exit wound and the internal limiting membrane was peeled over the macula and up to the exit wound. Laser retinopexy was followed by plugging of a piece of the amniotic membrane to the exit wound. A second piece of the amniotic membrane was used to cover the bare retinochoroidectomy area. The surgery was concluded with a silicone exchange. Postoperatively, no sign of proliferative vitreoretinopathy was observed, and at 3 months, the silicone oil was removed. The follow-up was uneventful, and the eye achieved a final visual acuity of 20/30.

Conclusion: The amniotic membrane may offer a simple and safe solution for the repair of the exit wounds of perforating injuries involving the retina and the choroid. The use of the amniotic membrane for this purpose may afford the opportunity for early vitrectomy in the management of perforating ocular injuries.

RETINAL CASES & BRIEF REPORTS 17:775–778, 2023

From the Department of Ophthalmology, Gazi University Faculty of Medicine, Ankara, Turkey.

A perforating injury refers to an ocular trauma with both entry and exit wounds. A perforating injury that involves the retina and the choroid carries a poor visual and anatomic prognosis. This is particularly because of the healing of the posterior exit wound by the inward migration of scleral fibroblasts and the initiation of the wound healing that leads to proliferative vitreoretinopathy.[1,2] Early vitrectomy for injuries involving the posterior segment has been proposed to restore the ocular anatomy before the initiation of the wound healing response.[3] However, the unsutured posterior exit scleral wound has been a barrier for early vitrectomy in perforating injuries. Hence, a delayed approach for the reconstruction of the eye after the exit wound has healed has been the common practice.[4]

The amniotic membrane has been extensively used for the management of ocular surface disorders. Its use has recently been expanded for treatment of retinal diseases, such as persistent macular holes and optic pit maculopathy. The amniotic membrane has been particularly useful in the treatment of myopic posterior segment pathologies such as myopic macular holes and the associated posterior retinal breaks and retinal detachment.[5]

The present report aims to describe the use of the amniotic membrane for the repair of the exit wound of a perforating injury which involved the retina and the choroid. This approach may provide the opportunity

Copyright © by Ophthalmic Communications Society, Inc. Unauthorized reproduction of this article is prohibited.

for early vitrectomy in the management of perforating ocular injuries involving the retina and the choroid.

Case Report

A 46-year-old man presented with a perforating eye injury with a metallic foreign body in his right eye. The visual acuity of this eye was 20/60, and the intraocular pressure was 14 mmHg with air-puff tonometry. The scleral entry wound was inferotemporal and 2 mm away from the limbus. A mild corneal edema was present, and mild clouding of the lens was observed inferotemporally. In the fundus examination, a hemorrhage was observed inferiorly in the equatorial retina. The computed tomography revealed a 4-mm–sized metallic foreign body immediately posterior to the sclera (Figure 1A).

Phacoemulsification of the lens was followed by a posterior capsulorhexis, but the implantation of the intraocular lens was deferred. During vitrectomy, a posterior vitreous detachment was achieved, and a complete vitrectomy with vitreous base shaving was conducted. The infusion pressure was reduced to 15 mmHg to limit the fluid outflow from the wound. Next, the hemorrhage was cleared, and a retinochoroidectomy was performed at the exit wound (Figure 1, B–D). The internal limiting membrane was stained with the Brilliant Blue G Ophthalmic Solution (ILM Blue/TissueBlue, DORC, Zuidland, The Netherlands) and peeled over the macula up to the arcuate vessels and over the retinal surface inferiorly up to the exit wound (Figure 1E). Then, laser retinopexy was performed.

A 10 x 15 mm cryopreserved amniotic membrane graft was obtained. A 6-mm round piece was cut and stained with a few drops of the Brilliant Blue G Ophthalmic Solution to enhance its visualization inside the eye. Then, it was introduced into the eye through the phaco incision and moved to the posterior segment through the posterior capsulorhexis, and under chandelier illumination, it was bimanually plugged into the exit wound using two serrated forceps (Figure 1F). The chemosis due to fluid outflow from the exit wound rapidly resolved after this step. Another 6-mm round piece of the amniotic membrane was cut from the same graft and stained in the same fashion. After a partial perfluorocarbon exchange, it was introduced into the eye in the same fashion (Figure 1G) and placed to cover the retinochoroidectomy defect at the exit wound using the two serrated forceps (Figure 1H). Then, the intraocular lens was implanted. A cautious air exchange was performed with care to avoid displacement of the amniotic membrane. Then, silicone exchange was performed, and the vitrectomy incisions were sutured with 8/0 Vicryl sutures.

The postoperative course was eventless. After the silicone oil was removed at 3 months, the patient achieved a visual acuity of 20/30 at 4 months. The optical coherence tomography scan demonstrated an orderly glial tissue covering the exit wound (Figure 2).

Discussion

Perforating injuries involving a posterior exit wound in the retina carry a poor prognosis. Excluding instances of direct impact to the optic nerve or the macular area, the wound healing triggered at the exit point plays the major role in the poor prognosis. The inward migration of scleral fibroblasts is the initiating step of this wound healing. Injuries that involve the choroid and the sclera besides the retina demonstrate a more severe proliferative vitreoretinopathy compared with trauma cases in which the injury is limited to the retina.[1,2] Hence, perforating injuries lead to the greatest incidence of proliferative vitreoretinopathy among all open eye injuries.[6] Even in eyes in which the wound healing appears to be local and leaves the retina attached, the pulling of the scar on the surrounding retina leads to retinal incarceration to the wound site and formation of radial retinal folds. If the wound is close to the macula and/or the effects of the folds reach the macula, the visual acuity is severely affected.[7]

A significant surgical approach to avoid this wound healing response has been early vitrectomy with prophylactic chorioretinectomy for open globe injuries involving the retina and the choroid.[3,4,7] However, an important obstacle against early vitrectomy for perforating injuries has been the open exit wound. Surgical closure of the posterior exit wound has commonly been regarded as difficult and dangerous, because of the risk of extreme traction on the globe during attempts to reach the wound extraocularly, which can lead to extrusion of the intraocular tissues. Hence, vitrectomy has been regarded impossible before the scleral wounds have healed.[2,4]

Experimental studies have demonstrated that a period of 4-7 days is required for the sealing of scleral wounds.[1] Hence, the common timing for vitreoretinal surgery in the intraocular reconstruction of perforating injuries has been in the second half of the second week. However, with this timing approach, the wound healing process that seals the scleral exit wound also leads to inward migration of scleral fibroblasts and initiation of proliferative vitreoretinopathy.[4]

In the present report, we opted for early vitrectomy for the intraocular reconstruction of a perforating injury. With the use of the amniotic membrane, the scleral exit wound was sealed from the inside of the eye. With this approach, it was possible to perform vitrectomy without waiting for the posterior exit wound to seal by itself. This approach seemed to be

None of the authors has any financial/conflicting interests to disclose.

The author does not have any proprietary interest or any commercial association that might pose a conflict of interest in connection with the submitted article.

Reprint requests: Ahmet M. Hondur, MD, Gazi Universitesi Tip Fakultesi, Goz Hastaliklari AD, Yenimahalle, Ankara 06500, Turkey; e-mail: ahondur@gazi.edu.tr

Downloaded from http://journals.lww.com/retinalcases by BhDMf5ePHKav1zEoum1tQfN4a+kJLhEZgbsIHo4XMi0hCywCX1AWnYQp/IlQrHD3i3D0OdRyi7TvSFl4Cf3VC1y0abggQZXdtwnfKZBYtws= on 10/31/2023

Copyright © by Ophthalmic Communications Society, Inc. Unauthorized reproduction of this article is prohibited.

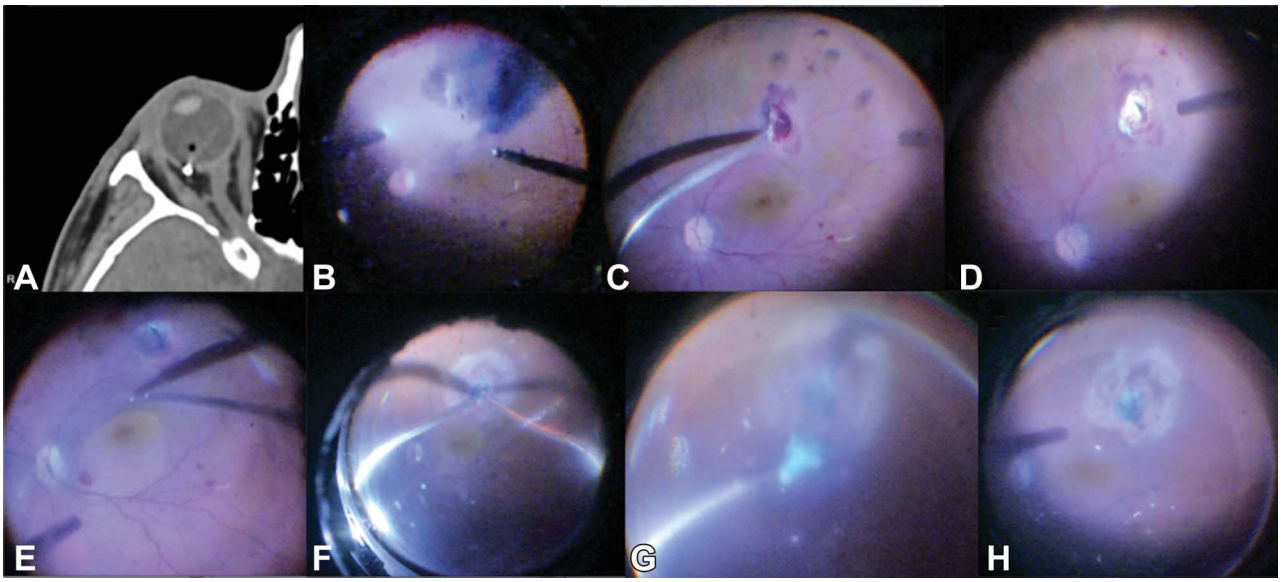

Fig. 1. A. The axial orbital computed tomography scan revealed a 4-mm–sized metallic foreign body immediately posterior to the sclera. **B.** The exit wound was camouflaged behind the hemorrhage close to the inferior temporal vascular arcade during initial stages of vitrectomy. **C.** After removal of the hemorrhage, the planned retinochoroidectomy area was cauterized. **D.** A clear view of the scleral exit wound was obtained after retinochoroidectomy. **E.** The internal limiting membrane was peeled over the macula and inferiorly up to the exit wound. **F.** After laser retinopexy, the first piece of the amniotic membrane was plugged into the scleral exit wound bimanually under chandelier illumination. **G and H.** A second piece of the amniotic membrane was introduced to the posterior segment similarly **(G)** and placed to cover the retinochoroidectomy defect at the exit wound **(H)**.

quite simple and straightforward. It also eliminated the risks of approaching the exit wound extraocularly, which probably would involve the risks of extreme traction on the globe. In addition, the plug of the amniotic membrane may also have served as a barrier for the inward migration of scleral fibroblasts. However, the use of the amniotic membrane to seal the exit wound may not be feasible in perforating injuries because of larger foreign bodies.

In a previous preliminary study, we evaluated the effects of the amniotic membrane on the retinal wound healing response in macular holes. Besides the widely anticipated effect of the amniotic membrane to serve as a scaffold for proper migration of glia, the amniotic membrane also demonstrated positive effects on the biomarkers involved in the retinal wound healing.[8] Therefore, a second piece of amniotic membrane was also placed over the wounded area to cover the defect in the retina and choroid.

In conclusion, the use of the amniotic membrane may serve as an important and simple surgical tool to close the posterior exit wound of perforating ocular injuries. It may also block the inward migration of scleral fibroblasts and, hence, downgrade the proliferative vitreoretinopathy originating from the exit wound. Further studies are required to clarify whether the use of the amniotic membrane may provide the path for early vitrectomy for perforating posterior segment injuries.

Key words: amniotic membrane, early vitrectomy, perforating ocular trauma, proliferative vitreoretinopathy.

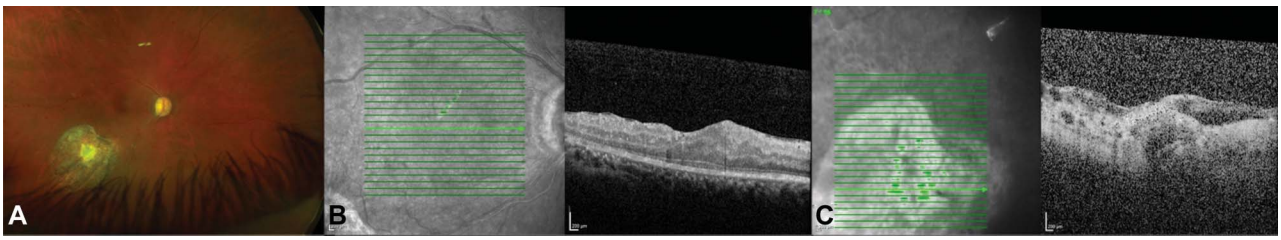

Fig. 2. A. At 4 months, the amniotic membrane appeared to be in place and covering the retinochoroidectomy area with surroundings laser scars in the widefield fundus photograph. **B.** A concurrent optical coherence tomography scan passing through the macular center demonstrated retinal wrinkling (dissociated optic nerve fiber layer appearance) because of internal limiting membrane peeling. **C.** At 5 months (2 months after silicone oil removal), the optical coherence tomography scan demonstrated a healed exit wound covered by glial tissue on the retinal side of the injury.

Downloaded from http://journals.lww.com/retinalcases by BhDMf5ePHKav1zEoum1tQfN4a+kJLhEZgbsIHo4XMi0hCywCX1AWnYQp/IlQrHD3i3D0OdRyi7TvSFl4Cf3VC1y0abggQZXdtwnfKZBYtws= on 10/31/2023

Copyright © by Ophthalmic Communications Society, Inc. Unauthorized reproduction of this article is prohibited.

References

1. Topping TM, Abrams GW, Machemer R. Experimental double-perforating injury of the posterior segment in rabbit eyes: the natural history of intraocular proliferation. Arch Ophthalmol 1979;97:735–742.
2. Recchia FM, Sternberg P. Surgery for ocular trauma: principles and techniques of treatment. In: Wilkinson CP, Hinton DR, Sadda RS, et al, eds. Ryan's Retina. 6th ed. New York: Elsevier; 2018:2081–2106.
3. Kuhn F, Mester V, Morris R. A proactive treatment approach for eyes with perforating injury. Klin Monbl Augenheilkd 2004;221:622–628.
4. Kuhn F, Morris R. Early vitrectomy for severe eye injuries. Eye (Lond). 2021;35:1288–1289.
5. Caporossi T, Tartaro R, Giansanti F, Rizzo S. The amniotic membrane for retinal pathologies. Insights on the surgical techniques. Graefes Arch Clin Exp Ophthalmol 2020;258:1347–1349.
6. Coyler M, Chun D, Bower K, et al. Perforating globe injuries during operation Iraqi Freedom. Ophthalmology 2008;118:2087–2093.
7. Kuhn F, Teixeira S, Pelayes DE. Late versus prophylactic chorioretinectomy for the prevention of trauma-related proliferative vitreoretinopathy. Ophthalmic Res 2012;48(Suppl 1):32–37.
8. Zeng Q, Karahan E, Hondur A, Tezel TH. Comperative anaysis of gliosis induced by covering of macular holes with a patch of retinal autograft vs. Human amniotic membrane. Invest Ophthalmol Vis Sci 2020;61:4392.

Downloaded from http://journals.lww.com/retinalcases by BhDMf5ePHKav1zEoum1tQfN4a+kJLhEZgbsIHo4XMi0hCywCX1AWnYQp/IlQrHD3i3D0OdRyi7TvSFl4Cf3VC1y0abggQZXdtwnfKZBYtws= on 10/31/2023

Copyright © by Ophthalmic Communications Society, Inc. Unauthorized reproduction of this article is prohibited.