Trisomy of 8q22.3~q23-qter following an unbalanced 1;8 translocation in a boy with multiple anomalies

Mehmet Ali Ergun[1], Sevim Balcı[2], Ece Konaç[1], Derya Kan[1], Sevda Menevşe[1], Oliver Bartsch[3]

[1]Department of Medical Biology and Genetics, Gazi University Faculty of Medicine, and [2]Department of Clinical Genetics, Hacettepe University İhsan Doğramacı Children's Hospital, Ankara, Turkey, and [3]Institute of Clinical Genetics, Medical Faculty, Dresden University of Technology, Dresden, Germany

SUMMARY: Ergun MA, Balcı S, Konaç E, Kan D, Menevşe S, Bartsch O. Trisomy of 8q22.3~q23-qter following an unbalanced 1;8 translocation in a boy with multiple anomalies. Turk J Pediatr 2004; 46: 384-387.

An 11-month-old boy was first referred with global developmental delay, pallor and heart defects (ASD, VSD, mitral and tricuspid valve insufficiency). He also had facial abnormalities. Standard karyotyping showed additional material on one chromosome 1p homolog, and fluorescence in situ hybridization (FISH) indicated an unbalanced translocation of 1pter~p36.33 and 8q22.3~q23. The breakpoint on 1p was found to reside very close to the telomere, making this a rare case of "almost pure" trisomy of 8q22.3~q23-qter, without a significant partial 1p36 monosomy by FISH technique. The patient's face resembled the peculiar face in previously reported cases of 8q23-qter duplication. This report supports that critical gene(s) for cardiac septum formation reside on distal chromosome 8q.

Key words: cardiac septal defects, mitral valve insufficiency, tricuspid valve insufficiency, unbalanced translocation, distal 8q trisomy.

Pure distal 8q trisomy is a rare disorder. Phenotypic features are known to vary in relation to the duplication size[1]. Clinical signs include low birth weight; facial abnormalities such as prominent forehead, flat occiput, hypertelorism, up-slanting palpebral fissure, nose and ear deformities, and thin upper lips; congenital heart defects; skeletal abnormalities; and retardation of growth and development (Table I)[1-7].

We report a boy with facial abnormalities, heart defect, developmental delay and unbalanced translocation of chromosomes 1p36.33 and 8q22.3~q23. The distal 1p monosomy was negligibly small, making this a rare case of "almost pure" trisomy of 8q22.3~q23-qter.

Case Report

This 11-month-old boy was born after a normal pregnancy to healthy, non-consanguineous parents. The mother and father were 22 and 32 years old, respectively. The patient presented with growth retardation, paleness, and inability to walk. At the age of 11 months, length was 72.5 cm (10-25th centile), weight 6.5 kg (<3rd centile) and

Table I. Comparison of the Phenotype and Karyotype of This Case to Similar Cases in the Literature

	Distal trisomy 8q[1,8]	Trisomy 8q23-qter[1,2-4,6]	This case
Growth retardation	+	+	+
Mental retardation	+	+	+
Triangular facial appearance	–	+	+
Microcephaly	+	+	+
Microphthalmia	+	+	+
Depressed nasal bridge	–	+	+
Cleft lip/palate	+	+	–
Low-set ears	+	+	+
Short and broad neck	+	+	+
Congenital heart defects	+	+	+
Skeletal abnormalities	+	+	–

head circumference 42 cm (<3rd centile). Findings included microcephaly, a peculiar and triangular face, frontal bossing, microphthalmia, hypertelorism, up-slanting palpebral fissure, depressed nasal bridge, low-set ears, short broad neck, inguinal hernia and developmental delay (Fig. 1a, b). Cardiologic evaluation indicated ventricular septal defect (VSD), atrial septal defect (ASD) and insufficiency of mitral and tricuspid valves. He had no craniosynostosis and no rib abnormalities.

(a)

(b)

Fig. 1. a, b: The patient at the age of 11 months.

Standard karyotyping was performed on trypsin-Giemsa banded (GTG) chromosomes from peripheral blood lymphocytes of the patient and his parents. An additional material on one chromosome 1p homolog of the patient, indicating an unbalanced translocation between chromosome 1 and an unknown chromosome, was detected (Fig. 2). Parental karyotypes were essentially normal, karyotypes 46,XX,1qh+ (confirmed by C-banding) and 46,XY, respectively. Therefore the translocation had occurred de novo. For the fluorescence in situ hybridization (FISH) studies, we used lymphocyte spreads from the patients. The breakpoint on 1p was defined using locus specific DNA probes TeIVysion 1p (Vysis, Downers Grove, IL) and CP5124 (Oncor, Gaithersburg, MD). The additional chromatin on 1p was identified using a panel of whole chromosome paints and was found to originate from chromosome 8 (Fig. 3a). Re-evaluation of G-banded metaphase clearly showed a translocation of 1p36 and 8q22.3~q23-qter. The breakpoint on 1p was studied using locus-specific DNA probes TeIVysion 1p (detecting the area of the locus CEB108/T7 on 1pter-p36.33) and CP5124 (detecting the area of the CDC2L1 gene at 1p36.3). TeIVysion 1p (Fig. 3b) and CP5124, respectively, yielded hybridization signals of normal size on the derivative chromosome 1 and the normal homolog 1. Results indicated a karyotype of 46,XY, add(1)(p36).ish der(1)t(1;8)(p36.33q22.3)(wcp8, CEB108/T7+, CDC2L1+, wcp1) de novo.

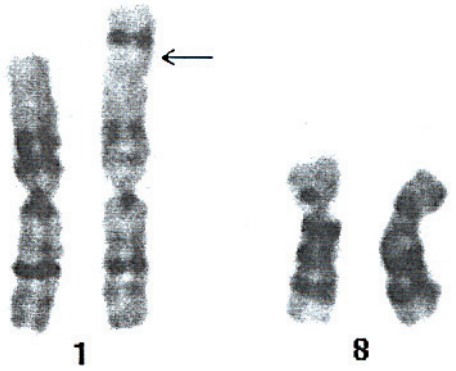

Fig. 2. Chromosomes 1 and 8 of the patient by GTG-banding.

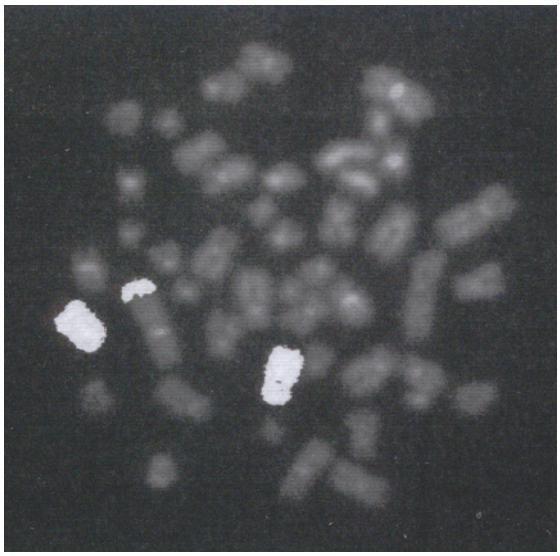

(a)

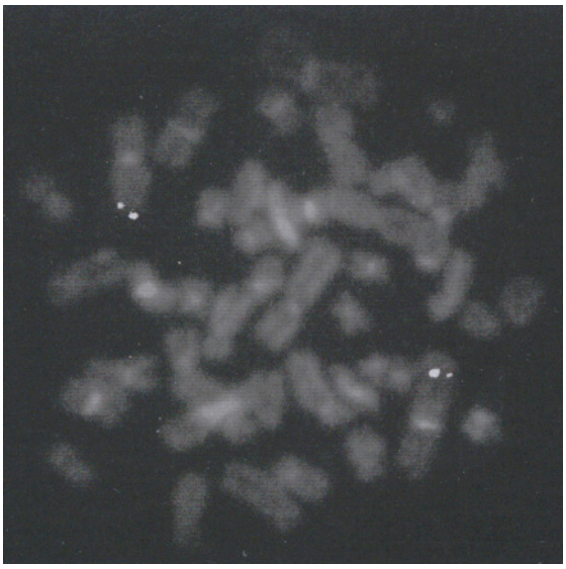

(b)

Fig. 3. a) Metaphase by FISH using a whole chromosome 8 paint. Note the chromosome 8 painted segment on the derivative homolog 1. b) Metaphase by FISH using a DNA probe for the 1p subtelomeric region (TeIVysion 1p). Note signals on both the derivative and normal chromosome 1.

DNA probe TeIVysion 1p (size, 90 kb) contains a locus (CEB108/T7) estimated to be within 300 kb of the end of the chromosome (manufacturer's data). Therefore, the breakpoint on chromosome 1p resides within less than 300 kb of the telomere, predicting that the distal 1p monosomy of the patient is extremely small and most likely genetically insignificant. All clinical signs of the patient may be ascribed to the 8q22.3~23-qter trisomy.

Discussion

We report a patient with "almost-pure" trisomy of 8q22.3~3.23-qter following a de novo 1;8 translocation. Comparable cases are rare. Six patients with "almost-pure" trisomy of 8q23-qter in three families were recorded[2-4,6], all summarized[1]. Another patient had mosaic tetrasomy 8q due to an inverted duplication of 8q23.3qter in an analphoid marker. The clinical findings included developmental delay, short stature, and contractures of the limbs and fingers[7]. Six patients had a smaller duplication of 8q24.1-qter and fewer and milder clinical signs[1].

Clinical signs with trisomy 8q23-qter include short stature, microcephaly, peculiar face, microphthalmia, cleft palate, short and broad neck, widely spaced nipples, congenital heart defects, small penis, overriding toes and mostly severe mental retardation[1]. Our patient shares many signs, including the short stature, microcephaly, peculiar face (with triangular face, frontal bossing, hypertelorism, microphthalmia, up-slanting palpebral fissure, depressed nasal bridge, and low-set ears), short broad neck, heart defect and developmental delay (Table I).

Distal 8q trisomy has long been associated with congenital heart defects[8]. Roskes et al.[9] cited 8p as a site for a gene involved in cardiac septum formation. A subset of patients with distal 8q duplications or mosaic trisomy 8 showed conotruncal heart defects[1,3,5]. In line with these observations, our patient demonstrated ASD, VSD, and insufficiency of mitral and tricuspid valves, adding evidence that gene(s) for the cardiac septum formation may reside on 8q22.3~23-qter.

In this study the diagnosis was confirmed by the FISH studies. Although the molecular cytogenetic fine localization of a chromosomal breakpoint usually requires a large set of locus-specific DNA probes, in this case, the unusual position of the 1p breakpoint enabled us to define the breakpoint with great precision (to an interval of less than 300 kb in size) by using only two different DNA probes.

In conclusion, this is a rare case of pure distal trisomy 8q diagnosed by FISH studies. The report contributes to the definition of the critical region for cardiac septum formation on distal chromosome 8q.

REFERENCES

1. Schinzel A. Catalogue of unbalanced chromosome aberrations in Man. In: Schinzel A (ed). 2nd revised and expanded edition. New York: Walter de Gruyter; 2001: 376-382.
2. Giorgi PL, Tarantino E, Formica A, Cipriani P, Dallapiccola B. Partial trisomy 8q resulting from maternal transmission t(2;8)(q373;q23). Acta Genet Med Gemellol (Roma) 1978; 27: 75-79.
3. Fineman RM, Ablow R, Breg WR, et al. Complete and partial trisomy of different segments of chromosome 8: case reports and review. Clin Genet 1979; 16: 390-398.
4. Vivarelli R, Scarinci R, Anichini C. La trisomia 8q parziale da traslocazione paterna (8;12): descrizione di due nuovi casi. Riv Ital Pediatr 1986; 12: 457-461.
5. Gelb BD, Towbin JA, McCabe ER, Sujansky E. San Luis Valley recombinant chromosome 8 and tetralogy of Fallot: a review of chromosome 8 anomalies and congenital heart disease. Am J Med Genet 1991; 40: 471-476.
6. Stengel-Rutkowski S, Lohse K, Herzog C, et al. Partial trisomy 8q. Two case reports with maternal translocation and inverted insertion: phenotype analyses and reflections on the risk. Clin Genet 1992; 42: 178-185.
7. Reddy KS, Sulcova V, Schwartz S, et al. Mosaic tetrasomy 8q: inverted duplication of 8q23.3qter in an analphoid marker. Am J Med Genet 2000; 92: 69-76.
8. Young RS, Hansen KL, Khodr GS. Five generations of t(4;8)(q35;q13) leading to a case of partial 8q trisomy with consideration of potential pregnancy outcomes from translocation carriers. Clin Genet 1984; 25: 522-527.
9. Roskes EJ, Boughman JA, Schwartz S, Cohen MM. Congenital cardiovascular malformations (CCVM) and structural chromosome abnormalities: a report of 9 cases and literature review. Clin Genet 1990; 38: 198-210.