Turkish Journal of Thoracic and Cardiovascular Surgery 2018;26(1):116-122
http://dx.doi.org/doi: 10.5606/tgkdc.dergisi.2018.13641

Original Article / Özgün Makale

First experiences and complications in video-assisted thoracoscopic surgery lobectomy at a thoracic surgery center

Göğüs cerrahisi merkezinde video-yardımlı torakoskopik cerrahi lobektomide ilk deneyimler ve komplikasyonlar

Göktürk Fındık, Funda İncekara, Mustafa Demiröz, Ebru Sayılır, Kubilay İnan, Seray Hazer, Koray Aydoğdu, Sadi Kaya

Department of Thoracic Surgery, Atatürk Chest Diseases and Thoracic Surgery Training and Research Hospital, Ankara, Turkey

ABSTRACT

Background: This study aims to report the difficulties and complications we experienced in video-assisted thoracoscopic surgery lobectomies performed at our thoracic surgery center.

Methods: A total of 76 patients (54 males, 22 females; mean age 48.3 years; range 9 to 83 years) who underwent video-assisted thoracoscopic surgery lobectomy between January 2012 and June 2016 were retrospectively reviewed. Preoperative patient characteristics such as additional diseases or tuberculosis history, stage for malignant diseases, surgical characteristics such as port properties and amount of bleeding, postoperative characteristics such as amount, time and duration of drainage, air leakage, and discharge time, morbidity and mortality rates, and their causes were evaluated.

Results: Of the patients, 35 were evaluated due to benign pulmonary diseases and 41 due to malignant pulmonary diseases. Postoperative prolonged air leakage developed in 14 patients. Of these patients, one was administered thoracotomy and primary repair, three were administered pleurodesis, and three were administered secondary pleurocan catheter, while the air leakage ended spontaneously in seven patients. Due to bleeding, one patient was treated with revision video-assisted thoracoscopic surgery on the same day postoperatively. One patient developed chylothorax and one patient developed pneumonia, which caused respiratory failure.

Conclusion: Video-assisted thoracoscopic surgery lobectomy is a safe thoracic procedure, which is used for both oncologic and non-oncologic diseases of the lung. Video-assisted thoracoscopic surgery may be performed by all thoracic surgeons experienced in open thoracic surgery. Thanks to the gained experiences, the rates of video-assisted thoracoscopic surgery lobectomy may improve in all centers.

Keywords: Complications; first cases; video-assisted thoracoscopic surgery lobectomy.

ÖZ

Amaç: Bu çalışmada göğüs cerrahisi merkezimizde uygulanan video-yardımlı torakoskopik cerrahi lobektomilerde deneyimlediğimiz zorluklar ve komplikasyonlar bildirildi.

Çalışma planı: Ocak 2012 - Haziran 2016 tarihleri arasında video-yardımlı torakoskopik cerrahi lobektomi geçiren toplam 76 hasta (54 erkek, 22 kadın; ort. yaş 48.3 yıl; dağılım 9-83 yıl) retrospektif olarak incelendi. Ek hastalıklar veya tüberküloz öyküsü gibi ameliyat öncesi hasta özellikleri, malign hastalıklar için evre; port nitelikleri ve kanama miktarı gibi cerrahi özellikler; drenaj miktarı, zamanı ve süresi, hava kaçağı ve taburcu zamanı gibi ameliyat sonrası özellikler; morbidite ve mortalite oranları ve bunların nedenleri değerlendirildi.

Bulgular: Hastaların 35'i benign pulmoner hastalıklar, 41'i malign pulmoner hastalıklar nedeni ile değerlendirildi. On dört hastada ameliyat sonrası uzamış hava kaçağı gelişti. Bu hastalardan birine torakotomi ve primer onarım, üçüne plörodezis ve üçüne sekonder plörakan dren uygulanır iken yedi hastada hava kaçağı kendiliğinden sona erdi. Kanama nedeniyle bir hasta ameliyat sonrası aynı gün revizyon video-yardımlı torakoskopik cerrahi ile tedavi edildi. Bir hastada şilotoraks ve bir hastada solunum yetmezliğine neden olan pnömoni gelişti.

Sonuç: Video-yardımlı torakoskopik cerrahi lobektomi akciğerin hem onkolojik hem de onkolojik olmayan hastalıkları için kullanılan güvenilir bir göğüs cerrahisi ameliyatıdır. Video-yardımlı torakoskopik cerrahi açık göğüs cerrahisinde deneyimli olan tüm göğüs cerrahları tarafından uygulanabilir. Edinilen deneyimler sayesinde video-yardımlı torakoskopik cerrahi lobektomi oranları tüm merkezlerde artabilir.

Anahtar sözcükler: Komplikasyonlar; ilk olgular; video-yardımlı torakoskopik cerrahi lobektomi.

Received: June 25, 2016 *Accepted*: March 27, 2017 *Published online*: January 09, 2018

Correspondence: Göktürk Fındık, MD. Atatürk Göğüs Hastalıkları ve Göğüs Cerrahisi Eğitim ve Araştırma Hastanesi, Göğüs Cerrahisi Kliniği, 06280 Keçiören, Ankara, Turkey. Tel: +90 312 - 567 77 77 e-mail: gokturkfindik@hotmail.com

Cite this article as:

Fındık G, İncekara F, Demiröz M, Sayılır E, İnan K, Hazer S, et al. First experiences and complications in video-assisted thoracoscopic surgery lobectomy at a thoracic surgery center. Turk Gogus Kalp Dama 2018;26(1):116-122.

©2018 All right reserved by the Turkish Society of Cardiovascular Surgery.

Performing a thoracic surgery through a thoracotomy may be more familiar and easier for a classical thoracic surgeon.[1] The site of approach and the point of incision are effective on the feasibility of the case and the surgical performance. The surgeons' intention is to achieve maximum benefit with minimum risks and to eliminate any unforeseen events before, during and after the operation. Such events may occur intraoperatively, such due to bad exposure or approach difficulties (e.g. as a result of false incisions) or bleeding, or postoperatively during the management of complications. Such consequences may be discouraging in being open-minded about new methods, both globally and in our country. Video-assisted thoracoscopic surgery (VATS) has undergone significant evolution over several decades. Although endoscopic instruments continued to improve, it was not until 1992 that the first VATS lobectomy for lung cancer was performed. Therefore, in this study, we aimed to report the difficulties and complications we experienced in VATS lobectomies performed at our thoracic surgery center.

PATIENTS AND METHODS

A total of 76 patients (54 males, 22 females; mean age 48.3 years; range 9 to 83 years), who underwent VATS lobectomy at Atatürk Chest Diseases and Thoracic Surgery Research and Training Hospital between January 2012 and June 2016, were retrospectively reviewed. Patients' age, sex and pathology findings were recorded. Preoperative patient characteristics such as additional diseases or tuberculosis history, stage for malignant diseases, surgical characteristics such as port properties and amount of bleeding, postoperative characteristics such as amount, time and duration of drainage, air leakage, and discharge time, morbidity and mortality rates, and their causes were studied. The study protocol was approved by the Atatürk Chest Diseases and Thoracic Surgery Research and Training Hospital Ethics Committee. A written informed consent was obtained from each patient. The study was conducted in accordance with the principles of the Declaration of Helsinki.

All operations were performed by one surgical team. Initial 45 operations were performed by three-portal approach; which consists of an utility incision measuring about 3-5 cm which is generally located on anterior aspect of the fifth intercostal space, one 10 mm port for the thoracoscope on the mid axillary line seventh intercostal space, and one 5 mm posterior access point near the tip of the scapula for only using a parenchyma retraction tool. Utility incision was placed directly over the hilum, which corresponds to the area between the nipple and the inferior angle of the scapula in the fifth intercostal space. Having gained experience, we used two-portal approach by eliminating the posterior incision in 26 cases, and finally performed VATS lobectomy through the uniportal approach (utility incision measuring about 3.5-4.5 cm at the anterior of the fifth intercostal space) in the last five cases as seen in Table 1. All operations were performed with a 10 mm 30° thoracoscope.

Statistical analysis

Statistical comparisons of baseline data between groups were carried out by the chi-square and Fisher's exact tests as appropriate. Preoperative

Table 1. Number of ports

	Three portal approach		Two portal approach		Uniportal approach	
	Benign diseases	Malign diseases	Benign diseases	Malign diseases	Benign diseases	Malign diseases
Right						
Upper lobectomy		5	1	3		
Middle lobectomy	6	1	3	1		
Lower lobectomy	5	5	2	3	2	1
Lower + middle lobectomy		1				
Upper + middle lobectomy		1				
Left						
Upper lobectomy		7		1		
Lower lobectomy	6	6	3	5	2	
Lingulectomy			2			
Lingulectomy + lower lobectomy	2		1			
Lingula protective upper lobectomy				1		
Total	19	26	12	14	4	1



Figure 1. Computed tomography images of benign lesions (left lower lobe bronchiectasis).

patient characteristics such as additional diseases or tuberculosis history, stage for malignant diseases, surgical characteristics such as port properties and amount of bleeding, postoperative characteristics such as amount, time and duration of drainage, air leakage, and discharge time, morbidity and mortality rates, and their causes were evaluated. Mann-Whitney U test was used in comparison of groups among independent groups. P values greater than 0.05 are meaningless, *p* values less than 0.05 are considered significant. The IBM SPSS version 21.0 (IBM Corp., Armong, NY, USA) software was used for statistical analysis.

RESULTS

We performed a total of 36 left-sided and 40 right-sided VATS lobectomies. The most common resection was lower lobectomy on both sides. Besides regular anatomic lobectomies, two right bilobectomies, three simultaneous left lower lobectomies and lingulectomies, and one lingula protective upper lobectomy were performed. While 35 patients had benign diseases (Figure 1), 41 had lung cancer (Figure 2a-d). Patients' distribution according to anatomic zone and pathologic types were shown in Table 2.

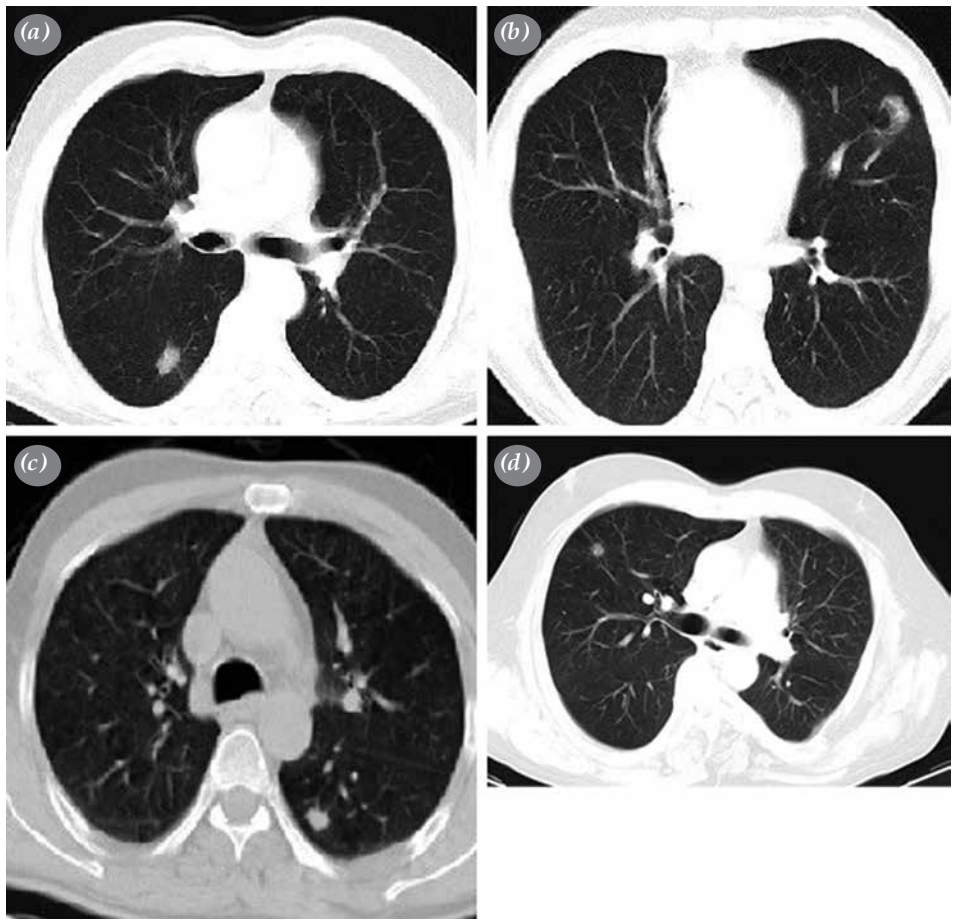

Figure 2. Computed tomography images of malignant lesions. **(a)** Right upper lobe adenocarcinoma. **(b, c)** Left upper lobe adenocarcinoma. **(d)** Right middle lobe squamous cell carcinoma.

Table 2. Pathological outcomes and localizations of lesions in lung

	MEC	Bronchiectasis	Hamartoma	Aspergilloma	Sequestration	AVM	Carcinoid	Squamouse	Small cell	Adenocarcinoma	Adenosquamous
Right											
Upper lobe						1		2		5	1
Middle lobe	1	7				1				1	
Lower lobe		6	1		2	1	1	1	1	6	
Lower lobe + middle lobe										1	
Upper lobe + middle lobe										1	
Left											
Upper lobe							1	3		4	
Lower lobe		11					2	1		8	
Lingula		2									
Lingula + lower lobe		2		1							
Lingula protective upper lobe										1	
Total	1	28	1	1	2	3	4	7	1	27	1

MEC: Mucoepidermoid carcinoma; AVM: Arteriovenous malformation.

Mean duration of hospitalization was 5.66 days (range 3-13 days) in benign patients and 8.23 days (range 2-19 days) in patients with lung cancer. Mean size of tumor was 2.4 cm (range 1-6 cm) in lung cancer patients. The pathologic distribution of the malignant cases was shown in Table 2. The average number of node stations in dissected lymph nodes was 6.85. The final pathology revealed 37 patients with N_0, two patients with N_1 (peribronchial), and two patients with N_2 (subcarinal) disease. Thus, 27 patients were Stage 1a, 10 were Stage 1b, two were Stage 2a, and two were Stage 3a according to the seventh edition of The International Association for the Study of Lung Cancer staging.

Complications of VATS lobectomy in benign and malignant diseases were compared in Table 3. Fourteen patients had postoperative prolonged air leakage, which was treated with thoracotomy and primary repair in one patient and with pleurodesis in three patients. Secondary pleurocan catheter was applied to three patients, and the air leakage ended spontaneously in seven patients. One patient with bronchiectasis underwent revision VATS on the same day due to hematoma. Bleeding was caused by bronchial artery, which was ligated with clips. Chylothorax developed in one patient. Wound infection was not reported in any patient. One patient developed pneumonia that needed respiratory support. Acute respiratory distress syndrome (ARDS), cardiovascular, renal or cerebrovascular complications were not observed. One patient with prolonged air leakage underwent left lower lobectomy and lingulectomy for aspergilloma. He admitted to our clinic with pneumothorax 19 days after surgery and was treated by tube thoracostomy. Air leakage continued, while bronchoscopy showed a fistula. A revision was performed through thoracotomy, and opened stump on the staple line was seen. Fistula was primarily repaired and stump was covered with intercostal muscle flap. The revision operations due to complications were limited only to the first two years. However, incidence of prolonged air leakage had not changed in four years.

DISCUSSION

Endoscopic surgical operations show a gradual increase. The history of endoscopic procedures in world began with cystoscopy of urology, and was followed by pleural biopsies of thoracic surgery. In present time, complex procedures like lobectomy are performed successfully by endoscopic techniques. Day by day, more surgeons are attracted by the magic of endoscopic surgery and begin to perform these operations. Video-assisted thoracoscopic surgery

Table 3. Complications and duration of hospitalization for video-assisted thoracoscopic surgery lobectomy in benign and malignant diseases

Complications	Benign diseases			Malignant diseases			Overall		
	n	%	Median	n	%	Median	n	%	Median
Revision (with thoracotomy)	1	2.85					1	1.31	
Revision (with VATS)	1	2.85					1	1.31	
Pneumonia				1	2.43		1	1.31	
Respiratory failure				1	2.43		1	1.31	
Prolonged air leakage	8	22.8		6	14.63		14	18.42	
Chylothorax				1	2.43		1	1.31	
Length of hospital stay (day)			5.66			8.23			7.07
Total	35			41			76		

VATS: Video-assisted thoracoscopic surgery.

lobectomy can be used for the treatment of both malignant and benign thoracic diseases. Although endoscopic instruments gradually improved, it was not until 1992 that the first VATS lobectomy for lung cancer was performed. Despite significant seeding of such procedure in several thoracic units globally, the uptake was slow and frustrating. Many surgeons considered it complex and unsafe, being skeptic about its oncologic validity. The last decade has witnessed significant change of practice in many thoracic units with a new generation of thoracoscopic surgeons.[1,2]

The size of the tumor is a definite criterion for the VATS approach. Although there are a variety of measures related to what the maximum tumor diameter should be, McKenna and Houck[3] and Peterson and Hansen[4] stated that the largest tumor diameter should be 6 cm. In our study, mean mass diameter for lung cancer patients was 2.4 cm (range 1-6 cm).

A majority of reports have found that both tube thoracostomy and hospitalization durations for patients who underwent VATS lobectomy are shorter than or equal to patients who underwent thoracotomy.[5-7] A review comparing VATS and thoracotomy reported by Whitson[8] showed that VATS lobectomy had 4.2 days average duration of chest tube drainage and 8.3 days of hospitalization, while same durations were 5.7 and 13.3 days, respectively, for thoracotomy.

Such results favor VATS lobectomy in terms of less pain, earlier termination of chest tube, and earlier discharge. Chest tube is terminated earlier because the 200 mL per/day drainage criteria for thoracotomy is 300 mL for VATS.[9,10] In our series of VATS lobectomy, mean duration of hospitalization was 5.66 days (range 3-13 days) for benign cases and 8.23 days (range 2-19 days) for malignant cases (Table 3). As part of our clinical practice, for lobectomy performed by both VATS and thoracotomy, we wait until the drainage falls below 150 mL per/day to terminate tube thoracostomy, and the day after, we discharge the patient. In our clinic, 486 patients underwent anatomic resection with thoracotomy between January 2012 and June 2016. Of these, 114 had benign diseases while 372 had malignant diseases. Mean duration of hospitalization was 9.13 days (range 3-46 days) for benign patients and 10.58 days (range 3-50 days) for malignant patients, and mean duration of hospitalization was 10.26 days (range 3-50 days) in both benign and malignant patients. In VATS group, duration of hospitalization was shorter than thoracotomy group. Correlations between operation type and duration of hospitalization were p=0.0 for all patients, p=0.004 for patients with malignant diseases, and p=0.0 for patients with benign diseases.

Complications of VATS lobectomy were defined as thoracotomy requirement, bleeding, wound infection, pneumonia, respiratory failure, prolonged air leak, ARDS, cardiovascular complications, renal complications, or development of cerebrovascular incidents. Kirby's study[11] suggested that morbidity and complication rates of VATS lobectomy group are significantly lower compared to lobectomy with thoracotomy group (53% versus 24%, respectively). Whitson's report[12] showed lower mortality rates (31.2% versus 16.4%, respectively) in the VATS group. Also, many retrospective case series have reported that VATS lobectomy groups have lower complication rates compared to lobectomy with thoracotomy groups.[7,13,14] This may be due to less pain, less inflammation, less deterioration of the chest wall function, and less affected mobilization of secretion with VATS.[7] In VATS lobectomy series, the most common complication is prolonged air leakage.[3,15,16] In our study, 14 patients had postoperative prolonged air leakage, which was treated with thoracotomy and primary repair in one patient and with pleurodesis

in three patients. Secondary pleurocan catheter was applied to three patients, and the air leakage ended spontaneously in seven patients. One patient with prolonged air leakage underwent left lower lobectomy and lingulectomy for aspergilloma. In the patient with bronchial fistula, a 4.8 mm endoscopic bronchial stapling device was used. Since the tissue was fairly thick and partly calcified, the shooting mechanism of the stapling device was broken during application and a second stapler was used on the same region. Intraoperatively, it was confirmed that there was no air leakage through the bronchial stump. This case indicates that knifeless bronchial stapling devices used for open techniques should be used through VATS utility incision for fairly thick bronchi and for some chronic cases. Thus, we prefer these staplers and dissect the bronchi manually ever since.

If we spare one patient whose leakage was due to bronchial fistula, the other 13 patients had parenchymal air leakage. We think that the cause of the air leakage, particularly for incomplete fissures, is the damaged adjacent parenchyma during dissection of fissure to reach the arterial structures. We also know that once the artery has been found, fissure is spared by stapling devices, and no further damage may be caused. We did not use fibrous tissue sealants in our patients although we think that such sealants may be useful during dissection of the aforementioned region. Another point which should be kept in mind is the possible occasional traction of the remaining lobe(s) through the third port site with surgical tools, which may damage the parenchyma. For one such case, the tear was noticed and repaired intraoperatively.

Interestingly, VATS lobectomy and lobectomy with thoracotomy groups were reported to be similar in terms of the incidence of atrial fibrillation.[4,6,7] In the postoperative period, arrhythmia may be caused by mechanical effects of the cessation of pulmonary veins due to pulmonary resection, denervation or other neurohumoral factors besides the size of incision.[7] Therefore, there may not be any particular difference between the two groups in terms of cardiovascular complications, as in our series. In the literature, mortality rate has been reported to be 1% or less in both groups.[17,18] Therefore, we may state that VATS lobectomy may not carry any additional risk of mortality.

Of the 486 cases of thoracotomy resection in our clinic, postoperative complications were expansion fault in 37, prolonged air leakage in 26, chylothorax in three, empyema in three, and wound infection in four. Five patients with postoperative massive air leakage, three patients with hematoma, and one patient with chylothorax underwent rethoracotomy. One patient underwent VATS after thoracotomy resection because of postoperative hematoma. Postoperative mortality was seen in 10 patients in early onset, due to cardiac reasons in six patients and respiratory failure in four patients.

For cases that may become symptomatic rapidly, like those with primary or postoperative chylothorax or hemothorax, VATS may be superior to thoracotomy. VATS may also be superior to open techniques in the visualization of some hidden points just as the pleural sinuses and lateral chest wall. In our patient with hemothorax, there was no such condition; however, bleeding was controlled easily by VATS.

Chylothorax developed in one lung cancer patient who underwent right lower lobectomy and lymph node dissection with VATS. This patient's oral feeding was stopped and he was given nutritional support. In this case, the amount of drainage was minimal and we did not consider urgent surgery. No patients had cardiovascular, renal or cerebral complications.

Our study has some limitations. The number of thoracotomy patients was 486, whereas 76 had VATS; therefore, statistical insecurities may have appeared. The data collection and analysis in this study was performed retrospectively; there may be unknown confounding variables and natural selection bias.

In conclusion, video-assisted thoracoscopic surgery lobectomy is a safe thoracic procedure, which is used for both oncologic and non-oncologic diseases of the lung. Video-assisted thoracoscopic surgery may be performed by all thoracic surgeons experienced in open thoracic surgery. Thanks to the gained experiences, the rates of video-assisted thoracoscopic surgery lobectomy may improve in all centers.

Declaration of conflicting interests

The authors declared no conflicts of interest with respect to the authorship and/or publication of this article.

Funding

The authors received no financial support for the research and/or authorship of this article.

REFERENCES

1. Miller JI Jr. The present role and future considerations of video-assisted thoracoscopy in general thoracic surgery. Ann Thorac Surg 1993;56:804-6.
2. Begum S, Hansen HJ, Papagiannopoulos K. VATS anatomic lung resections-the European experience. J Thorac Dis 2014;6:203-10.

3. McKenna RJ Jr, Houck WV. New approaches to the minimally invasive treatment of lung cancer. Curr Opin Pulm Med 2005;11:282-6.
4. Petersen RH, Hansen HJ. Learning thoracoscopic lobectomy. Eur J Cardiothorac Surg 2010;37:516-20.
5. Swanson SJ, Herndon JE, D'Amico TA, Demmy TL, McKenna RJ Jr, Green MR, et al. Video-assisted thoracic surgery lobectomy: report of CALGB 39802--a prospective, multi-institution feasibility study. J Clin Oncol 2007;25:4993-7.
6. Scott WJ, Allen MS, Darling G, Meyers B, Decker PA, Putnam JB, et al. Video-assisted thoracic surgery versus open lobectomy for lung cancer: a secondary analysis of data from the American College of Surgeons Oncology Group Z0030 randomized clinical trial. J Thorac Cardiovasc Surg 2010;139:976-81.
7. Paul S, Altorki NK, Sheng S, Lee PC, Harpole DH, Onaitis MW, et al. Thoracoscopic lobectomy is associated with lower morbidity than open lobectomy: a propensity-matched analysis from the STS database. J Thorac Cardiovasc Surg 2010;139:366-78.
8. Whitson BA, Groth SS, Duval SJ, Swanson SJ, Maddaus MA. Surgery for early-stage non-small cell lung cancer: a systematic review of the video-assisted thoracoscopic surgery versus thoracotomy approaches to lobectomy. Ann Thorac Surg 2008;86:2008-16.
9. McKenna RJ Jr, Mahtabifard A, Pickens A, Kusuanco D, Fuller CB. Fast-tracking after video-assisted thoracoscopic surgery lobectomy, segmentectomy, and pneumonectomy. Ann Thorac Surg 2007;84:1663-7.
10. Baumann MH. What size chest tube? What drainage system is ideal? And other chest tube management questions. Curr Opin Pulm Med 2003;9:276-81.
11. Kirby TJ, Mack MJ, Landreneau RJ, Rice TW. Lobectomy--video-assisted thoracic surgery versus muscle-sparing thoracotomy. A randomized trial. J Thorac Cardiovasc Surg 1995;109:997-1001.
12. Whitson BA, Groth SS, Duval SJ, Swanson SJ, Maddaus MA. Surgery for early-stage non-small cell lung cancer: a systematic review of the video-assisted thoracoscopic surgery versus thoracotomy approaches to lobectomy. Ann Thorac Surg 2008;86:2008-16.
13. Villamizar NR, Darrabie MD, Burfeind WR, Petersen RP, Onaitis MW, Toloza E, et al. Thoracoscopic lobectomy is associated with lower morbidity compared with thoracotomy. J Thorac Cardiovasc Surg 2009;138:419-25.
14. Flores RM, Park BJ, Dycoco J, Aronova A, Hirth Y, Rizk NP, et al. Lobectomy by video-assisted thoracic surgery (VATS) versus thoracotomy for lung cancer. J Thorac Cardiovasc Surg 2009;138:11-8.
15. Rocco G, Internullo E, Cassivi SD, Van Raemdonck D, Ferguson MK. The variability of practice in minimally invasive thoracic surgery for pulmonary resections. Thorac Surg Clin 2008;18:235-47.
16. Toker A. Videotorakoskopi: Yıllar içinde neler değişti? Videothoracoscopy: what has changed through the years? Turkish J Thorac Cardiovasc Surg 2007;15:90-6.
17. Casali G, Walker WS. Video-assisted thoracic surgery lobectomy: can we afford it? Eur J Cardiothorac Surg 2009;35:423-8.
18. Sugiura H, Morikawa T, Kaji M, Sasamura Y, Kondo S, Katoh H. Long-term benefits for the quality of life after video-assisted thoracoscopic lobectomy in patients with lung cancer. Surg Laparosc Endosc Percutan Tech 1999;9:403-8.