Journal of Neurology, Neurosurgery, and Psychiatry 1991;54:226–229

Occidental type cerebromuscular dystrophy: a report of eleven cases

Haluk Topaloğlu, Kalbiye Yalaz, Yavuz Renda, Melda Çağlar, Safiye Göğüs, Gulsev Kale, Kıvılcım Gücüyener, Gülay Nurlu

Abstract

Occidental type cerebromuscular dystrophy (OCMD) forms a substantial distinct group within congenital muscular dystrophy (CMD). These patients invariably present with amyotrophy, multiple joint contractures, facial muscle involvement, normal or nearly normal intelligence, leukodystrophic appearance on CT scan, and dystrophic changes in muscle.

Congenital muscular dystrophy (CMD) is a unique type of muscular disorder characterised by probable autosomal recessive inheritance, early onset hypotonia, joint contractures, dystrophic changes in muscle and slowly progressive course. Clinical presentation are rather heterogenous. There are four separate entities within CMD. Classic occidental (type 1) CMD with a normal or subnormal intelligence, Fukuyama's CMD (FCMD) (type 2), the cerebro- ocular dysplasia- muscular dystrophy (COD-MD) syndrome and some uncategorised forms.[1-4] In the majority of cases intelligence is preserved, so the central nervous system is generally considered to be unaffected.[1 5] There is, however, increasing evidence that CNS involvement in CMD may be more common than previously recognised.[6-8] An intermediate form between type 1 and type 2 (Fukuyama's) CMD with early hypotonia, normal mental development and leukodystrophic appearance on CT scan has recently been suggested and named as "occidental type cerebromuscular dystrophy" (OCMD), because this form appears to be prevalent in the Western hemisphere.[9] In this study we report clinical and pathological findings of this particular form of CMD in 11 cases.

Methods

Hacettepe University Children's Hospital is one of the major referral centres in Turkey. A total of 23 patients were diagnosed with CMD between July 1988 and November 1989 in our muscle pathology laboratory. Among these, 11 fit the criteria for OCMD: muscle hypotonia and weakness from birth or early infancy leading to a delay in motor development, no evidence of mental retardation, that is, mental developmental or intelligence quotient being within the normal range; myopathic muscle pathology including variation in fibre size, interstitial fibrosis, adiposis, and occasional fibre necrosis and regeneration; leukodystrophic appearance on cerebral CT scan; and no clinical or morphological findings of a neuropathic process. To assess mental development, the Bayley test and the Stanford-Binet test were given to those under three years of age and above five years of age, respectively.

Muscle biopsy specimens were taken from the gastrocnemius in all cases. The specimens were frozen in isopentane cooled in liquid nitrogen. Six micron serial cryostat sections were stained with haematoxylin and eosin, and modified Gomori trichrome. A battery of histochemical stains including NADH-tetrazolium reductase (NADH-TR), periodic acid Schiff and oil-red-O, were also used.

Results

CLINICAL OBSERVATIONS

The clinical histories of the 11 patients, aged from 10 months to 12 years (at initial evaluation), are summarised in table 1. Parental consanguinity was present in eight cases, being first cousins in seven and second cousins in one. One patient had an affected twin (patient 5), and one other had a sibling with similar symptoms (patient 2). All patients featured with hypotonia at birth. None of the patients were microcephalic.

The following findings were present in all cases: delay in motor development; multiple joint stiffness at the elbows, hips, knees or ankles (either present at birth or had developed later, except patient 4 who is free of contractures so far); proximal muscle weakness; and facial muscle involvement (fig 1, 2). Seven patients were areflexic. None of the cases had achieved independent working at the time of examination or follow ups. All patients were very slender in stature. Muscle hypertrophy was not present. Cardiac evaluation, which included chest radiograph, EKG and cardiac echogram, was normal in all patients.

The creatine kinase (CK) level was mild to moderately elevated in nine patients and normal in the remaining two. Electromyography (EMG) was myogenic in eight patients and normal in three. Motor nerve conduction velocity was within normal limits. All patients showed marked white matter hyperlucency with or without ventricular dilation (plus cortical atrophy in some) on cerebral CT scan (figs 3, 4). All patients had normal mental

Hacettepe University Children's Hospital, Ankara, Turkey
Department of Pediatric Neurology
H Topaloğlu
K Yalaz
Y Renda
K Gücüyener

Department of Pathology
M Cağlar
S Göğüs,
G Kale

Department of Electrophysiology
G Nurlu

Correspondence to:
Dr Topaloğlu, Department of Pediatric Neurology, Hacettepe Children's Hospital, 06100 Ankara, Turkey

Received 8 January 1990 and in final revised form 17 July 1990.
Accepted 23 July 1990

Table 1 Clinical findings

Case	*1*	*2*	*3*	*4*	*5*	*6*	*7*	*8*	*9*	*10*	*11*
Sex	*F*	*F*	*M*	*M*	*M*	*M*	*M*	*F*	*F*	*M*	*M*
Age at onset	at birth	at birth	at birth	at birth	at birth	at birth	at birth	at birth	at birth	at birth	at birth
Family history	—	one sib affected	—	—	two twin sibs affected	—	—	—	—	—	—
Head circumference	50 p	75 p	50 p	30 p	25 p	25 p	25 p	60 p	50 p	90 p	50 p
Prenatal consanguinity	first cousins	first cousins	—	—	second cousins	first cousins	first cousins	first cousins	first cousins	—	first cousins
Joint stiffness	+	+	+	−	+	+	+	+	+	+	+
DQ or IQ	86	90	83	83	82	84	93	83	85	86	79
Maximal motor ability	sits w support	stands w support	sits w/o support	stands w support	sits w/o support	stands w support	sits w/o support	sits w/o support	sits w/o support	sits w support	sits w/o support
Facial muscle involvement	+	+	+	+	+	+	+	+	+	+	+
CK	617 (N. < 240)	54 (N. < 191)	1514 (N. < 191)	32 (N. < 12)	12 (N. < 12)	931 (N. < 191)	2803 (N. < 191)	452 (N. < 191)	436 (N. < 191)	5052 (N. < 191)	339 (N. < 191)
EMG	myogenic	myogenic	myogenic	myogenic	N	myogenic	N	myogenic	myogenic	myogenic	N
CT scan											
WMHL	+	+	+	+	+	+	+	+	+	+	+
CA	+	+	−	+	+	+	−	+	+	−	−
Age at CK and CT	3 yr	12 yr	12 mo	12 mo	10 mo	5 yr	18 mo	3 yr	18 mo	19 mo	11 mo
Age at final follow up	4 yr	12½ yr	22 mo	2½ yr	16 mo	6½ yr	27 mo	4½ yr	24 mo	28 mo	2 yr
Clinical course	non-prog	non-prog	non-prog	non-prog	non-prog	non-prog	non-prog	non-prog	non-prog	non-prog	non-prog

M = male, F = female, (−) = absent, (+) = present, N = normal, w = with, w/o = without, CK = creatine kinase, EMG = electromyogram, WMHL = white matter hyperlucency, CA = cortical atrophy.

developmental milestones and developmental or intelligence quotients.

MUSCLE BIOPSY FINDINGS

The histopathological data are summarised in table 2. Most specimens exhibited marked variation in fibre size and evident endomysial fibrosis. Various degrees of adipose tissue replacement was detected in all patients. Moderate fibre atrophy and mild necrosis with regeneration was frequently encountered (figs 5, 6). Central nuclei was common. Mild focal inflammation was present in two cases. Muscle spindles and intramuscular nerves appeared normal. Targetoid/core fibres were not present. No ragged red fibre or nemaline body was identified on modified Gomori trichrome staining. There was no evidence of type grouping or group atrophy on histochemical staining.

Discussion

The aetiology and pathogenesis of CMD remains unclear. Various forms of CMD may be associated with more or less marked disorders in cerebral development.[7 10 11] A theory of intrauterine viral infection has been proposed, but it is not supported by virological or serological evidence.[2] There may also be the

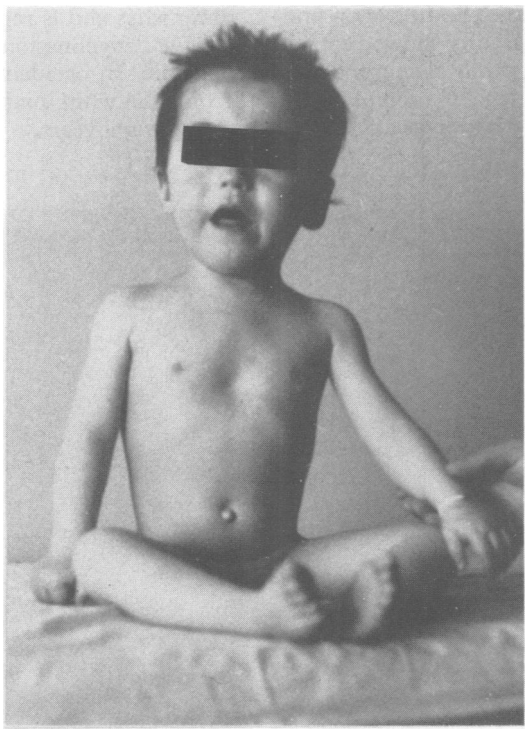

Figure 1 Twelve month old boy (case 3). Macrocephalic appearance, facial muscle involvement, amytrophy, bilateral contractures at the hips, knees and ankles. DQ 83.

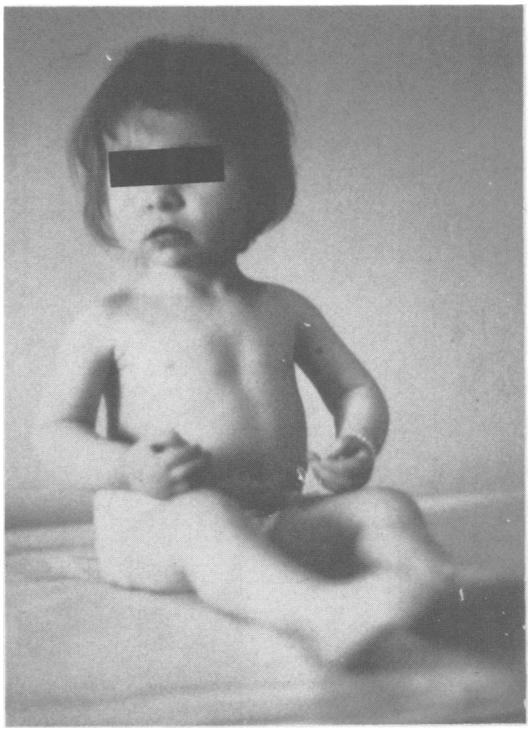

Figure 2 Eighteen month old girl (case 9). Macrocephalic appearance, facial weakness, amytrophy, bilateral contractures at the elbows, wrists and ankles. DQ 85.

Table 2 Histopathological findings

Case	1	2	3	4	5	6	7	8	9	10	11
Adiposis	++++	++++	++++	+++	++	+++	+++	++	++	+++	+++
Variation in fibre size	++	++	++	+	+	++	++	++	++	+	++
Fibrosis	+++	+++	++	+	+	+++	++	+	+++	+	++
Nuclear centralisation	+	−	+	−	−	+	+	−	+	+	−
Fibre atrophy	++	++	++	+	+	++	++	++	+	++	+
Necrosis	+	−	+	+	+	+	−	−	+	+	−
Inflammation	+	−	−	−	−	++	−	−	−	+	−
Age at biopsy	3 yr	12 yr	12 mo	12 mo	10 mo	5 yr	18 mo	3 yr	18 mo	19 mo	11 mo

Scale: (−) = absent, (+) = mild, (++) = moderate, (+++) = strong, (++++) = intense.

role of prolonged intervention of teratogenic factors.[12] An autosomal recessive mode of inheritance has been documented in the vast majority of cases.[5] A history of parental consanguinity was present in eight of our cases, suggesting autosomal recessive transmission.

The muscle biopsy findings in our patients were consistent with typical features of: diffuse endo-perimysial fibrosis, increased numbers of atrophic fibres, marked increase in fatty tissue and the absence of neuropathic properties. These findings are quite different from those seen in congenital non-progressive myopathies by the absence of cytoarchitectural changes peculiar to them.

In some cases of classic occidental type CMD (type 1), cerebral CT scan abnormalities have been documented.[7-9 13-15] This finding shows a considerable amount of overlap in clinical presentations of CMD patients. These patients are distinguished by amyotrophy, multiple joint contractures, involvement of the facial musculature, and some dysmorphic features; long and thin face, abnormalities of jaw articulation and high arched palate.[9 16] Intelligence may be normal or slightly lowered. All these patients have marked white matter hypodensity on CT scan. The necropsy findings of one case in the literature showed cortical areas of micropolygyria, cerebral neuronal loss, heterotopic nerve cells, degeneration of myelin sheath and cerebellar hypoplasia.[17] These patients form a sub-group within CMD. Our group of patients belong to this interesting type of CMD. Invariably, our patients had macrocephalic appearance (though not true macrocephaly), facial muscle involvement, multiple joint contractures and normal mental development. Their CT scans are very similar; marked white matter hypodensity with or without ventricular dilation and cortical atrophy in some.

In Japan type 2 Fukuyama's CMD seems to be one of the most frequent causes of the floppy infant syndrome,[2] whereas outside Japan the association of CMD with CNS involvement and mental retardation is very rare, and only a few cases have been reported.[18 19] Type 2 CMD has even been reported in Japanese infants conceived and born outside Japan.[20] The major changes in the CNS of type 2 CMD patients represent an arrest in the migration and differentiation of neurons early in the course of fetal development. This defect is expressed as microcephaly, polymicrogyria, pachygyria and heterotopias.[21] The most striking change, prominent white matter hyperlucency, is usually seen at about one years of age in type 2 CMD. As the child grows older, hyperlucency diminishes and is replaced by normalisation.[22] Delayed myelination processing may be responsible. In occidental type cerebromuscular group the white matter hyperlucency persists after several years.[7]

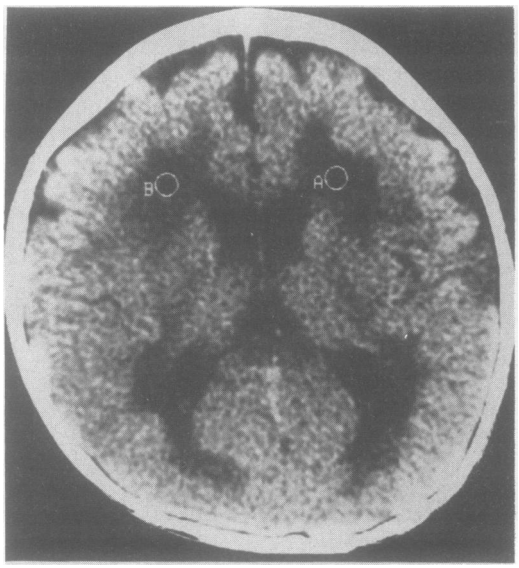

Figure 3 CT scan (case 3). Cortical atrophy and marked white matter hyperlucency. Ventricular dilation.

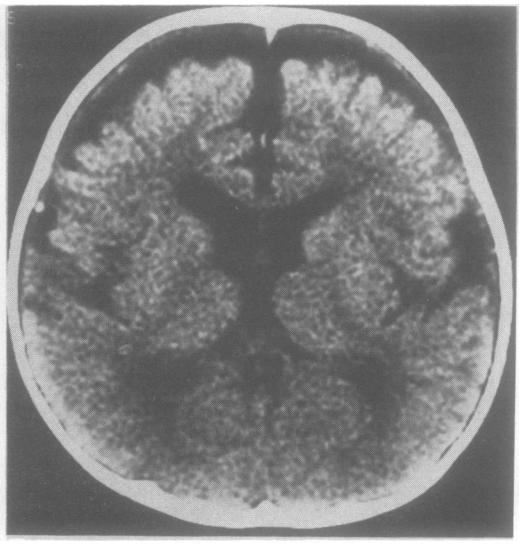

Figure 4 CT scan (case 9). Severe cortical atrophy, marked white matter hyperlucency and ventricular dilation.

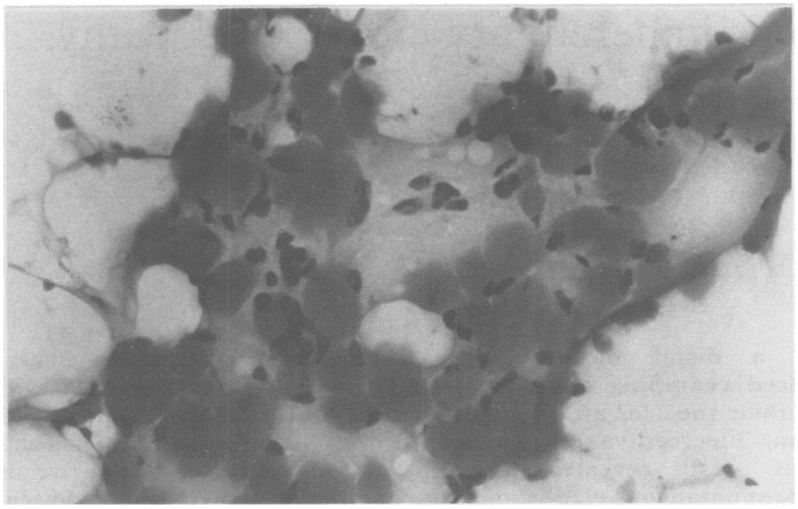

Figure 5 Muscle biopsy (case 3). Variation in fibre size, severe fibrosis, intense adiposis. HE × 200.

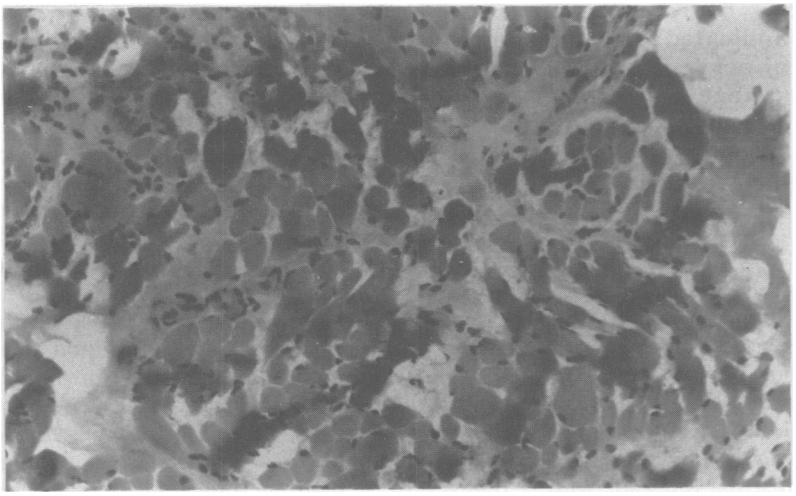

Figure 6 Muscle biopsy (case 9). Variation in fibre size, moderate fibrosis, mild adiposis, scattered degenerating fibres. HE × 200.

We believe that our group of patients with their clinical features and CT scan changes may form a sub-group within CMD. Patients of this defined particular type should be regarded as a distinct entity. On the other hand, not all cases featuring the clinical findings we have previously mentioned have abnormal CT scans. Here emerges the issue of marked heterogeniety of CMD—some cases may only present partial features.

We have called this form "occidental type cerebromuscular dystrophy,[9] but this is open to discussion. Some observations reported as type 2 CMD, even in Japan, may correspond to the same disease.[16] Further pathological and follow up studies will be necessary for clarification.

This study was supported by a grant from the Turkish Child Neurology Association.

1 McMenamin JB, Becker LE, Murphy EG. Congenital muscular dystrophy: A clinicopathological report of 24 cases. *J Pediatr* 1982;**100**:692–7.
2 Fukuyama Y, Osawa M, Suzuki H. Congenital progressive dystrophy of the Fukuyama type. Clinical, genetic and pathological considerations. *Brain Dev* (Tokyo) 1981;**3**: 1–29.
3 Dambska M, Wisniewski K, Sher J. Cerebro-oculo-muscular syndromes: A variant of Fukuyama congenital muscular dystrophy. *Clin Neuropathol* 1982;**25**:93–8.
4 Goebel HH, Fidzianska A, Lenard HG, Osse G, Hori A. A morphological study of non-Japanese congenital mucular dystrophy associated with cerebral lesions. *Brain Dev* (Tokyo) 1983;5:292–301.
5 Donner M, Rapola J, Somer H. Congenital muscular dystrophy. A clinico-pathological and follow up of 15 patients. *Neuropediatrie* 1975;**6**:239–58.
6 Echenne B, Pages M, Marty-Double C. Congenital muscular dystrophy with cerebral white matter spongiosis. *Brain Dev* 1984;**6**:491–5.
7 Echenne B, Arthuis M, Billard C, *et al*. Congenital muscular dystrophy and cerebral CT scan anomalies. *J Neurol Sci* 1986;75:7–22.
8 Topaloglu H, Yalaz K, Kale G, Ergin M. Congenital muscular dystrophy with cerebral involvement. Report of a case of occidental type cerebromuscular dystrophy *Neuropediatrics* 1990;**21**:53–4.
9 Castro-Gago M, Pena-Guitian J. Congenital muscular dystrophy of a non-Fukuyama type with characteristic CT images (letter). *Brain Dev* (Tokyo) 1988;**10**:60.
10 Sarnat HB. Does the human fetal brain influence muscle development? *Can J Neurol Sci* 1985;**12**:111–20.
11 Sarnat HB. Cerebral dysgenesis and their influence on fetal muscle development. *Brain Dev* (Tokyo) 1986;**8**:494–9.
12 Hansson D, Kristensson K, Lycke E, Solymar L, Sourander P. Generalised myopathy and cerebral malformations possibly related to an enteroviral infection. *Acta Pediatr Scand* 1975;**64**:881–5.
13 Nogen AG. Congenital muscular disease and abnormal findings on computerised tomography. *Dev Med Child Neurol* 1980;**22**:658–63.
14 Gobernado JM, Gimeno A. Changes in cerebral white matter in two cases of congenital muscular dystrophy. *Pediat Radiol* 1982;**12**:201.
15 Castro-Gago M, Diaz-Cardama I, Monasterio L, Fuster M, Perez-Becerra E, Pena J. Congenital muscular dystrophy with central nervous system involvement: an intermediate form? *The Annals (Houston)* 1985;7:5–12.
16 Echenne B. Congenital muscular dystrophy of a non-Fukuyama type (letter). *Brain Dev* 1988;**10**:397.
17 Egger J, Kendall BE, Erdohazi M, Lake BD, Wilson J, Brett EM. Involvement of the central nervous system in congenital muscular dystrophies. *Dev Med Child Neurol* 1983;**25**:32–42.
18 Martinelli P, Gabellini AS, Ciucci G, Govoni E, Vitali S, Gulli MR. Congenital muscular dystrophy with central nervous system involvement: Case report. *Eur Neurol* 1987;**26**:17–22.
19 Krijgsman JB, Barth PG, Stam FC, Slooff JL, Jaspar HHJ. Congenital muscular dystrophy and cerebral dysgenesis in a Dutch family. *Neuropediatrie* 1980;**11**:108–20.
20 McMenamin JB, Becker LE, Murphy EG. Fukuyama type congenital muscular dystrophy. *J Pediatr* 1982;**101**:580–2.
21 Kamoshita S, Konishi Y, Segawa M, Fukuyama Y. Congenital muscular dystrophy as a disease of the central nervous system. *Arch Neurol* 1976;**33**:513–6.
22 Yoshioka M, Saiwai S. Congenital muscular dystrophy (Fukuyama type)—Changes in the white matter low density on CT. *Brain Dev* (Tokyo) 1988;**10**:41–4.