8 Lazarevic D, Pistorio A, Palmisani E *et al*. The PRINTO criteria for clinically inactive disease in juvenile dermatomyositis. Ann Rheum Dis 2013;72:686–93.

9 Sato S, Hoshino K, Satoh T *et al*. RNA helicase encoded by melanoma differentiation-associated gene 5 is a major autoantigen in patients with clinically amyopathic dermatomyositis: association with rapidly progressive interstitial lung disease. Arthritis Rheum 2009;60:2193–200.

10 R Core Team [online]. Vienna, Austria: R Foundation for Statistical Computing, 2012. http://www.R-project.org/ (3 June 2014, date last accessed).

11 Wood SN. Generalized additive models: an introduction with R. Boca Raton, FL, USA: Chapman & Hall/CRC, 2006.

12 Marhaug G, Shah V, Shroff R *et al*. Age-dependent inhibition of ectopic calcification: a possible role for fetuin-A and osteopontin in patients with juvenile dermatomyositis with calcinosis. Rheumatology 2008;47:1031–7.

Clinical vignette

Rheumatology 2014;53:2208
doi:10.1093/rheumatology/keu342
Advance Access publication 3 September 2014

Ultrasonographic diagnosis of posterior interosseous nerve entrapment due to ganglion cyst in a patient with rheumatoid arthritis

A 74-year-old man with RA was seen due to weakness in the fingers of his right hand. He was receiving LEF (20 mg/day) and prednisolone (10 mg/day) treatment. Physical examination showed weakness (1/5) of the finger extensors (drop finger). Laboratory tests yielded increased CRP (6.4 mg/l, normal range 0–3), ESR (56 mm/h, normal range 0–20) and RF (192 IU/ml, normal range 0–14) levels. Electrodiagnostic evaluations were consistent with severe and partial neuropathy of the right posterior interosseous nerve (PIN). US imaging clearly demonstrated a ganglion cyst compressing the PIN (Fig. 1). As the ganglion could not be drained, US-guided intervention was finalized with intralesional betamethasone injection. The patient refused surgery, as his pain (but not weakness) subsided.

FIG. 1 US imaging (axial view) shows an anechoic (ganglion), lobulated cyst (asterisk) compressing the posterior interosseous nerve (white arrow) distal to its branching from the radial nerve at the level of the radial head (R)

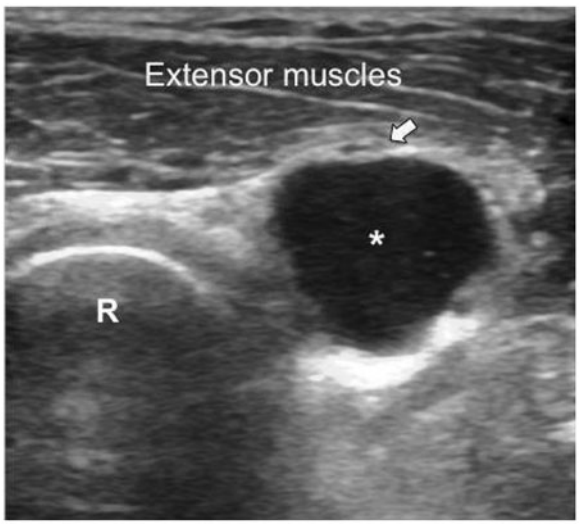

A ganglion or synovial cyst is a benign tumour-like mass that usually occurs near the joints or tendon sheaths, most commonly in the wrist and hand [1]. Although they are usually asymptomatic, they can manifest with various complaints, especially if they cause any sort of nerve entrapment [2]. Herein we show that US is a convenient imaging tool for illustrating not only the clinical conditions related to RA (rheumatoid nodules, synovial cysts, etc.) but also secondary/pertinent complications of such manifestations, i.e. peripheral nerve compression.

Funding: None.

Disclosure statement: The authors have declared no conflicts of interest.

Timur Ekiz[1], Gökhan Tuna Öztürk[1], Süha Yalçın[1], Gülay Kınıklı[2] and Levent Özçakar[3]

[1]Department of Physical Medicine and Rehabilitation, Ankara Physical Medicine and Rehabilitation Training and Research Hospital, [2]Department of Rheumatology, Ankara University Medical School and [3]Department of Physical Medicine and Rehabilitation, Hacettepe University Medical School, Ankara, Turkey.

Correspondence to: Timur Ekiz, Ankara Physical Medicine and Rehabilitation Training and Research Hospital, Department of Physical Medicine and Rehabilitation, Türkocağı Street No: 3, 06230 Ankara, Turkey.
E-mail: timurekiz@gmail.com

References

1 Kara M, Yalçin S, Tiftik T *et al*. Proximal median nerve entrapment caused by a distal biceps tendon cyst: an ultrasonographic diagnosis. Am J Phys Med Rehabil 2013;92:942–3.

2 Kara M, Tiftik T, Yetiş gin A *et al*. Ultrasound in the diagnosis and treatment of posterior interosseous nerve entrapment: a case report. Muscle Nerve 2012;45:299–300.

© The Author 2014. Published by Oxford University Press on behalf of the British Society for Rheumatology. All rights reserved. For Permissions, please email: journals.permissions@oup.com

Downloaded from https://academic.oup.com/rheumatology/article/53/12/2208/1804854 by Gazi Universitesi user on 02 October 2023