ORIGINAL ARTICLE

Veterinary Research Forum. 2020; 11 (4) 305 – 309
doi: 10.30466/vrf.2019.105229.2500
Journal Homepage: vrf.iranjournals.ir

Veterinary Research Forum

The effectiveness of *Teucrium chamaedrys* L. extracts on endometriotic implant regression in rat endometriosis model

Şule Özel[1], İpek Süntar[2], Nilüfer Ercan Gökay[1], Tuğba Taşkın Türkmenoğlu[3], Mürşide Ayşe Demırel[4]*

[1] Clinic of Gynecology, Zekai Tahir Burak Woman's Health Training and Research Hospital, University of Health Sciences, Ankara, Turkey; [2] Department of Pharmacognosy, Faculty of Pharmacy, Gazi University, Ankara, Turkey; [3] Department of Pathology, Diskapi Yildirim Beyazit Training and Research Hospital, Ankara, Turkey; [4] Laboratory Animals Care and Research Unit, Department of Pharmacology, Faculty of Pharmacy, Gazi University, Ankara, Turkey.

Article Info

Article history:

Received: 15 March 2019
Accepted: 06 July 2019
Available online: 15 December 2020

Keywords:

Endometriosis
Lamiaceae
Rat
Teucrium chamaedrys

Abstract

The aim of the present study was to investigate the therapeutic effects of *Teucrium chamaedrys* L. (Lamiaceae) in the experimentally induced endometriosis in rats. Endometrial tissue was implanted into the abdominal wall of thirty Sprague Dawley rats; the rats with endometriosis were randomized into five groups and treatment procedure was performed for three weeks. The treatment groups were orally treated with three different extracts of *Teucrium chamaedrys*. Buserelin acetate (20.00 mg) was given as a reference drug. Vehicle was administered alone to the control group. All rats were sacrified at the end of the experiment. The endometriotic implants were measured, intra-abdominal adhesions were scored and the tissue samples were histopathologically investigated. After the treatment procedure, the volumes of endometrial implant and adhesions were detected to be significantly decreased in the *T. chamaedrys* extracts treated groups compared to the control group. Therapeutic effect of the *T. chamaedrys* extracts could be attributed to the both nonpolar and polar secondary metabolites. The study conceived that the different polarity extracts of *T. chamaedrys* could be beneficial in the treatment of endometriosis.

© 2020 Urmia University. All rights reserved.

Introduction

Endometriosis is the growth of endometrial tissue outside the uterus. It is one of the most common gynecological diseases negatively affecting the quality of life.[1-3] It is known that endometriosis plays an important role in the fertility of both women and animals.[2,4,5] This disease affects approximately 6.00-10.00% of the women population.[6] Etiopathogenesis of this disorder is yet uncertain.[7] The diagnosis of endometriosis in the cow and mare with infertility is accomplished by endometrial biopsy.[4,8] In bitches and cats, endometriosis is a rare and sporadic disease. Generally, this disorder is accidentally discovered during the ovariohysterectomy procedure.[5,9,10] Previous studies have exhibited that ovarian endometriosis is associated with inadequate corpus luteum function.[11,12] Accordingly, spontaneous abortion was reported due to ovarian endometriosis in a bitch.[5] The patients with endometriosis are treated according to the symptoms and fertility needs.[7] Pharmacological, non-pharmacological, and surgical methods are treatment options for endometriosis. Most of the pharmacological methods cause pregnancy prevention due to their contraceptive action.[13] Moreover, available medical therapies mainly focus on treating the symptoms rather than curing the disease itself. These therapies cannot be employed for a long time owing to their severe secondary side effects.[14] Surgical approach may damage the ovarian reserve. Thus, there is a definite need to develop new drugs to provide specific and more efficient therapeutic options eliminating endometriotic lesions, preventing recurrences, and not interfering with the fertility potential.[15] New complementary therapies, perhaps combined with established medical and surgical therapies, could prevent the progression of the disease and improve fertility.

Despite the presence of drug medication and surgical methods, more recently natural remedies are gaining popularity among patients having such gynecological problems due to the unwanted effects of conventional

***Correspondence:**

Mürşide Ayşe Demırel. DVM, PhD
Laboratory Animals Care and Research Unit, Department of Pharmacology, Faculty of Pharmacy, Gazi University, Ankara, Turkey
E-mail: aysedemirel@gazi.edu.tr

This work is licensed under a Creative Commons Attribution-NonCommercial 4.0 International License which allows users to read, copy, distribute and make derivative works for non-commercial purposes from the material, as long as the author of the original work is cited properly.

remedies. Indeed, medicinal plants and their secondary metabolites could also serve as new sources of effective therapies in drug research and development studies. Medicinal plants that have been reported to be used for the treatment of gynecological ailments can be used as research material for this purpose, thereof. In ethnobotanical records, the flowering aerial parts of *Teucrium chamaedrys* L. (Lamiaceae), known with the English name of germander, were reported to be utilized for the treatment of inflammations, gastrointestinal problems, rheumatoid arthritis, wounds, and uterus infections.[16,17] This plant was also studied for its important phytochemical compounds such as diterpenoids, saponins, and flavonoids.[18,19]

The aim of this study was to evaluate the potential effect of a plant remedy, namely, *T. chamaedrys* in a surgical model of endometriosis in female rats.

Materials and Methods

Plant material. The flowering aerial parts of *T. chamaedrys* were collected in May 2018 from Şarkikaraağaç (Isparta, Turkey) and identified by Dr. Ufuk Ozbek from the Department of Biology, Faculty of Science, Gazi University, Ankara, Turkey. The voucher specimen was kept in the Herbarium of Faculty of Pharmacy, Gazi University, Ankara, Turkey (GUEF 3502).

Preparation of the plant extract. The plant material was dried, powdered (100 g), and successively extracted with *n*-hexane, ethyl acetate (EtOAc), and methanol (MeOH), respectively (2.00 L of each). The extracts were evaporated to be dried under reduced pressure and temperature to obtain 3.33 g *n*-hexane (3.33%), 3.32 g EtOAc (3.32%), and 15.75 g MeOH (15.75%) extracts.

***In vivo* experimental model.** Six-week-old female Sprague Dawley rats weighing 200-250 g were used for experimental induction of endometriosis with the method developed by Vernon and Wilson.[20] The present study was approved by the Experimental Animals Ethics Committee of Gazi University, Ankara, Turkey (G.U.ET-18.027). All experiments were performed under the ethical guidelines from the Ethics Commission on Animal Use, the National Institutes of Health Guidelines for the Care and Use of Laboratory Animals. The animals were housed in polysulfone cages at 21.00 - 24.00 ˚C, 40.00 - 45.00% humidity and light-controlled (12 hr light/12 hr dark) conditions at Laboratory Animals Breeding and Experimental Research Center, Faculty of Pharmacy, Gazi University, Ankara, Turkey and provided standard food and water *ad libitum.*

Experimental design and surgically induced rat endometriosis. Rats exhibiting regular estrous cycles by daily assessment of vaginal cytology were used in the experiment. Thirty rats were randomly divided into five groups consisting of six rats in each group as a control group, reference group, and three different polarity extracts treatment groups. Test materials were administered via oral gavage once daily throughout three weeks.

To induce endometriosis, the homologous uterine horn transplantation was performed. All rats were intraperitoneally anesthetized with xylazine hydrochloride (10.00 mg kg^{-1}; Ege Vet, Izmir, Turkey) and ketamine hydrochloride (50.00 mg kg^{-1}; Ege Vet). The rats were placed in the supine position and abdominal shaving and routine disinfection were provided. A midline vertical incision (2.00 cm) was created by the scalpel blade and the abdominal cavity was opened. After the removal of the right uterine horn, a 10.00 mm piece of resected uterine horn tissue was taken by microscissors. This piece of the uterine tissue was longitudinally opened and the myometrium layer was excised. Then, the excised endometrial tissue was sutured with USP 4-0 polyglactin (Orhan Boz, Ankara, Turkey) into the abdominal wall. The abdomen was closed with USP 3-0 polyglactin (Orhan Boz).

A second laparotomy was performed to determine the volumes of endometriotic implants and adhesion scores under the same anesthesia procedure after twenty-one days from the first operation. The implants volume was calculated by measuring the size of their length, width, and height. A formula (π / 6 × length × width × height) was used for calculation of the volume in which the value of π is 3.14.[21] Intra-abdominal adhesion scores were determined according to Blauer and Collins's scoring system as follows: 0 = no adhesion, 1 = thin, easily separable adhesions, 2 = thick adhesions limited to one area, 3 = thick and widespread adhesions and 4 = thick and widespread adhesions plus adhesions of viscera to the anterior/or posterior of the abdominal wall.[22] Subsequently, the abdominal wall and skin were closed with suture material.

Treatment procedure. Test materials were applied after two days from the second operation throughout twenty-one days. Sodium carboxymethylcellulose (CMC) in distilled water (5.00%; 2.00 mL per rat, daily) was given by oral gavage to the control group animals (n = 6). Gonadotropin-releasing hormone (buserelin acetate, 20.00 mg per rat, weekly) was subcutaneously administered to the reference group animals (n = 6). The *n*-hexane, EtOAc and MeOH extracts prepared in 5.00% CMC solution were administered by oral gavage at 100 mg kg^{-1} doses (2.00 mL per rat, daily; n = 6, each extract group). The estrous cycle was assessed every 4-5 days by vaginal cytology during the treatment procedure.

Termination of the experimental procedure. All rats were sacrificed by exsanguination under deep general anesthesia at the end of study. The volume of endometriotic implants and adhesion scores were again assessed and compared with the results obtained in the second operation. Afterward, the endometrotic implants were resected for histopathological evaluation.

Histopathological examination. The tissues were fixed in a 10.00% buffered formaldehyde solution for at least six hr. The samples were kept on overnight using an automatic tissue processor and embedded in paraffin. Afterward, tissue samples were cut into 4.00 µm thick sections using a microtome and stained with Hematoxylin and Eosin (H & E). All samples were examined under a light microscope for the presence of endometriotic gland, hemosiderin-laden macrophages, and neovascularization.

Statistical analysis. The one-way analysis of variance was used to determine statistically significant differences between groups. These differences were considered significant when $p \leq 0.05$.

Results

Following the second laparotomy, vascularized and cystic structures of the implants were determined (Fig. 1A). Intra-abdominal adhesions were macroscopically scored (Table 1) and volumes of implants were sized (Table 2). After the treatment procedure, adhesions were detected in the control group with a score number of 2.37 ± 0.54. It was observed that the adhesion formations significantly decreased in EtOAc (score: 0.56 ± 0.48) and MeOH (score: 0.76 ± 0.21) extracts groups compared to the control group (Table 1). At the end of the experimental procedure, the areas of endometriotic implants were sized. Implant volumes were significantly reduced in all treatment groups compared to control group (Fig. 1B).

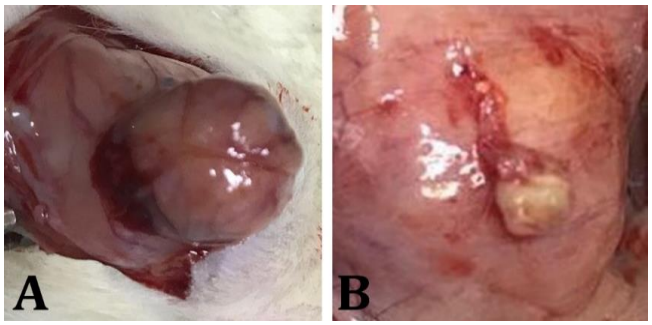

Fig. 1. A) Implanted endometriotic lesion 21 days after endometriosis induction; **B)** The regression of endometrial foci.

Table 1. Intra-abdominal adhesion scores of the endometriotic implants in all groups before (in the second operation) and after treatment (at the end of the experiment). Data are presented as mean ± SEM.

Groups	Pre-treatment	Post-treatment
Control	2.24 ± 0.61	2.37 ± 0.54
Buserelin acetate	2.17 ± 0.60	2.50 ± 0.62
***n*-hexane extract**	2.23 ± 0.42	1.27 ± 0.56
EtOAc extract	2.17 ± 0.40	0.56 ± 0.48*
MeOH extract	2.27 ± 0.45	0.76 ± 0.21*

EtOAc: Ethyl acetate, MeOH: Methanol

* Asterisk indicates a significant difference compared to the pre-treatment value at $p < 0.05$.

Table 2. Comparison of the pre-treatment and post-treatment endometriotic implant volume (mm^3). Data are presented as mean ± SEM.

Groups	Pre-treatment	Post-treatment
Control	2.31 ± 0.29	2.47 ± 0.30
Buserelin acetate	2.38 ± 0.56	0.52 ± 0.19*
***n*-hexane extract**	2.26 ± 0.23	0.23 ± 0.18*
EtOAc extract	2.36 ± 0.16	0.18 ± 0.07*
MeOH extract	2.25 ± 0.53	0.02 ± 0.01*

EtOAc: Ethyl acetate, MeOH: Methanol

* Asterisk indicates a significant difference compared to the pre-treatment value at $p < 0.01$.

The superficial or profound invasions between the muscle fibers in the implantation sites were histopathologically observed. Endometriotic lesions were detected in the control group. The H & E staining showed cystic lesions with well visualized endometrial epithelium in control group. In treatment groups, neovascularization, focal small endometriotic glands, and occasional hemosiderin-laden macrophages were seen only in a few rats. In the reference group, atrophic endometrial epithelium lining cyst wall with surrounding hemosiderin-laden macrophages was observed (Fig. 3).

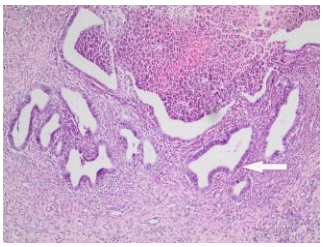

Fig. 2. Histological appearance of the endometriotic gland (arrow) in the control group (H & E, 100×).

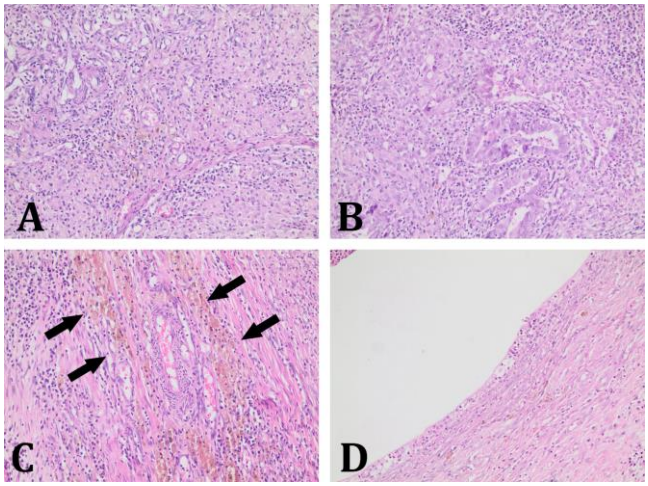

Fig. 3. A) Only neovascularization and a few hemosiderin-laden macrophages are seen in *T. chamaedrys n*-hexane extract group, without any endometriotic glands; **B)** Regression of endometrial glands in *T. chamaedrys* methanol extract group; **C)** Hemosiderin-laden macrophages (arrows) without any endometrial tissue in *T. chamaedrys* ethyl acetate extract group; and **D)** Atrophic endometrial epithelium lining cyst wall with surrounding hemosiderin-laden macrophages in buserelin acetate group (H & E, 200×).

Before the experiment, regular estrous cycles were detected for all rats in vaginal smear samples. After endometriosis induction, rats showed an irregular estrous cycle. While irregular estrous cycles continued in control group rats during the experimental procedure, the estrous cycle re-started in the treatment groups. This alteration was similar in all treatment groups.

Discussion

Feasibility studies are still carried out to find more efficient therapies with fewer side effects for the treatment of endometriosis. Lowering the estrogen level is one of the therapeutic goals in endometriosis cases, since, it is known that estrogen has a strong proliferative effect in endometrial cells. Lots of therapeutic agents used in endometriosis cause various side effects. In current therapy of endometriosis, GnRH agonists are preferred owing to their significant estrogen level reducing effect. The use of agents such as GnRH agonists and aromatase inhibitors reduces bone mass by about 2.00-5.00% for six months. Therefore, the new treatment options such as anti-inflammatory drugs, statins, selective estrogen modulators, anti-angiogenic and anti-adhesive agents have been the subject of recent researches.[23-25]

In drug discovery and development, traditional medicine is considered a good source of information that can provide a hypothetical basis for experimental studies. Since there is a well-documented folk remedy knowledge in ethnobotany literature. Reliance on herbal medicine is mainly due to the high cost of allopathic medicine and the inaccessibility of modern healthcare systems in rural areas. People living in remote areas also use plants for the treatment of several gynecological disorders such as menstrual problems, abortion, leucorrhoea.[26] According to ethnobotanical reports, the flowering aerial parts of *T. chamaedrys* L., a Lamiaceae family plant, were reported to be used for the treatment of inflammatory diseases, gastrointestinal ailments, rheumatoid arthritis, wounds, and uterus infections.[16,17] The phytochemical studies on *T. chamaedrys* have revealed the presence of saponins, flavonoids, and several furane-containing neoclerodane diterpenoids as the secondary metabolites.[18,19] In the present study, we aimed to investigate the potential role of *T. chamaedrys* in surgically-induced endometriosis in female rats. The outcomes of this study have demonstrated that the EtOAc and MeOH extracts of *T. chamaedrys* reduced the intra-abdominal adhesion formation. Moreover, all of the extracts including *n*-hexane exhibited a significant reduction in the volume of endometrioma compared to the control group, which received no treatment. Besides, the effect of extracts was found to be higher than that of the reference group receiving buserelin acetate. Especially in terms of intra-abdominal adhesion scores, the extracts, particularly EtOAc, decreased the adhesion formation, which is an important finding regarding the fertility aspect. In a previous study, among the three plant materials tested, *T. chamaedrys* was found to be the richest in terms of polyphenolic compounds and it was the most powerful antioxidant and antimicrobial agent in *in vitro* studies.[27] Reportedly, the clinical effects of *T. polium* L., another *Teucrium* species, on the severity of primary dysmenorrhea were assessed in placebo-controlled study. The outcome of the study demonstrated that the use of *T. polium* during menstruation led to a decrease in the severity of dysmenorrhea without inducing any side effects.[28] Previous animal experiments have shown the formation of reactive epoxides from diterpenoid type compounds, which induce apoptosis in hepatocytes due to the permanent utilization of *T. Chamaedrys.*[29] Therefore, herein we also assessed the potentially toxic effects of extracts on the liver of rats. No damaging effect was recorded for the dosage of 100 mg kg^{-1}.

In the present study, all of the extracts displayed significant activity in decreasing the volumes of endometriotic implants and reducing the intra-abdominal adhesions, which means the secondary metabolites of nonpolar and polar features are both responsible for these activities. This directs us to evaluate the total extract's biological activity in our further studies to find out a possible synergistic effect.

The results of the present study suggest that different polarity extracts of *T. chamaedrys* L. (Lamiaceae) have beneficial effects on the treatment of endometriosis in rat. The volumes of endometriotic implants were detected to be decreased significantly in *T. chamaedrys* extracts treated groups. The macroscopic adhesion score was determined to be significantly lower in MeOH and EtOAc groups.

Acknowledgments

The authors are thankful to the staff of the Laboratory Animals Care and Research Unit, Faculty of Pharmacy, Gazi University (Ankara, Turkey).

Conflicts of interest

The authors declare no conflict of interest.

References

1. Leyland N, Casper R, Laberge P, et al. Endometriosis: diagnosis and management. J Obstet Gynaecol Can 2010;32(7 Suppl 2):S1-S32.
2. Dayangan Sayan C, Özakşit MG, Sarıkaya E, et al Serum interleukin-8, CA-125 levels, neutrophil-to-lymphocyte ratios, and combined markers in the diagnosis of endometriosis. Turk J Med Sci 2013;43: 417-423.

3. Măluțan AM, Drugan T, Ciortea R, et al. Endometriosis-associated changes in serum levels of interferons and chemokines. Turk J Med Sci 2017;47(1):115-122.
4. Moreira LLQ, de Carvalho ECQ, Caldas-Bussiere MC. Differential immunohistochemical expression of matrix metalloproteinase-2 and tissue inhibitor of metallo-proteinase-2 in cow uteri with adenomyosis during follicular phase. Vet Res Commun 2011; 35:261-269.
5. Demirel MA. A case of spontaneous abortion related to ovarian endometriosis in a Golden Retriever dog. Iran J Vet Res 2017;18(1):63-66.
6. Giudice LC, Kao LC. Endometriosis. Lancet 2004; 364(9447):1789–1799.
7. Arruda MS, Petta CA, Abrão MS, et al. Time elapsed from onset of symptoms to diagnosis of endometriosis in a cohort study of Brazilian women. Hum Reprod. 2003;18(4):756-759.
8. Schlafer DH. Equine endometrial biopsy: enhancement of clinical value by more extensive histopathology and application of new diagnostic techniques. Theriogenology 2007; 68(3):413-422.
9. Perez-Marin CC, Molina L, Dominguez JM, et al. Incidental finding of uterine adenomyosis in a bitch with reproductive disorders: a case report. Vet Med (Praha) 2008; 53(11):636-640.
10. Bulman-Fleming J. A rare case of uterine adenomyosis in a Siamese cat. Can Vet J 2008; 49(7):709-712.
11. Ayers JW, Birenbaum DL, Menon KM. Luteal phase dysfunction in endometriosis: elevated progesterone levels in peripheral and ovarian veins during the follicular phase. Fertil Steril 1987; 47(6): 925-929.
12. Pluchino N, Drakopoulos P, Wenger JM, et al. Endocrinology of pregnancy loss. In: Carp HJA (Ed). Recurrent pregnancy loss: Causes, controversies, and treatment. 2nd Ed. New York, USA: CRC Press 2014; 111-121.
13. Pfeifer S, Fritz M, Goldberg J, et al. Endometriosis and infertility: a committee opinion. Fertil Steril 2012; 98(3):591-598.
14. Rice VM. Conventional medical therapies for endometriosis. Ann N Y Acad Sci 2002; 955:343-352.
15. Ricci AG, Olivares CN, Bilotas MA, et al. Natural therapies assessment for the treatment of endometriosis. Hum Reprod 2013; 28:178-188.
16. Rader JI, Delmonte P, Trucksess MW. Recent studies on selected botanical dietary supplement ingredients. Anal Bioanal Chem 2007; 389(1):27-35.
17. Herrera S, Bruguera M. Hepatotoxicity induced by herbs and medicines used to induce weight loss [Spanish]. Gastroenterol Hepatol 2008;31(7):447-453.
18. Bedir E, Manyam R, Khan I.A. Neo-clerodane diterpenoids and phenylethanoid glycosides from Teucrium chamaedrys L. Phytochemistry 2003;63(8): 977-983.
19. Lin LZ, Harnly JM, Upton R. Comparison of the phenolic component profiles of skullcap (*Scutellaria lateriflora*) and germander (*Teucrium canadense* and *T. chamaedrys*), a potentially hepatotoxic adulterant. Phytochem Anal 2009;20(4):298-306.
20. Vernon MW, Wilson EA. Studies on the surgical induction of endometriosis in the rat. Fertil Steril 1985; 44(5):684-694.
21. Altintas D, Kokcu A, Tosun M, et al. Comparison of the effects of cetrorelix, a GnRH antagonist, and leuprolide, a GnRH agonist, on experimental endometriosis. J Obstet Gynaecol Res 2008;34(6):1014-1019.
22. Blauer KL, Collins RL. The effect of intraperitoneal progesterone on postoperative adhesion formation in rabbits. Fertil Steril.1988;49:144-149.
23. Taylor HS, Osteen KG, Bruner-Tran KL, et al. Novel therapies targeting endometriosis. Reprod Sci 2011;18(9):814-823.
24. Abbas MA, Taha MO, Disi AM, et al. Regression of endometrial implants treated with vitamin D3 in a rat model of endometriosis. Eur J Pharmacol 2013; 715(1-3):72-75.
25. Yildirim B, Guler T, Akbulut M, et al. 1-alpha,25-dihydroxyvitamin D3 regresses endometriotic implants in rats by inhibiting neovascularization and altering regulation of matrix metalloproteinase. Postgrad Med 2014;126(1):104-110.
26. Shinwari S, Ahmad M, Zhang G, et al. Medicinal plant diversity use for gynecological disorders among the rural communities of Northern Pakistan. Pak J Bot 2017; 49(5):1787-1799.
27. Vlase L, Benedec D, Hanganu D, et al. Evaluation of antioxidant and antimicrobial activities and phenolic profile for *Hyssopus officinalis, Ocimum basilicum* and *Teucrium chamaedrys.* Molecules 2014; 19(5): 5490-5507.
28. Abadian K, Keshavarz Z, Mojab F, et al. The biological effects of *Teucrium polium* on the severity of primary dysmenorrhea. J Appl Biotechnol Rep 2016; 3(3): 453-456.
29. Seeff L, Stickel F, Navarro VJ. Hepatotoxicity of herbals and dietary supplements. In, Kaplowitz N, DeLeve LD (Eds). Drug-induced liver disease. 3rd ed. Amsterdam, The Netherland: Elsevier 2013; 631-658.