AMERICAN ACADEMY OF OPHTHALMOLOGY®

Vitreopapillary Findings in Nonarteritic Ischemic Optic Neuropathy versus Healthy Eyes

A Clinical and OCT Comparison

Ahmet M. Hondur, MD,[1,2] Golnaz Moazami, MD,[1] Gozde Hondur, MD,[1,3] Tongalp H. Tezel, MD[1]

Purpose: To study the vitreopapillary interface in nonarteritic ischemic optic neuropathy (NAION) for features that may predispose to optic nerve perfusion defects.

Design: Case-control study.

Participants and Controls: Patients with NAION (study group) were compared with healthy non-NAION patients with crowded discs (control group I) and noncrowded optic discs (control group II).

Methods: The vitreopapillary interface was studied in 32 eyes with NAION using high-resolution OCT scans. Results were compared with 2 control groups consisting of age, sex, and refraction-matched non-NAION individuals with crowded optic discs (control group I: 31 eyes) and noncrowded optic discs (control group II: 32 eyes).

Main Outcome Measures: The incidence of total posterior vitreous detachment (PVD), vitreopapillary and vitreovascular attachments, and epipapillary membranes.

Results: The rate of PVD over the macula was similar between groups (NAION: 62.5%, control I: 61.3%, and control II: 65.6%, $P = 0.93$), whereas the posterior hyaloid remained attached to the crowded discs at a significantly higher rate (NAION: 81.2%, control I: 83.9% and control II: 43.7%, $P = 0.0005$). A higher rate of focal vitreopapillary attachments on crowded discs than on noncrowded discs was noted (NAION: 72.2%, crowded control I: 58.7%, and noncrowded control II: 19.1%, $P = 0.007$). Vitreovascular attachments (NAION: 68.8%, crowded control I: 3.2% vs. noncrowded control II: 6.3%, $P = 0.00001$) and dense epipapillary membranes were observed in NAION eyes.

Conclusions: Crowded discs may have stronger vitreopapillary attachments. A close relationship of these attachments with optic nerve vessels may lead to the transmission of strong tractional forces by a syneretic vitreous gel, especially after macular PVD. This transduced mechanical force may contort the vessel wall and disrupt the blood flow in NAION.

Financial Disclosure(s): Proprietary or commercial disclosure may be found after the references in the Footnotes and Disclosures at the end of this article. *Ophthalmology 2025;132:327-334 © 2024 by the American Academy of Ophthalmology*

Nonarteritic ischemic optic neuropathy (NAION) is the most common acute optic nerve disease of adulthood, with an annual incidence of 0.5−1/10 000.[1,2] The most common presentation involves a sudden monocular visual loss, disc edema, afferent pupil defect, and a typically inferior altitudinal visual field defect.[1−3]

Despite being relatively common and presumed to be ischemic, it has not been possible to demonstrate a primary vasculopathy histopathologically. In addition, clinical findings during acute NAION have not been supportive of an ischemic pathology.[3] However, the similarity of its clinical features to arteritic ischemic optic neuropathy, which is a vasculopathic disease, has led clinicians to continue suspecting a vascular etiology for NAION.[4] Thus, the understanding of the pathogenesis of NAION has remained incomplete, although there is a widespread assumption that microvascular ischemia is the final denominator in the pathogenesis of the disease. However, the best-known feature associated with NAION is a crowded optic disc with a small (≤ 0.2) cup-to-disc ratio, named a "disc at risk."[5] However, because crowding of nerve fibers cannot cause vascular occlusion or ischemia, this structural feature has been proposed to be a marker of another unidentified factor leading to ischemia at the disc.[6]

Besides an editorial,[3] a few studies have reported results that implied the association of vitreopapillary traction with NAION.[7,8] However, there have been reports against any direct role of tractional forces at the optic disc in the disease pathogenesis.[9,10] Therefore, we aimed to study the vitreopapillary findings in eyes with NAION in

© 2024 by the American Academy of Ophthalmology
Published by Elsevier Inc.
https://doi.org/10.1016/j.ophtha.2024.09.008
ISSN 0161-6420/24

comparison with age-matched control eyes. Clinical findings were correlated to spectral-domain OCT (SD-OCT) findings.

Methods

This retrospective case analysis was approved and monitored by the Institutional Review Board of Columbia University, Vagelos College of Physicians and Surgeons, and conducted according to the principles of the Declaration of Helsinki. A waiver for informed consent was given by the Institutional Review Board because of the retrospective design of the study.

The study group consisted of patients diagnosed with NAION who had OCT scans of the vitreopapillary interface. Information about patients' medical and ocular history, ocular examination, and ancillary testing was obtained from patient charts. Patients' age, gender, systemic disease, medications, and relevant clinical data, including refractive error, lens status, and detailed ophthalmoscopy findings, were extracted from the charts. OCT scans of the optic disc and macula, fundus photographs, and visual field examinations were also reviewed.

The inclusion criteria for NAION cases comprised an age $>$ 40 years, presentation with the typical symptoms and signs of the disease, including an acute and painless monocular visual loss, a swollen disc on ophthalmoscopy, a relative afferent pupillary defect (unless a previous optic neuropathy was known in the other eye), 0.2 or less cup-to-disc ratio, and a visual field defect compatible with NAION. Other optic disc diseases such as glaucoma, optic nerve pit or coloboma, arteritic ischemic optic neuropathy, traumatic, toxic or compressive optic neuropathies, elevated intracranial pressure, optic disc drusen, optic neuritis, neuroretinitis, and vasculitis or coexisting retinal pathologies were excluded from this study. Erythrocyte sedimentation rate and C-reactive protein tests had been performed to exclude arteritic ischemic optic neuropathy in all cases. In patients with bilateral NAION, 1 eye was included. In all NAION eyes, the OCT images after the disc swelling resolution were compared with the healthy control eyes.

As for control, 2 age-matched and refraction-matched groups were established. Only 1 eye of the control subjects was included in the study. The controls were randomly selected from the same neuro-ophthalmology clinic and consisted of individuals screened for other neuroophthalmological disorders. Thus, they had OCT scans of the vitreopapillary interface and were found to be healthy. The first control arm consisted of randomly selected healthy eyes with crowded optic discs (cup/disc ratio of $\leq$ 0.2) without a history or any clinical sign of NAION (control group I). The second control group consisted of randomly selected eyes with noncrowded (cup/disc ratio of $\geq$ 0.3) healthy optic discs (control group II). The inclusion criteria for healthy control group subjects were age $>$ 40 years, a best-corrected visual acuity of 20/30 or better, a spherical equivalent refractive error between +5 and −5 diopters (D), astigmatism $<$ 3 D, no media opacity that would interfere with fundus viewing and imaging, no retinal or optic nerve head pathology, an intraocular pressure $<$ 21 mmHg, and the absence of glaucomatous damage in peripapillary retinal nerve fiber layer thickness analysis with the Cirrus SD-OCT (Carl Zeiss Meditec) or the Spectralis SD-OCT (Heidelberg Engineering).

Eyes with a spherical equivalent myopia or hyperopia greater than 5.0 D, astigmatism greater than 3.0 D, aphakia, and pseudophakia were excluded from the study and control groups. In addition, eyes without OCT scans were excluded.

Optic disc and macula OCT scans were obtained with the Cirrus SD-OCT (Carl Zeiss Meditec) or the Spectralis SD-OCT (Heidelberg Engineering). The posterior vitreous detachment (PVD) over the macula was assessed with the OCT scans, and total PVD was assessed with the OCT scans and ophthalmologically. Two observers blinded to the eyes' clinical information evaluated the OCT scans.

Statistical analysis was performed using SigmaPlot 12.5 software. The comparisons were done with the chi-square test for the categorical variables. The level of statistical significance was determined as $P < 0.05$.

Results

In this study, 32 eyes with NAION were compared with 31 age- and refraction-matched healthy eyes with crowded optic discs (control group I) and 32 healthy eyes with noncrowded optic discs (control group II). The groups had similar clinical characteristics in terms of age, refraction, and incidence of risk factors for NAION, such as hypertension, diabetes mellitus, and smoking (Table 1).

A significant result of our study was that eyes with NAION and healthy eyes with crowded optic discs had a lower incidence of total PVD compared with eyes with noncrowded optic discs (Table 1; $P = 0.0005$) despite all groups demonstrating similar clinical characteristics and similar rates of macular PVD (Table 1; $P = 0.93$).

Focal vitreopapillary attachments, apart from the vitreous attachment to the disc edges, were noted in more eyes with NAION and healthy eyes with crowded discs than those with noncrowded discs ($P = 0.007$; Table 2). The vitreopapillary attachments were in the form of glial condensations (Fig 1). Although the incidence of such vitreopapillary attachments was not different in eyes with NAION versus healthy eyes with crowded discs (71.9% vs. 58.1%; $P = 0.25$), vitreovascular attachments to major vessels over the optic discs were more frequent in eyes with NAION (68.8%) compared with healthy eyes with crowded discs (3.2%) and noncrowded discs (6.3%; $P = 0.00001$; Table 2; Fig 1).

Evaluation of eyes with total PVD revealed that 4 eyes (66.7%) with NAION had readily apparent epipapillary membranes on their optic discs (Fig 2). In comparison, such membranes were observed in only 1 healthy eye (20%) with a crowded disc and PVD, and none of the 18 eyes with PVD and noncrowded discs ($P = 0.0009$; Table 3).

In 4 eyes (12.5%) with NAION, tearing of thick epipapillary membranes from the underlying disc tissue due to vitreous traction on the optic disc was observed. The epipapillary membranes appeared thick and tightly attached to the optic disc tissue in these eyes. In addition, the vitreous attachment to the epipapillary membranes appeared to be obtuse-angled in these NAION eyes (Fig 3A, B). Less-extensive and less-dense epipapillary membranes were observed in only 2 healthy eyes (6%) with crowded discs (Fig 3C, D) and in 2 healthy eyes (6%) with noncrowded discs (Fig 3E, F). However, the epipapillary tissue in these eyes did not appear to be associated with distortion of the underlying tissue (Fig 3C−F). Instead, in healthy crowded discs, the epipapillary tissue was less dense than an epipapillary membrane and appeared to have more loose connections to the underlying nerve tissue with gaps (Fig 3C, D). In healthy noncrowded discs, it appeared as a

Table 1. Characteristics of the Patients and Their Eyes

	Age (yrs)	Refraction	Total PVD	Macular PVD	HT	DM	Smoking History
Study (NAION) Group (n = 32)	64.4 ± 9.2	−0.24 ± 1.68 D	6 eyes (18.8%)	20 eyes (62.5%)	18 cases (56.3%)	4 cases (12.5%)	4 cases (12.5%)
Control Group 1 (n = 31) (Healthy Crowded Optic Discs)	64.2 ± 9.7	0.01 ± 1.70 D	5 eyes (16.1%)	19 eye (61.3%)	14 cases (45.2%)	4 cases (12.9%)	3 cases (9.7%)
Control Group 2 (n = 32) (Healthy Noncrowded Optic Discs)	64.2 ± 9.6	−0.03 ± 1.51 D	18 eyes (56.3%)	21 eyes (65.6%)	11 cases (34.4%)	6 cases (18.8%)	4 cases (12.5%)
	$P = 0.99$	$P = 0.81$	**$P = 0.0005$***	$P = 0.93$	$P = 0.21$	$P = 0.73$	$P = 0.92$

D = diopters; DM = diabetes mellitus; HT = hypertension; PVD = posterior vitreous detachment.
*Chi-square test.

further less dense tissue that appeared to be almost disconnected from the optic disc (Fig 3E, F).

In a single eye with NAION, the temporal relationship of clinical findings with PVD and separation of the glial matrix over major disc vessels was documented (Fig 4).

Discussion

Nonarteritic ischemic optic neuropathy is the most common acute optic neuropathy of adulthood and is the second most common cause of permanent optic nerve–related visual loss after glaucoma.[11] However, our understanding of various features of NAION remains incomplete. The relationship of NAION to crowded disc morphology, the preference for superior involvement with a lower altitudinal visual field defect, and the absence of cupping after loss of neural tissue are among unexplained features. Furthermore, a major recent controversy has been on the role of vitreous separation or traction in NAION pathogenesis. To better understand the role of vitreous in the disease process, we investigated its relationship with the optic disc in eyes with and without crowded discs.

A significant finding in our present study was a lower incidence of total PVD in eyes with NAION (16.1%) and crowded healthy discs (18.8%) compared with eyes with noncrowded optic discs (56.3%) (Table 1). A recent study demonstrated even a lower (8.0%) rate of total PVD with swept-source OCT in a smaller group (23 eyes) of the younger age group (median age of 52 years) of nonacute NAION eyes.[12] However, the rate of total PVD was not compared with a healthy control group. In another study with a similar age group, total PVD was documented in only 10% of eyes before the onset of NAION and in only 30% of eyes with acute NAION.[9]

The persistent attachment of the posterior vitreous to the disc, that is, lack of total PVD, associated with NAION or healthy crowded discs, implies a stronger vitreopapillary attachment and that vitreous forces or traction can be transmitted to the optic disc. Compared with a totally attached posterior vitreous, the forces transmitted to the disc may be more pronounced in the setting of a macular PVD, because the vitreous is relatively more mobile, and the forces are transmitted only to the disc. However, the study of only a relationship of an acute total PVD at the time of NAION presentation, as in previous studies,[9,10] may be misleading. First, in the setting of a swollen optic disc during acute NAION, it is difficult to clearly observe the status of the posterior vitreous and document the presence of a total PVD in many cases. Second, a total PVD only implies the termination of tractional forces on the disc at the time of observation. However, PVD is an insidious, slowly progressive, and lengthy process associated with vitreous syneresis and synchysis and takes many years. Total PVD only marks the conclusion of this long process. Thus, it cannot rule out vitreous traction at different time points of this process or the onset of NAION. Persistence of the vitreous attachment and its

Table 2. Incidence of Focal Vitreopapillary Attachments

	Eyes with NAION (n = 32)	Healthy Crowded Disks (n = 31)	Healthy Noncrowded Disks (n = 32)
Vitreopapillary attachments	23 (71.9%)	18 (58.1%)	6 (18.8%)*
Attachments over disc vessels (Vitreovascular attachments)	22 (68.8%)†	1 (3.2%)	2 (6.3%)

NAION = nonarteritic ischemic optic neuropathy.
*$P = 0.007$ chi-square test.
†$P = 0.00001$ chi-square test.

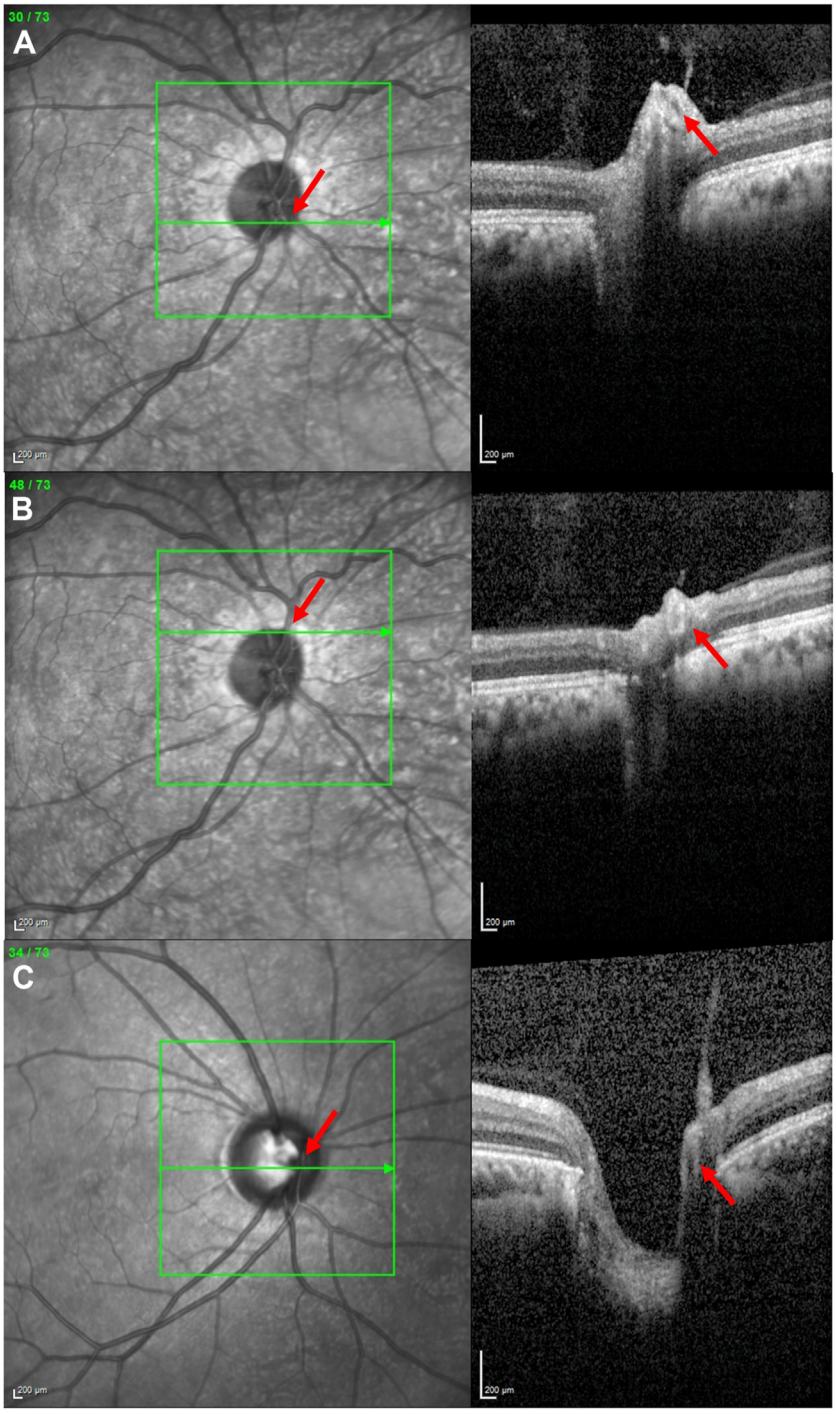

Figure 1. A, OCT scan demonstrating a vitreovascular attachment (**red arrows** indicate the location of the vessel) in an eye with nonarteritic ischemic optic neuropathy (NAION). **B.** OCT section from the same eye as in **A** showing another vitreovascular attachment (**red arrows** indicate the location of the vessel) located distant to the one in **A**. **C,** In a healthy crowded disc, the vitreopapillary attachment is not to the vessel (**red arrows** indicate the location of the vessel).

stronger nature in crowded discs also may explain the predilection for involvement of the superior nerve fibers and thus altitudinal inferior visual field defect in NAION, because gravitational forces would be transmitted to the superior part of the optic disc to a greater extent than to its inferior part.[13]

The cup size is small, whereas the disc size is normal in eyes with NAION.[14,15] Because the number of retinal nerve

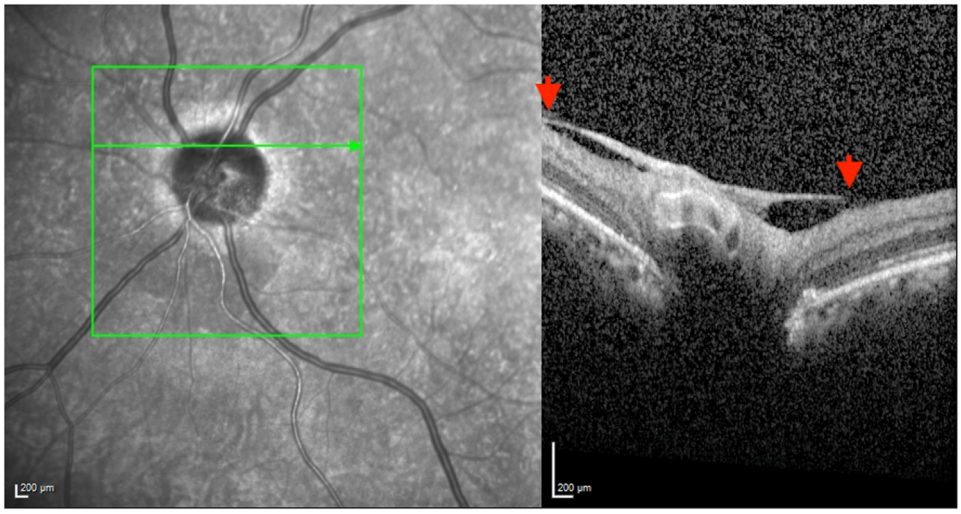

Figure 2. In an eye with nonarteritic ischemic optic neuropathy (NAION) and total posterior vitreous detachment (PVD), the posterior hyaloid appears thickened as an epipapillary membrane and is attached to the optic disc surface, which implies that PVD occurred in a plane anterior to the epipapillary membrane (**red arrows** indicate the edges of the epipapillary membrane). The close relationship of the epipapillary membrane to underlying major vessels is noticeable.

fibers in the optic nerve is stable, the cause of crowding appears to be the overpopulation of the astrocytes,[3,16] which are the source of the glial matrix covering the optic disc that consists of glycosaminoglycans and a basal lamina.[17] An important feature of this basal lamina is the presence of defects and discontinuities.[18] Histopathological studies have demonstrated that the glia extends through these defects and discontinuities as spiny processes and the glia has attachments to the vitreous.[19] In the present study, the focal vitreopapillary attachments observed in OCT images of NAION eyes and healthy eyes with crowded discs may correspond to these histopathologically described glial processes.

In further analysis of our results, we aimed to understand why some eyes with crowded discs developed NAION, whereas others did not. Both healthy eyes with crowded discs and NAION eyes had a comparable rate of total PVD (18.8% vs. 16.1%). Thus, vitreous traction alone could not explain the disease process. Analysis of the OCT images revealed that the focal vitreopapillary attachments were more frequently related to major optic disc vessels in NAION eyes (68.8%) than in both healthy eyes with crowded discs (3.2%) and noncrowded discs (6.3%) (Table 2). These focal vitreopapillary attachments associated with major vessels may represent the previously described histopathological vitreovascular attachments in NAION eyes.[3] These vitreovascular attachments may transmit the vitreous tractional forces directly to the major optic disc vessels.

We also analyzed the optic disc surface structure of NAION eyes with PVD compared with healthy eyes. Another suggestion for the role of vitreous traction in NAION was the observation of epipapillary membranes on optic discs frequently after total PVD in NAION eyes, which was rarer in healthy controls after total PVD (Fig 2; Table 3). These epipapillary membranes have been defined histopathologically[19] and seem to represent a strong vitreopapillary attachment over the disc surface in eyes with NAION that leads to a different plane of vitreous separation than in conventional PVD. Such strong vitreopapillary attachments may lead to the transmission of greater vitreal tractional forces to the disc during the

Table 3. Eyes with Epipapillary Membranes on Disc after Total Posterior Vitreous Detachment

	Eyes with NAION (n = 32)	Healthy Eyes with Crowded Disks (n = 31)	Healthy Eyes with Normal Disks (n = 32)	*P* value
No. of eyes with total PVD	6 (18.8%)	5 (16.6%)	18 (56.3%)	
Eyes with epipapillary membranes after total PVD	4 (66.7%)*	1 (20.0%)	0 (0%)	0.0009*

NAION = nonarteritic ischemic optic neuropathy; PVD = posterior vitreous detachment.
*Chi-square test.

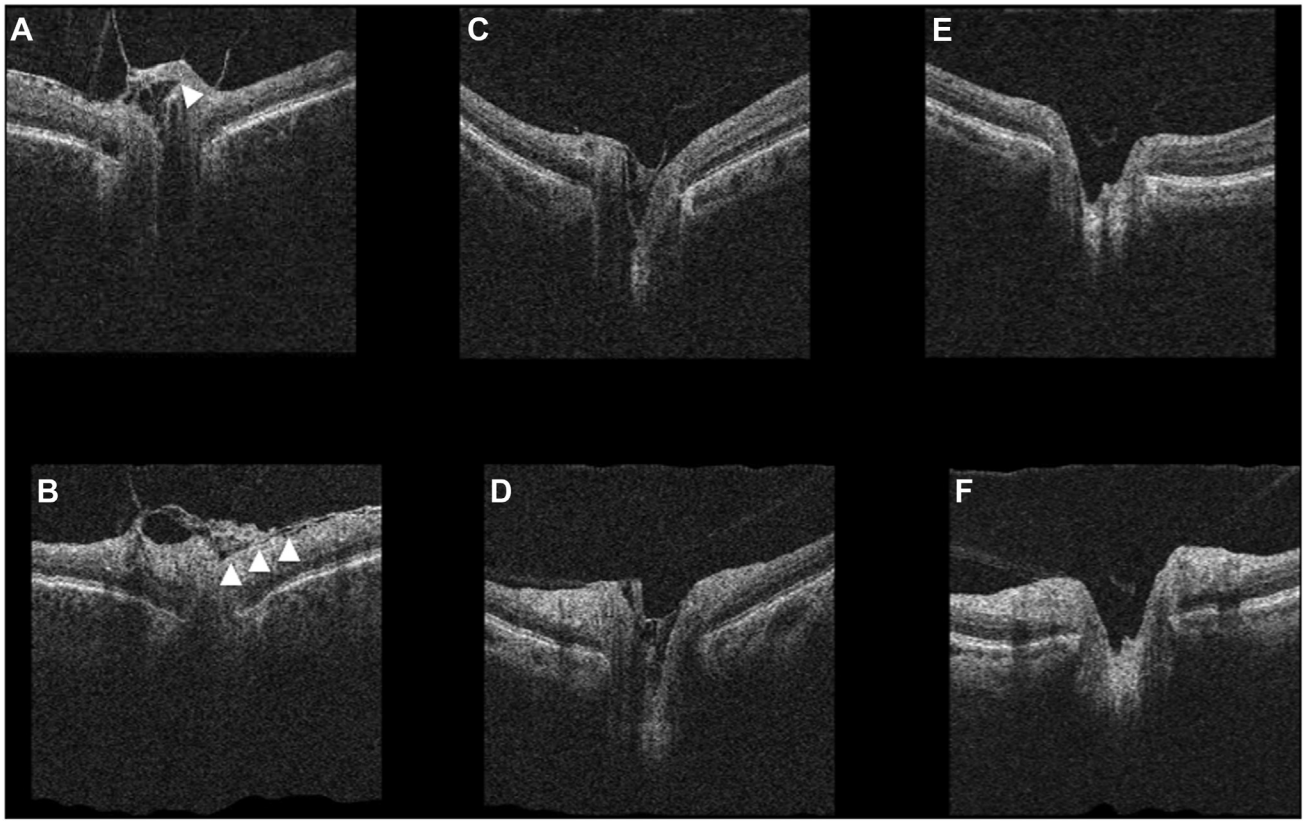

Figure 3. In an eye with nonarteritic ischemic optic neuropathy (NAION), posterior vitreous traction leads to tearing of the dense and thick epipapillary membrane (**white arrowheads** in the horizontal **A** and vertical **B** sections). In a healthy eye with a crowded disc, the posterior vitreous attachment to the epipapillary tissue and the attachment of the epipapillary tissue to the optic disc appears loose with no significant distortion of underlying tissues: horizontal (**C**) and vertical (**D**) sections. In a healthy eye with a noncrowded disc, the posterior vitreous appears to have almost detached from the center of the optic disc with a loose epipapillary tissue: horizontal (**E**) and vertical (**F**) sections. Vertical OCT sections (**B**, **D,** and **F**) were obtained in an inferior to superior direction.

progress of PVD. Such tractional forces have been proposed to be capable of causing functional and structural disc changes in NAION.[3] Thus, among eyes with crowded discs, those with further firmer vitreopapillary attachments may be inclined to NAION.

Supporting this point, tearing of thick epipapillary membranes from underlying disc tissue due to vitreous traction was observed in 4 eyes with NAION (Fig 3A, B; Fig 4A, B). In contrast to the obtuse-angled, firm attachment or "traction" of posterior vitreous in eyes with NAION, in healthy eyes with crowded and noncrowded discs, the epipapillary membranes were in the form of an "adhesion" with gaps and "loose" attachment to the disc (Fig 3C, D) or had led to the separation of a very loose membrane without damage (Fig 3E, F), respectively.

In 1 NAION eye, it was possible to demonstrate the happening of NAION with a simultaneous PVD. In this eye, the optic nerve swelling initially increased with the progression of PVD (Fig 4B, C) and resolved with the completion of PVD and the separation of the epipapillary membrane from the optic disc (Fig 4D). This case also implied a different vitreopapillary relationship in NAION.

Our observations point to the role of vitreopapillary traction, which may contort the vessel walls and alter the blood flow. This mechanism may act as a triggering or contributory factor in susceptible eyes, which may have already altered blood flow or vascular insufficiency from multiple risk factors. In addition, traction may alter blood flow indirectly through other mechanisms. For example, tractional forces can affect astrocytes, which are cells recognized to play an important role in the modulation of the blood flow in neural tissues. In animal models, astrocytes have been shown to modulate vascular caliber in the central nervous system through their end feet over capillaries.[20,21] In addition, tractional stress on vasculature is well known to alter the local nitric oxide and endothelin-1 equilibrium toward vasoconstriction.[22,23]

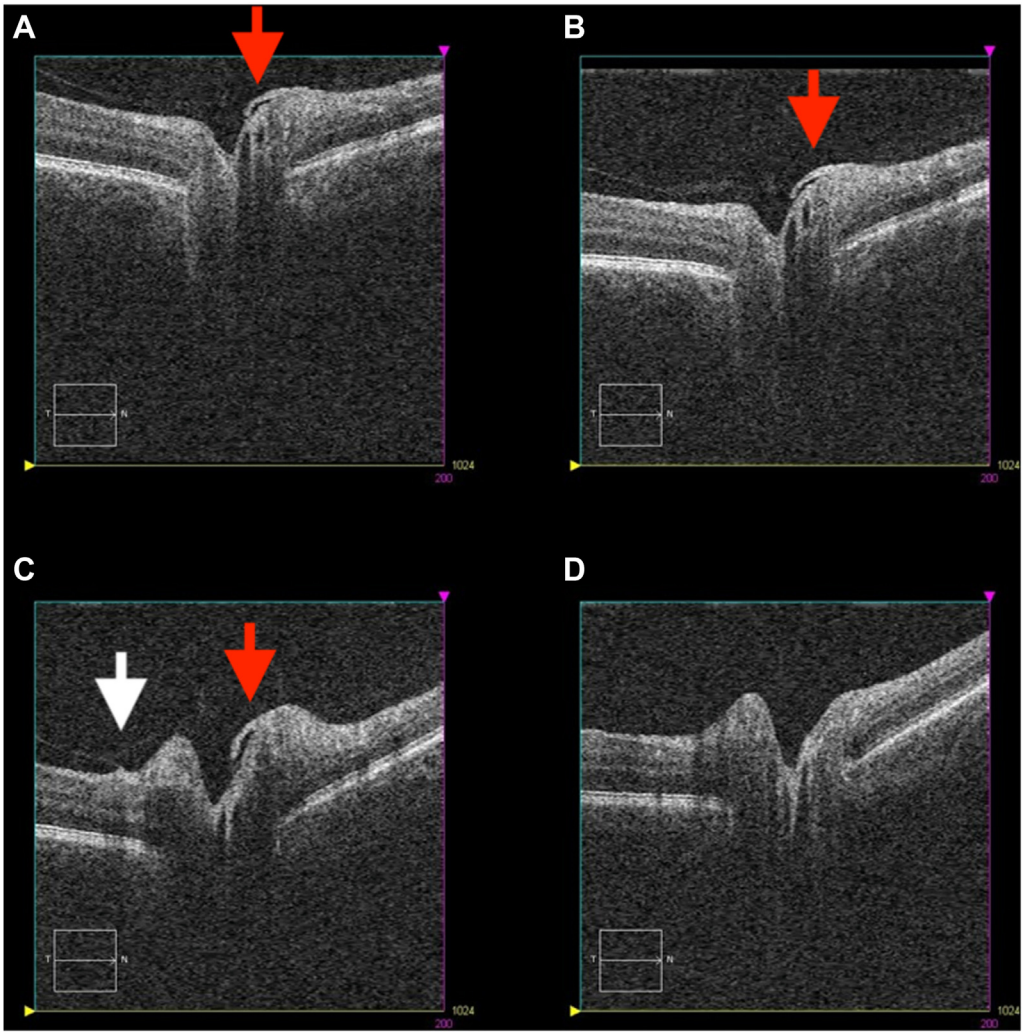

Figure 4. Temporally sequential images of the optic disc at the same cross-section of a nonarteritic ischemic optic neuropathy (NAION) eye. Posterior vitreous detachment is associated with the tearing of an epipapillary membrane (red arrows) over major disc vessels (**A**–**D**). The relationship of the epipapillary membrane to the vessels is most evident in images **A** and **B**. Traction (**white arrow**) becomes evident at the posterior hyaloid attachment to the temporal disc edge (**C**), and the disc appears more swollen compared with images **A** and **B.** The disc swelling associated with NAION subsides completely with total posterior vitreous and epipapillary membrane detachment **(D)**.

Conclusions

The results of the current study point to a different vitreopapillary relationship, the persistence of a strong vitreous attachment, and the transmission of tractional forces to the optic disc in crowded discs. The different features of PVD, such as the tearing of the vitreous collagen structure or the epipapillary membranes, point to a further stronger vitreopapillary attachment in NAION eyes. In these eyes, the transduced mechanical forces by a syneretic vitreous gel, especially after a partial or macular PVD, may contort vessel walls and disrupt the blood flow through multiple pathways. Our results encourage further research in imaging the vitreoretinal interface in crowded discs, particularly to describe features related to NAION development.

Footnotes and Disclosures

Originally received: March 31, 2024.
Final revision: August 25, 2024.
Accepted: September 9, 2024.
Available online: September 12, 2024. Manuscript no. OPHTHA-D-24-00638.

[1] Columbia University, Department of Ophthalmology, Vagelos College of Physicians and Surgeons, New York, New York.

[2] Gazi University, Department of Ophthalmology, Ankara, Turkey.

[3] SBU Ulucanlar Goz Egitim Arastirma Hastanesi, Ankara, Turkey.

Disclosure(s):

All authors have completed and submitted the ICMJE disclosures form.

This study was partially supported by an unrestricted grant from Research to Prevent Blindness, Inc., New York, NY to the department and Foley Research Fund, New York, NY (T.H.T.).

HUMAN SUBJECTS: Human subjects were included in this study. This retrospective case analysis was approved and monitored by the Institutional Review Board (IRB) of Columbia University, Vagelos College of Physicians and Surgeons, and conducted according to the principles of the Declaration of Helsinki. Due to the study's retrospective design, the IRB waived informed consent.

No animal subjects were used in this study.

Author Contributions:

Conception and design: Tezel

Data collection: A.M. Hondur, Moazami, Tezel

Analysis and interpretation: Hondur, Moazami, Hondur, Tezel

Obtained funding: Tezel

Overall responsibility: Hondur, Hondur, Tezel

Abbreviations and Acronyms:
D = diopters; **NAION** = nonarteritic ischemic optic neuropathy; **PVD** = posterior vitreous detachment; **SD-OCT** = spectral-domain-OCT.

Keywords:
Epipapillary membrane, Nonarteritic ischemic optic neuropathy, Posterior vitreous detachment, Vitreopapillary traction, Vitreovascular attachment.

Correspondence:
Tongalp H. Tezel, MD, 622 West 168th Street, 18th Floor, Suite 18201B, Mailbox 200, New York, NY 10032. E-mail: tht2115@cumc.columbia.edu.

References

1. Hattenhauer MG, Leavitt JA, Hodge DO, et al. Incidence of nonarteritic anterior ischemic optic neuropathy. *Am J Ophthalmol*. 1997;123:103−107.
2. Johnson LN, Arnold AC. Incidence of nonarteritic and arteritic anterior ischemic optic neuropathy. Population-based study in the state of Missouri and Los Angeles County, California. *J Neuroophthalmol*. 1994;14:38−44.
3. Parsa CF, Hoyt WF. Nonarteritic anterior ischemic optic neuropathy (NAION): a misnomer. Rearranging pieces of a puzzle to reveal a nonischemic papillopathy caused by vitreous separation. *Ophthalmology*. 2015;122:439−442.
4. Boutigny A, Mohamedi N, Pardo SJ, et al. Impairment of central retinal artery hemodynamics in affected and fellow eyes in giant cell arteritis patients with unilateral vision loss. *Autoimmun Rev*. 2023;22:103272.
5. Feit RH, Tomsak RL, Ellenberger Jr C. Structural factors in the pathogenesis of ischemic optic neuropathy. *Am J Ophthalmol*. 1984;98:105−108.
6. Lessell S. Nonarteritic anterior ischemic optic neuropathy. *Arch Ophthalmol*. 1999;117:386.
7. Modarres M, Sanjari MS, Falavarjani KG. Vitrectomy and release of presumed epipapillary vitreous traction for treatment of nonarteritic anterior ischemic optic neuropathy associated with partial posterior vitreous detachment. *Ophthalmology*. 2007;114:340−344.
8. Nomura Y, Tamaki Y, Yanagi Y. Vitreopapillary traction diagnosed by spectral domain optical coherence tomography. *Ophthalmic Surg Lasers Imaging*. 2010;41(Suppl):S74−S76.
9. Thompson AC, Bhatti MT, Gospe 3rd SM. Spectral-domain optical coherence tomography of the vitreopapillary interface in acute nonarteritic anterior ischemic optic neuropathy. *Am J Ophthalmol*. 2018;195:199−208.
10. Molaie AM, Pramil V, Hedges 3rd TR, et al. Vitreoretinal findings in nonarteritic ischemic optic neuropathy. *J Neuroophthalmol*. 2022;42:e124−e129.
11. Miller NR, Arnold AC. Current concepts in the diagnosis, pathogenesis and management of nonarteritic anterior ischaemic optic neuropathy. *Eye (Lond)*. 2015;29:65−79.
12. Li D, Sun S, Liang J, et al. Papillary vitreous detachment as a possible accomplice in non-arteritic anterior ischaemic optic neuropathy. *Br J Ophthalmol*. 2024;108:607−612.
13. Parsa CF, Williams ZR, Van Stavern GP, Lee AG. Does vitreopapillary traction cause nonarteritic anterior ischemic optic neuropathy? *J Neuroophthalmol*. 2022;42:260−271.
14. Rebolleda G, Pérez-Sarriegui A, Díez-Álvarez L, et al. Lamina cribrosa position and Bruch's membrane opening differences between anterior ischemic optic neuropathy and open-angle glaucoma. *Eur J Ophthalmol*. 2019;29:202−209.
15. Moghimi S, Afzali M, Akbari M, et al. Crowded optic nerve head evaluation with optical coherence tomography in anterior ischemic optic neuropathy. *Eye (Lond)*. 2017;31:1191−1198.
16. Rao NA, Spencer WH. Optic Nerve. In: Spencer WH, ed. *Ophthalmic Pathology: An Atlas and Textbook*. 1. 4th ed. Philadelphia, PA: Saunders; 1996:513−622.
17. Wang MY, Sadun AA, Sebag J. Vitreo-papillary adhesion and traction. In: Sebag J, ed. *Vitreous in Health and Disease*. New York, NY: Springer; 2024:299−310.
18. Foos RY, Roth AM. Surface structure of the optic nerve head. 2. Vitreopapillary attachments and posterior vitreous detachment. *Am J Ophthalmol*. 1973;76(5):662−671. https://doi.org/10.1016/0002-9394(73)90560-6. PMID: 4748187.
19. Roth AM, Foos RY. Surface structure of the optic nerve head. 1. Epipapillary membranes. *Am J Ophthalmol*. 1972;74:977−985.
20. Takano T, Tian GF, Peng W, et al. Astrocyte-mediated control of cerebral blood flow. *Nat Neurosci*. 2006;9:260−267.
21. Zonta M, Angulo MC, Gobbo S, et al. Neuron-to-astrocyte signaling is central to the dynamic control of brain microcirculation. *Nat Neurosci*. 2003;6:43−50.
22. Vozzi F, Bianchi F, Ahluwalia A, Domenici C. Hydrostatic pressure and shear stress affect endothelin-1 and nitric oxide release by endothelial cells in bioreactors. *Biotechnol J*. 2014;9:146−154.
23. Morawietz H, Talanow R, Szibor M, et al. Regulation of the endothelin system by shear stress in human endothelial cells. *J Physiol*. 2000;525:761−770.