INTERNAL MEDICINE

□ CASE REPORT □

Thromboembolic Splenic Infarction As a Rare Complication of Myocardial Infarction

Sinan Akýncý, Yusuf Tavil, Salih Topal, Hýzýr Okuyan and Atiye Çengel

Key words: splenic infarction, acute myocardial infarction, arterial thromboembolism

(DOI: 10.2169/internalmedicine.46.6456)

Introduction

Systemic thromboembolism related to acute myocardial infarction (MI) is an important cause of mortality and morbidity (1, 2). In particular, the presence of left ventricular mural thrombus is strongly associated with an increased risk of embolism. Although, embolic events are frequently seen in the cerebrovascular system, other sites of embolism such as; kidney, lower limbs, and mesentery have been previously reported (3) However, splenic thromboembolism which is related to MI has been rarely reported in the literature. Only 3 cases of splenic thromboembolism as a complication of MI were found in the literature (4). Herein, we present a patient who was complicated by splenic thromboembolism in the course of MI.

Case Report

A 58-year-old male patient was referred to our clinic for coronary angiography. His previous reports revealed that he had been hospitalized and given streptokinase infusion for acute anterior MI one week earlier. During his follow-up he had been treated with aspirin, intravenous heparin infusion, beta blockers and ACE inhibitors. It was also reported that ventricular tachycardia occurred in the setting of MI, which had been treated with intravenous amiodarone (1,000 mg iv). At the time of admission to our clinic his pulse rate and blood pressure was 84 bpm and 110/70 mmHg, respectively. Physical examination was normal except for crackles at the basal segments of left lung and tenderness at the left upper quadrant of the abdomen. Electrocardiogram findings revealed QS waves and a slight ST elevation in leads V_2 to V_6, concordant with subacute anterior MI. Laboratory tests revealed leukocytosis (12,000/mm^3), elevated erythrocyte sedimentation rate (77 mm/h), and increased liver enzymes (AST: 233 U/l [normal, 8-35], ALT: 99 U/l [normal, 5-43]). Hepatotrophic viral markers were negative, and coagulation parameters were within normal ranges. Echocardiography showed a left ventricular apical aneurysm with mural thrombus (Fig. 1). There was infiltrative appearance at the basal segment of the left lung on the chest radiogram. Based upon these findings, the diagnosis of pneumonia was considered and oral antibiotic therapy was started (levofloxacin 500 mg bid). Despite this treatment, leukocytosis and elevated liver enzymes were not resolved, so further investigations were conducted to address these unresolved issues. Abdominal ultrasonogram showed a heterogeneous appearance in the middle segment of the spleen. Contrast computed tomography confirmed this appearance with a wedge type infarct area in the middle segment of the spleen (Fig. 2). Thus, the patient received the anticoagulant, enoxaparin (60 mg sc bid), until he became clinically stable. After ten days, coronary angiography was performed. There was a noncritical stenosis at the mid segment of LAD, and no intervention was planned for this lesion. The patient was discharged with medical therapy which included beta blocker (metoprolol tartarate 50 mg bid), salicylate (100 mg/d), statin (atorvastatin 20 mg/d), ACE inhibitor (ramipril 5 mg/d), and warfarin sodium (5 mg/d).

Over the six-month follow-up period, no new embolic event was observed. The control echocardiography at the 6th month showed that the apical LV thrombus was resolved.

Discussion

Splenic infarction caused by systemic thromboembolism is a well-known complication associated with several cardiovascular disorders. Although, thromboembolic complications were seen in 3-5% of all acute MI, splenic infarct due to MI was infrequently reported (5). It was shown that the risk of systemic thromboembolism in patients with MI which is 3.4% decreases to 1.3% after anticoagulant therapy (6). According to the previous reports, the incidence of cerebral

Department of Cardiology, Gazi University Medical Shool, Ankara
Received for publication December 23, 2006; Accepted for publication June 29, 2007
Correspondence to Dr. Yusuf Tavil, yusuftavil@gmail.com

DOI: 10.2169/internalmedicine.46.6456



Figure 1. **Transthoracic echocardiography demonstrating apical aneurysm and thrombus formation.**

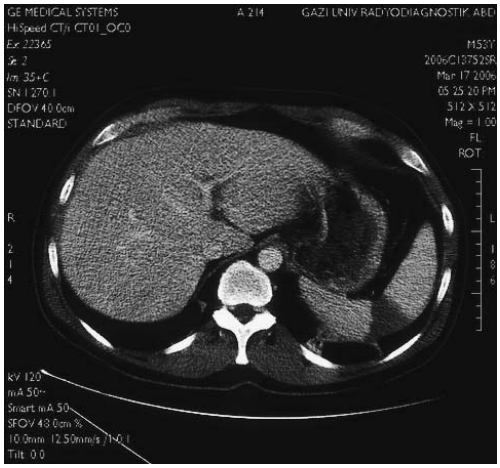

Figure 2. **Contrasted computed tomography showing a wedge type infarct area in the middle segment of spleen.**

embolism was 3.2% and peripheric embolism was 2.4% of all MI patients (7). Embolization of atheromatous debris from the aorta, thrombotic elements from the left ventricle, and vegetations from infected valves are the most common settings in which thromboembolic splenic infarcts are noted. Although there is no information on the incidence of splenic thromboembolism in these conditions, several case reports have been published. Other causes of splenic infarction, especially in younger patients, are sickle cell anemia, leukemia, sarcoidosis, and pancreatitis.

Hyperhomocysteinemia is a frequent cause of arterial embolism and coronary heart disease. Since it has potential to cause splenic embolism and MI, it should be excluded in this patient. But to date there are no published cases of splenic embolism due to hyperhomocysteinemia. Other frequent hematologic diseases such as protein C, S deficiency, factor V leiden, and AT III resistance usually causes venous thromboembolism, so these disorders were not investigated in our patient.

The existence of left ventricular thrombus increases the risk of embolic events 5.4 times in patients with MI (8). The detection of thrombus within the left ventricle is important in acute myocardial infarction, left ventricular aneurysm, and cardiomyopathy as specific treatment recommendations must be arranged for this condition (9).

The clinical presentation of splenic infarction is typically nonspecific; manifestations may include fever, tachycardia, and left upper-quadrant tenderness. In the present patient, even though he had left upper quadrant tenderness, we inadvertently failed to notice splenic infarction, because there were crackles at the basal segments of the left lung and the infiltrative appearance at the basal segment of left lung on chest radiogram which evoked the diagnosis of pneumonia. At that point, the suspicion of splenic infarction had to be considered. Computed tomographic scanning and, to a lesser degree, ultrasonography are the imaging techniques that are useful and sufficient for the diagnosis splenic infarction.

Treatment is generally nonoperative. Splenectomy should be performed for persistent symptoms or if a splenic abscess or hemorrhage occurs. In an autopsy series of 96 consecutive cases of splenic infarction, only 10% was suspected clinically, however splenic infarctions contributed substantially to morbidity and mortality in 44% of the cases (10).

It should be emphasized that splenic infarction must be suspected in patients with MI who develop left upper quadrant pain and signs of localized or systemic inflammation. In addition, some serious complications of splenic infarction including abscess and rupture should be considered. CT scan is currently the preferred diagnostic test, but the ultimate diagnosis depends on the pathologic examination of the spleen (11).

References

1. Vaitkus PT. Left ventricular mural thrombus and the risk of embolic stroke after acute myocardial infarction. J Cardiovasc Risk **2**: 103-106, 1995.
2. Chesebro JH, Ezekowitz M, Badimon L, Fuster V. Intracardiac thrombi and systemic thromboembolism: Detection, incidence, and treatment. Ann Rev Med **36**: 579-605, 1985.
3. Meltzer RS, Visser CA, Fuster V. Intracardiac thrombi and systemic embolization. Ann Intern Med **104**: 689-698, 1986.
4. Puletti M, Cusmano E, Testa MG, Borgia C, Fanari F, Curione M. Incidence of systemic thromboembolic lesions in acute myocardial infarction. Clin Cardiol **9**: 331-333, 1986.
5. Wilensky RL, Jung SC. Thromboembolism in patients with decreased left ventricular function: incidence, risk, and treatment. J Cardiovasc Risk **2**: 91-96, 1995.
6. Working Party on Anticoagulant Therapy in Coronary Thrombosis to The Medical Research Council. Assessment of short-term anticoagulant administration after cardiac infarction. Br Med J **1**: 335-342, 1969.
7. Veterans Administration Cooperative Clinical Trial Group. Anticoagulants in acute myocardial infarction:results of a cooperative clinical trial. JAMA **225**: 724-729, 1973.
8. Vaitkus PT, Barnathan ES. Embolic potential, prevention and man-

DOI: 10.2169/internalmedicine.46.6456

agement of mural thrombus complicating anterior myocardial infarction: a meta-analysis. J Am Coll Cardiol **22**: 1004-1009, 1993.

9. Domenicucci S, Chiarella F, Bellotti P, Lupi G, Scarsi G, Vecchio C. Early appearance of left ventricular thrombi after anterior myocardial infarction: a marker of higher in-hospital mortality in patients not treated with antithrombotic drugs. Eur Heart J **11**: 51-58, 1990.

10. O'Keefe JH, Holmes DR, Schaff HV, Sheedy PF, Edwards WD. Thromboembolic splenic infarction. Mayo Clin Proc **61**: 967-972, 1986.

11. Jaroch MT, Broughan TA, Hermann RE. The natural history of splenic infarction. Surgery **100**: 743-750, 1986.

© 2007 The Japanese Society of Internal Medicine
http://www.naika.or.jp/imindex.html