Bone Marrow Transplantation (2008) 42, 461–467
© 2008 Macmillan Publishers Limited All rights reserved 0268-3369/08 $32.00
www.nature.com/bmt

ORIGINAL ARTICLE

The role of liver biopsy in the workup of liver dysfunction late after SCT: is the role of iron overload underestimated?

GT Sucak[1], ZA Yegin[1], ZN Özkurt[1], ŞZ Akı[1], T Karakan[2] and G Akyol[3]

[1]*Department of Hematology, Faculty of Medicine, Gazi University, Ankara, Turkey;* [2]*Department of Gastroenterology, Faculty of Medicine, Gazi University, Ankara, Turkey and* [3]*Department of Pathology, Faculty of Medicine, Gazi University, Ankara, Turkey*

Abnormalities in liver function tests are common in hematopoietic SCT (HSCT) recipients. We retrospectively investigated the role of liver biopsy in determining the cause of elevated liver enzymes and its impact on the management of patients in the post-HSCT setting. A total of 24 consecutive liver biopsies were obtained from 20 patients from September 2003 to December 2007. A definite histopathologic diagnosis was obtained in 91.7% of the biopsies. Iron overload (IO) was found in 75% and GVHD in 54.2% of the patients. The initial clinical diagnosis of GVHD was confirmed in 56.5% and refuted in 43.5% of the allogeneic HSCT recipients. The median number of post transplant transfusions, percent transferrin saturation and ferritin levels were found to be higher in patients who had histologically proven hepatic IO ($p1 = 0.007$, $p2 = 0.003$ and $p3 = 0.009$, respectively). Regression analysis showed a significant correlation between serum ferritin levels and histological grade of iron in the hepatocytes. Our data suggest that hepatic IO is a frequent finding in the post-HSCT setting, which contributes to hepatic dysfunction and it should be considered in the differential diagnosis, particularly in patients with high serum ferritin levels.
Bone Marrow Transplantation (2008) **42,** 461–467; doi:10.1038/bmt.2008.193; published online 7 July 2008
Keywords: elevated liver enzymes; hematopoietic SCT; iron overload; GVHD; liver biopsy

Introduction

Liver dysfunction is a frequent complication of hematopoietic SCT (HSCT), occurring in 50–72% of patients with mortality rates ranging between 4 and 15%.[1–6] A substantial number of HSCT survivors suffer from chronic liver disease (CLD).[4,6] Etiology of liver dysfunction depends on factors such as type of HSCT, conditioning regimen, viral hepatitis status and the time interval post transplant that dysfunction is seen. The major causes of liver dysfunction in the early post transplant period are chemotherapy, radiotherapy, sinusoidal obstruction syndrome/venoocclusive disease (SOS/VOD), infections (hepatitis lenta) and drugs, whereas GVHD, iron overload (IO) and reactivation of viral infections such as CMV) and hepatitis B and C account for most of the cases of liver dysfunction in the intermediate and late periods.[3–8] Diagnosis usually depends on the clinical and laboratory features and exclusion of possible etiologic factors. Reactivation of virus infections and acute viral hepatitis are diagnosed with molecular viral tests, and SOS/VOD and GVHD are usually diagnosed clinically. However, the cause of elevated liver enzymes needs to be ascertained by liver biopsy occasionally in order to administer disease-specific therapy and avoid unnecessary immunosuppression. Although a very valuable diagnostic tool particularly in cases with uncertain and overlapping clinical features, liver biopsy is an invasive procedure with a significant complication rate.[8] There is an increased rate of hemorrhagic complications due to thrombocytopenia during the early post transplant period, during which time transjugular biopsy is the method of choice.[8,9] We retrospectively reviewed the medical records of 20 patients in whom liver biopsy was required to clarify the cause of elevated liver enzymes post transplantation. The impact of liver biopsy in the management of liver dysfunction in these 20 HSCT recipients was also evaluated.

Patients and methods

Patients

The charts of the 207 patients (123 allogeneic and 84 autologous) who underwent HSCT at Gazi University Hospital, between September 2003 and December 2007 were retrospectively reviewed. Of the 207 patients, 193 had at least one of the liver enzymes above normal levels at some point after HSCT (118 allogeneic and 75 autologous). The majority of the liver enzyme abnormalities were transient and in the early post transplant period, and were either due to conditioning or to other hepatotoxic drugs or complications such as SOS/VOD. Patients with hepatic GVHD usually had elevated bilirubin levels ± elevated liver

Correspondence: Dr GT Sucak, Department of Hematology, Faculty of Medicine, Gazi University, Bilkent-1 Çamlık Sitesi E-6 Blok, No. 18, Ankara 6533, Turkey.
E-mail: aysucak@gazi.edu.tr
Received 21 January 2008; revised 30 April 2008; accepted 7 May 2008; published online 7 July 2008

enzymes. A total of 20 patients with persistent elevation of liver enzymes, including 13 men and 7 women with an age range of 17–52 years required 24 liver biopsies. These were at a median 211 (11–955) days after HSCT. Clinical, laboratory and histopathologic data of these 20 patients and 24 liver biopsies were reviewed. Impact of the histopathological diagnosis on subsequent patient management was also obtained from the clinical records. Details regarding patient characteristics, primary disease, conditioning regimens and treatment modifications made after histopathologic diagnosis are shown in Table 1. GVHD prophylaxis consisted of CsA and MTX. Liver function tests and hepatobiliary ultrasound were performed in every HSCT patient and were within the normal reference ranges prior to conditioning. Hepatitis B and hepatitis C viruses in the donors were negative for all 20 patients undergoing liver biopsy. Hepatitis B Ag and hepatitis C Ab positivity were seen in 2 (1 each) patients among the 20 requiring biopsy (5% each). The frequency of Hepatitis B was 3.2% for hepatitis B and 0.5% for hepatitis C in the population of 187 patients who did not require liver biopsy post-HSCT.

Liver biopsy

Liver biopsies were performed on the decision of the attending physician. However, according to institutional standard practice, a liver biopsy is performed when one or more of the liver enzymes: alanine aminotransferase (ALT), aspartate aminotransferase (AST), γ-glutamyle transferase (GGT) and alkaline phosphatase (ALP) are persistently or progressively elevated in 2 weeks of follow-up. At least one of the liver enzymes was persistently high in the 20 patients described. The mean ALT level was 237.5 ± 216.1 U/l, AST 130.5 ± 143.4 IU/l, GGT 206.5 ± 211.1 IU/l and ALP 255.1 ± 306.4 IU/l. We refrained from performing a liver biopsy in patients with transient enzyme abnormalities and when the cause of the elevated liver enzymes was apparent and due to drug toxicity, SOS/VOD, viral hepatitis or reactivation of a previous hepatitis or overt GVHD. Hepatobiliary ultrasound, molecular viral markers including hepatitis B, C, CMV, herpes simplex virus (HSV), adenovirus and parvovirus were performed on detection of liver abnormalities. The biopsy procedure was conducted percutaneously under ultrasound guidance with a platelet count over 50×10^9 per liter and normal hemostatic parameters.

All biopsy specimens were fixed in 10% formalin and stained with hemotoxylin-eosin. Serial sections from each biopsy were examined, and Masson's trichrome for fibrotic stage and Prussian blue for hemosiderin deposition were used. Furthermore, immunohistochemical methods for hepatitis B surface/core Ags and CMV inclusions were performed when needed. A diagnosis of GVHD was given using the following criteria: mixed portal inflammation including eosinophils and activated lymphocytes, endothelitis and bile duct injury with lymphocytic permeation of duct epithelia, cytoplasmic vacuolization, nuclear loss, centrizonal hepatocyte necrosis, apoptosis and cholestasis. Hemosiderin deposition, both in hepatocytes and parenchymal/portal macrophages, was evaluated and graded as mild, moderate or severe according to following criteria: hemosiderin deposition visible at $\times 40$ magnification and in 25% of hepatocytes, at $\times 20$ magnification and in 50% of hepatocytes, at $\times 10$ magnification and more than 50% of hepatocytes, respectively. Specimens showing marked portal lymphocytic inflammation, interface hepatitis in addition to paranchymal necrosis were investigated immunohistochemically for possible viral hepatitis. Biopsies with none to mild portal inlammation with scattered hepatocyte necrosis and sinusoidal inflammation were categorized as nonspecific.

Treatment of elevated liver enzymes was carried out either according to the clinical or histopathologic diagnosis with corticosteroids ± intensifying current immunosupressive agents for GVHD, defibrotide for SOS/VOD, withdrawing the drugs suspected of interfering with hepatic functions and iron chelation in patients with IO. Informed consent was obtained from all patients and this retrospective study was approved by the institutional board of Gazi University Medical School.

Statistical analysis

Differences between groups were analyzed by the Student's *t*-test or Mann–Whitney *U*-test for continuous variables, and the χ^2-test for categorical variables. Relations between variables were evaluated with Pearson's or Spearman's correlation tests. A value of $P<0.05$ was considered to represent a statistically significant difference. Survival analysis was carried out by using Kaplan–Meier and logrank tests. Analysis of the data was performed using SPSS for Windows V. 11.5 (SPSS Inc., Chicago, IL, USA).

Results

Elevated liver enzymes at some point post-HSCT were seen in 95.6% of patients receiving allogeneic and 89.3% of patients receiving autologous HSCT. A total of 24 liver biopsies were required in 20 patients. The time interval from allogeneic SCT to liver biopsy ranged from 11 to 955 days (median 211), and the median platelet count on the day of biopsy was 145 500 per μl (52 200–253 000). One patient had a hemorrhage after liver biopsy, which was treated conservatively with blood transfusions. There was no biopsy-related mortality.

Three patients had more than one liver biopsy. Repeating biopsies were included in the analysis as the second and third biopsies performed during different episodes of elevated liver enzymes with usually a different histopathologic diagnosis and at least 6 months apart (Table 1).

A definite histopathologic diagnosis was obtained from 22 of the 24 biopsies (91.7%). The liver biopsy was nondiagnostic in two cases (8.3%). The most common histologic diagnosis was IO, which was documented in 18 of the 24 biopsy specimens (75%). IO was the sole histopathologic abnormality in 8 of the 24 (33.3%) biopsy specimens and 13 of the 24 biopsies were diagnosed with GVHD (54.2%). Concomitant IO and GVHD were present in eight biopsies (33.3%), whereas only one biopsy (4.2%) showed IO and chronic hepatitis B infection, and one

Table 1 Patient characteristics, liver function tests and management of the patients who had undergone liver biopsy

Patient no., age, gender, diagnosis	*CR*	*Bx time*	*ExH GVHD*	*IO*	*HGVHD*	*TS (%)*	*Ferritin (ng/ml)*	*AST (IU/l)*	*ALT (IU/l)*	*ALP (IU/l)*	*GGT (IU/l)*	*T.bil (mg per 100 ml)*	*Drugs used at the time of the biopsy*	*Treatment modification*
No. 1, 20, M, AML	TBI/Cy	+217	None	None	(+)	39	43.9	103	171	78	17	0.1	CsA, ACV, TMP/SMX, UDCA	↑ the dose of CsA
No. 2, 52, M, AML	Bu/Cy	+306	None	None	(+)	43	1649	97	189	138	63	0.3	ACV, TMP/SMX	MP + MMF
No. 3, 19, M, CML	Bu/Cy	+278	None	None	(+)	8	11.9	87	103	122	28	0.6	CsA, ACV, TMP/SMX, STI-571	↑ the dose of CsA
No. 4, 22, F, HD	Bu/Cy/Flu	+128	None	None	(−)	19	274.9	58	83	244	87	0.1	CsA, ACV, TMP/SMX	No specific treatment
No. 5, 30, F, HD	Flu/TBI	+63	Oral	None	(−)	38	300	97	139	90	182	1.3	CsA, ACV, TMP/SMX, FLC	No specific treatment
No. 6, 41, F, MM	Flu/TBI	+96	None	None	(+)	11	51	72	142	200	476	0.5	CsA, ACV, TMP/SMX, VFX, F, T	MP + ↑ the dose of CsA
No. 7, 21, M, HD	Bu/Cy/Flu	+314	Oral	3	(−)	88	2000	132	865	1613	1008	1.0	MMF, LAM, VCV, TMP/SMX, UDCA, FLC	DFO
No. 8/I, 26, M, ALL	TBI/Cy	+52	None	1	(−)	45	5308	49	46	199	250	1.7	CsA, ACV, TMP/SMX, FLC, CT, H, VPA	No specific treatment
No. 8/II, 26, M, ALL	TBI/Cy	+389	None	2	(−)	100	1047	171	248	250	100	1.4	ACV, TMP/SMX, UDCA	DFO
No. 9, 43, M, AML	Bu/Cy	+159	None	3	(+)	57	2000	76	141	369	125	0.4	CsA, ACV, TMP/SMX	↑ the dose of CsA + DFO
No. 10, 45, M, AML	Bu/Cy	+205	None	1	(+)	22	1104	84	175	82	25	0.5	CsA, ACV, TMP/SMX, UDCA	MP + ↑ the dose of CsA
No. 11/I, 47, M, AML	Bu/Cy	+93	None	2	(−)	5	1816	38	89	170	214	0.5	CsA, ACV, TMP/SMX, CT, ALLO	No specific treatment
No. 11/II, 47, M, AML	Bu/Cy	+328	None	2	(+)	64	1392	40	89	170	214	0.4	CsA, ACV, TMP/SMX, CT	↑ the dose of CsA
No. 12/I, 31, M, AML	Bu/Cy	+428	None	3	(+)	95	1130	67	138	147	82	0.1	CsA, ACV, TMP/SMX	↑ the dose of CsA + DFO
No. 12/II, 31, M, AML	Bu/Cy	+767	None	1	(−)	83	389	80	146	136	80	0.4	CsA, ACV, TMP/SMX	No specific treatment
No. 12/III, 31, M, AML	Bu/Cy	+955	None	1	(+)	36	257	700	745	295	294	0.5	CsA, ACV, TMP/SMX, UDCA	MP
No. 13, 28, F, SAA	ATG/Cy	+89	None	3	(+)	90	4987	45	66	211	235	0.7	CsA, GCV, TMP/SMX, FLC, EP	MP + DFO
No. 14, 26, F, AML	Bu/Cy	+835	None	1	(+)	23	298	370	343	129	217	0.3	CsA, ACV, TMP/SMX	MP
No. 15, 33, F, NHL	Bu/Cy/Flu	+49	Skin	2	(−)	28	10 262	176	333	177	114	3.0	CsA, ACV, TMP/SMX, AMB, ET, SL, LOR	DFO
No. 16, 18, M, AML	Bu/Cy	+184	Oral	1	(−)	90	2000	15	125	161	50	0.5	VCV, TMP/SMX, CT, VRC	No specific treatment
No. 17, 17,M,ALL	TBI/Cy	+133	None	1	(+)	43	306	211	269	532	359	2.7	CsA, ACV, TMP/SMX, ALLO	MP
No. 18, 21, F, ALL	Bu/Cy	+321	Skin	2	(−)	26	648	135	501	204	392	0.2	MMF, VCV, TMP/SMX, UDCA, INH	No specific treatment
No. 19, 19, M, SAA	Cy	+252	None	2	(+)	91	1500.9	191	509	109	71	2.1	CsA, ACV, UDCA	MP
No. 20[a], 30, M, HD	BEAM	+11	None	3	(−)	93	3800.7	39	47	296	274	4.1	LOR, UDCA, CT, T, F, SL, MTZ, ACV	Patient denied DFO

Abbreviations: ACV = acyclovir; ALL = acute lymphoblastic leukemia; ALLO = allopurinol; ALP = alkaline phosphatase; ALT = alanine transaminase; AMB = amphoterisin B; AML = acute myeloblastic leukemia; AST = aspartate transaminase; BEAM = BCNU = etoposide = cytosine arabinoside = melphalan; Bu = busulfan; Bx time = time of the biopsy; CML = chronic myeloid leukemia; CR = conditioning regimen; CsA = cyclosporin A; CT = citalopram; Cy = cyclophosphamide; DFO = desferroxamine; EP = estrogen–progestin; ExH GVHD = extrahepatic graft-versus-host disease; F = fentanyl; FLC = fluconazole; Flu = fludarabine; GCV = gancyclovir; GGT = γ-glutamyl transferase; H = hydantoin; HD = Hodgkin's disease; H GVHD = Hepatic graft-versus-host disease; INH = isoniazide; IO = iron overload; LAM = lamivudine; LOR = lorazepam; MM = multiple myeloma; MMF = mycophenolate mofetil; MP = methyl prednisolone; MTZ = metronidazole; NHL = non-Hodgkin lymphoma; SAA = severe aplastic anemia; SL = spironolactone; STI-571 = imatinib mesylate; T = tramadol; TBI = total body irradiation; T.bil = total bilirubin; TMP/SMX = trimethoprim sulphamethoxazole; TS = transferrin saturation; UDCA = ursodeoxycholic acid; VCV = valacyclovir; VFX = venlafaxine; VPA = valproate; VRC = voriconazole.
[a]Autologous SCT.

biopsy showed concomitant chronic hepatitis C, IO and GVHD. None of the biopsies revealed evidence of fibrosis or cirrhosis. Histopathology of the liver biopsies is shown in Table 2.

Liver biopsies of the five allogeneic HSCT recipients who had abnormal liver function tests and clinical signs of extrahepatic (limited, skin and/or oral) GVHD and who did not require systemic GVHD treatment in the abscence of hepatic GVHD showed no evidence of hepatic GVHD on histologic examination. Of 14 patients who had a ferritin level higher than 1000 ng/ml, 13 had histologically proven IO.

GVHD was the initial clinical diagnosis in all the allogeneic HSCT recipients with elevated liver enzymes. However, 43.5% (10/23) of these biopsies from allogeneic HSCTs showed no signs of GVHD on histologic examination, whereas 56.5% of the biopsies showed GVHD. In 33.3% of the patients IO was the only histopathologic finding. IO was mild in seven biopsies (38.9%), moderate in six biopsies (33.3%) and severe in five biopsies (27.8%).

Mean ferritin levels, percent transferrin saturation (TS), number of transfusions and inflammation markers of the patients with, and without hepatic IO are shown in Table 3. The median number of post transplantation packed red cell transfusions in patients who had histologically proven hepatic IO was 13 units (0–68), whereas it was 2 (1–9) units in patients without hepatic IO ($P=0.007$). The median number of platelet transfusions in patients who had histologically proven hepatic IO was 12 units (1–29), whereas it was 4.5 (1–9) units in patients without hepatic IO ($P=0.007$). The TS was found to be higher in patients with histologically proven IO (mean $59.9\pm31.7\%$) when compared to patients without IO (mean $26.3\pm15.5\%$; $P=0.003$). Serum ferritin levels were significantly higher in patients with hepatic IO (2235.9 ± 2505.5 ng/ml) compared to patients without hepatic IO (388.5 ± 630.0 ng/ml; $P=0.009$). C-reactive protein, albumin and fibrinogen levels, as markers of inflammation were not different in patients with, or without IO. Degree of hepatic iron was positively correlated with ferritin ($P<0.001$, $r=0.673$), percent TS ($P=0.003$, $r=0.579$), and number of packed red cells transfused ($P=<0.027$, $r=0.452$), and negatively

Table 2 Histopathologic results of liver biopsies

Histopathologic diagnosis of liver biopsies	N *(%)* N = *24*
Iron overload	8 (33.3)
GVHD	4 (16.7)
Iron overload + GVHD	8 (33.3)
Iron overload + hepatitis B	1 (4.2)
Iron overload + hepatitis C + GVHD	1 (4.2)
Iron overload (overall)	18 (75)
GVHD (overall)	13 (54.2)
Nondiagnostic	2 (8.3)

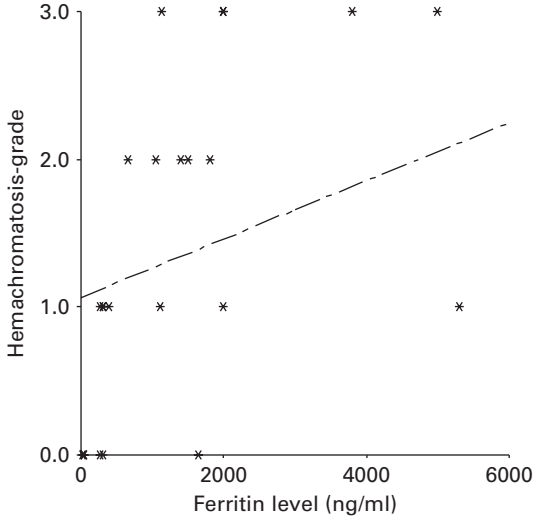

Figure 1 Degree of iron overload (IO) in the liver biopsy was positively correlated with ferritin levels.

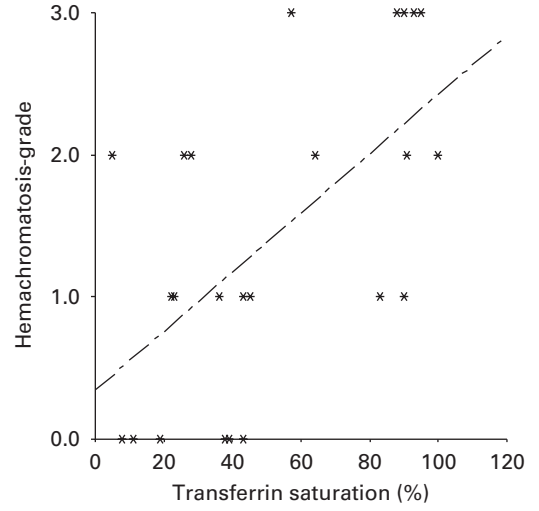

Figure 2 Degree of iron overload (IO) in the liver biopsy was positively correlated with transferrin saturation.

Table 3 The biochemical parameters and transfusion data of patients with and without iron overload

	Without hepatic iron overload (n = *6*)	*With hepatic iron overload* (n = *18*)	P-*values*
Ferritin (ng/ml)	388.5 ± 630.0	2235.9 ± 2505.5	**0.009**
Transferrin saturation (%)	26.3 ± 15.5	59.9 ± 31.7	**0.003**
CRP (g/l)	2.8 ± 4.6	16.7 ± 37.9	>0.05
Fibrinogen (mg per 100 ml)	326.3 ± 121.2	322.7 ± 106.3	>0.05
Albumin (g per 100 ml)	4.6 ± 0.2	4.4 ± 0.4	>0.05
Transfused packed red cells	2 (1–9)	13 (0–68)	**0.007**
Transfused platelets[a]	4.5 (1–9)	12 (1–29)	**0.007**

Bold values are statistically significant.
[a]Single donor apheresis.

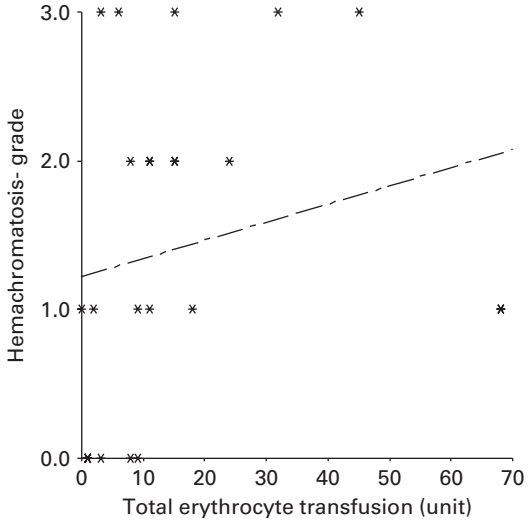

Figure 3 Degree of iron overload (IO) in the liver biopsy was positively correlated with total number of packed red cell transfusions.

correlated with serum albumin level ($P = 0.05$, $r = -0.396$) on a simple correlation analysis (Figures 1–3). Only the positive correlation between degree of hepatic iron content and serum ferritin levels remained significant by regression analysis ($P = 0.043$, R^2: 0.45).

Ferritin values above 500 ng/ml were seen in 26.2% of the autologous and 66.7% of the allogeneic HSCT patients. Ferritin values were above 500 ng/ml in 62.5% of the 20 patients at the time of liver biopsy. Positive and negative predictive values of ferritin levels in reflecting hepatic IO were calculated as 93.3 and 44% for levels of ferritin >500 ng/ml.

The probability of survival was 61.3% in patients who required liver biopsy and 38.8% in patients who did not, without statistical significance. The median follow-up period was 462 days (106–1520) and 217 days (1–1565), respectively.

Discussion

Liver dysfunction is a very common complication of allogeneic HSCT and is reported in 50–84.2% of patients.[3–12] Hepatic toxicity due to chemotherapy and radiotherapy, SOS/VOD, total parenteral nutrition, GVHD, sepsis, reactivation of viral hepatitis, CMV and IO are the most common causes of the abnormalities in liver function tests (LFTs).[6,7,12–15] Although the cause of the hepatic dysfunction is usually diagnosed by clinical and laboratory features, liver biopsy is required in patients with uncertain and/or overlapping etiology. We performed 24 percutaneous liver biopsies, median 211 days after HSCT in 20 patients. All except one of our patients who required liver biopsy had undergone allogeneic HSCT, in accordance with previous reports in the literature.[3,16] Percutaneous liver biopsy is an invasive but relatively safe diagnostic procedure in patients with normal hemostasis tests and platelet counts above 50×10^9 per liter.[8] The percutaneous route was preferred in our patient cohort, as majority of the biopsies were obtained in the late post transplantation period when platelet counts were normal. A complication rate below 5% with a histopathologic diagnostic yield of 91.7% in our patient cohort indicates that percutaneous liver biopsy is a relatively safe and effective diagnostic procedure in the late stages of HSCT. In 43.5% of our patients histopathologic diagnosis brought about a change in the management of patients, mainly by withholding steroids and immunosuppresive agents. Similarly, in a recent report by Chahal *et al*.,[17] liver biopsy was performed in 61 consecutive patients out of 1700 HSCT and histopathologic diagnosis led to a change in management in 37% of their patients.

The majority of the liver biopsies showed GVHD and/or IO in the present study which is in accordance with the literature.[3,6,18–21] The median post transplant day of liver biopsy was day + 211 which accounts for the late post transplant period and explains why IO and GVHD are the most common histopathologic diagnosis rather than SOS/VOD, drug toxicity or hepatitis lenta which is seen in the earlier periods of HSCT. Whereas 75% of the biopsies showed histopathologic evidence of IO, 54.2% of the patients showed GVHD. Chronic GVHD was excluded on histopathologic diagnosis in 43.5% of the patients and avoided unnecessary corticosteroid treatment which could have increased morbidity and mortality. In 56.5% of the allogeneic patients either corticosteroids were commenced or immunosuppressive treatment was intensified with the histopathologic confirmation of GVHD. Ho *et al*.,[3] reported liver histology consistent with IO in 84% of a selected group of their HSCT patients and the degree of hepatic IO correlated with elevated levels of ferritin and TS. The role of IO as the the actual cause of elevated liver enzymes could be questioned. Moreover, IO may be equally prevelant in patients with normal aminotransferase activity, as the fibrogenic process induced by iron is associated with little cell damage and inflammation often with borderline or even normal transaminase levels.[22] However, in a recent report 'IO-related disease' has been defined as documented IO and one or more of the following conditions: cirrhosis, liver fibrosis, hepatocellular carcinoma, elevated aminotransferase levels (AST: >45 IU/l, ALT: >40 IU/l), physician diagnosed symptomatic hemochromatosis and arthropathy of the second and third metacarpophalengeal joints.[23] Thus, elevated transaminases appear to be related IO in the HSCT patients described.

Serum ferritin levels were above normal in 128 (64%) and above 1000 ng/ml in 69 (35%) of our 207 patients. High serum ferritin levels were more frequent among allogeneic HSCT patients at 79.8%, compared to autologous patients with a rate of 47.1%. McKay *et al*.,[24] found elevated serum ferritin levels in 88% of their patients at least 1 year post-HSCT. Ferritin levels and TS values were significantly higher in our patients with histopathologic evidence of hepatic IO, compared to those without IO (Table 3). Serum ferritin levels were positively correlated with hepatic IO on regression analysis, and the positive predictive value of ferritin levels >500 ng/ml in reflecting hepatic IO was calculated as 93.3% and the negative predictive value was 44%. Serum ferritin levels appeared to be important in predicting cases with hepatic IO and degree of hepatic iron

content. Elevated serum ferritin levels have also recently been suggested as a test in predicting hepatic cirrhosis in patients with hemochromatosis. Waalen *et al*.,[25] found 59 patients with ferritin levels above 1000 ng/ml among 29 699 white subjects that they screened. A total of 40% of these 59 patients were found to have hereditary hemochromatosis, whereas only 5% of these patients had elevated liver enzymes, which suggests that ferritin might be a better marker than elevated transaminases in predicting hepatic IO.

Our data suggest that the number of transfusions is a contributing factor causing IO. However, the amount of iron transfused by blood products *per se* does not explain the IO of the patients. Patients with IO might already be a high-risk population that requires a higher number of transfusions. It should also be noted that transfusions are by no means the only cause of IO in patients with hematologic malignancies treated with, or without HSCT. Decreased utilization of iron due to ineffective erythropoiesis, release of iron from the injured tissues, increased intestinal absorption of iron secondary to mucositis and GVHD,[26] HFE mutations, abnormalities in hepcidin regulation are the other possible causes of IO in patients with hematologic malignancies and HSCT.[4,7,26,27]

IO has important short- and long-term consequences. Free iron in the plasma is very toxic to tissues as it acts as a catalyst in the formation of hydroxyl radicals and peroxidation of lipid membranes.[18,21,24,28–30] Previous reports have documented an association between mucositis, opportunistic infections including aspergillus and mucor mucosis, febrile days, GVHD, SOS/VOD, hepatitis C and finally survival.[1,19,26,31–35] Patients with hemachromatosis have an increased incidence of cirrhosis, hepatocellular carcinoma and some other malignancies.[35–40] Similarly, CLD is one of the major long-term complications in HSCT survivors. Whereas Strasser *et al*.,[4] reported a cumulative incidence of CLD in 3.8% by 20 years after transplantation in a series of 3721 patients, Tomas *et al*.,[6] reported CLD in 57.5% of their cohort of 106 patients in 2 years follow-up, which strongly correlated with siderosis. They showed a dramatic improvement in LFTs with phlebotomy in patients with IO and hepatitis C. Azar *et al*.,[14] reported that the only parameter which predicted liver injury in their 25 HSCT recipients was IO, whereas Angelucci *et al*.,[35] found that the risk for progression of liver disease after HSCT strongly correlated with siderosis. Iqbal *et al*.,[2] found varying degrees of IO in 81.25% of the HSCT patients undergoing laparoscopic liver biopsy in earlier phases of HSCT. Hepatic IO, besides fibrotic and cirrhotic potential, changes the natural course of viral hepatitis and its response to treatment and might also precipitate or mimic GVHD.[4,26,27,35] In this respect, we suggest that strategies which modify pre- or post transplantation IO in HSCT recipients might improve complication rates and survival.

In conclusion, liver biopsy has changed the management of a substantial number of our patients, indicating the essential role of liver biopsy in HSCT recipients with elevated liver enzymes. Our data suggest that hepatic IO is a frequent histopathologic finding among HSCT recipients with elevated liver enzymes, whereas GVHD seems to be overestimated in the same population. The significant correlation with hepatic IO, and serum ferritin levels warrants validation of the role of ferritin as a surrogate marker of hepatic IO in HSCT recipients. Treatment of IO with phlebotomy and/or iron chelators in the post transplant setting should also be investigated in prospective studies.

References

1 Armand P, Kim HT, Cutler CS, Ho VT, Koreth J, Alyea EP *et al*. Prognostic impact of elevated pretransplant serum ferritin in patients undergoing myeloablative stem cell transplantation. *Blood* 2007; **109**: 4586–4588.
2 Iqbal M, Creger RJ, Fox RM, Cooper BW, Jacobs G, Stellato TA *et al*. Laparoscopic liver biopsy to evaluate hepatic dysfunction in patients with hematologic malignancies: a useful tool to effect changes in management. *Bone Marrow Transplant* 1996; **17**: 655–662.
3 Ho GT, Parker A, MacKenzie JF, Morris AJ, Stanley AJ. Abnormal liver function tests following bone marrow transplantation: aetiology and role of liver biopsy. *Eur J Gastroenterol Hepatol* 2004; **16**: 157–162.
4 Strasser SI, Sullivan KM, Myerson D, Spurgeon CL, Storer B, Schoch HG *et al*. Cirrhosis of the liver in long term marrow transplant survivors. *Blood* 1999; **93**: 3259–3266.
5 El Sayed MH, El-Haddad A, Fahmy OA, Salama II, Mahmoud HK. Liver disease is a major cause of mortality following allogeneic bone marrow transplantation. *Eur J Gastroenterol Hepatol* 2004; **16**: 1347–1354.
6 Tomas JF, Pinilla I, Garcia-Buey ML, Garcia A, Figuera A, Gomez-Garcia de Soria V *et al*. Long term liver dysfunction after allogeneic bone marrow transplantation: clinical features and course in 61 patients. *Bone Marrow Transplant* 2000; **26**: 649–655.
7 McDonald GB. Review article: management of hepatic disease following haematopoietic cell transplant. *Aliment Pharmacol Ther* 2006; **24**: 441–452.
8 Choi SW, Islam S, Greenson JK, Levine J, Hutchinson R, Yanik G *et al*. The use of laparoscopic liver biopsies in pediatric patients with hepatic dysfunction following allogeneic hematopoietic stem cell transplantation. *Bone Marrow Transplant* 2005; **36**: 891–896.
9 Ma SY, Au WY, Ng IOL, Lie AKW, Leung AYH, Liang RHS *et al*. Role of liver biopsy in the management of liver dysfunction after hematopoietic stem cell transplantation in a hepatitis B virus prevalent patient population. *Transplantation* 2003; **76**: 169–176.
10 Harrison P, Neilson JR, Marwah SS, Madden L, Bareford D, Milligan DW. Role of non transferrin bound iron in iron overload and liver dysfunction in long term survivors of acute leukaemia and bone marrow transplantation. *J Clin Pathol* 1996; **49**: 853–856.
11 Veneri D, Franchini M, Zanetti F, Krampera M, Matteis G, Pizzolo G. Iron overload in acute myeloid leukemia patients is not related to HFE and TFR2 gene mutations. *Haematologica* 2003; **88**: 1069–1070.
12 Kim BK, Chung KW, Sun HS, Suh JG, Min WS, Kang CS *et al*. Liver disease during the first posttransplant year in bone marrow transplantation recipients: retrospective study. *Bone Marrow Transplant* 2000; **26**: 193–197.
13 Kusumi E, Kami M, Kanda Y, Murasbige N, Seki K, Fujiwara M *et al*. Hepatic injury following reduced intensity unrelated cord blood transplantation for adult patients with hematological diseases. *Biol Blood Marrow Transplant* 2006; **12**: 1302–1309.

14 Azar N, Valla D, Abdel-Samad I, Hoang C, Fretz C, Sutton L *et al*. Liver dysfunction in allogeneic bone marrow transplantation recipients. *Transplantation* 1996; **62**: 56–61.
15 Özdoğan O, Ratip S, Al Ahdab Y, Dane F, Al Ahdab H, İmeryüz N *et al*. Causes and risk factors for liver injury following bone marrow transplantation. *J Clin Gastroenterol* 2003; **36**: 421–426.
16 Subbarao G, Haut PR, Johnson CS, Gowan D, Molleston JP. Incidence, etiology and risk factors for liver dysfunction in children following hematopoietic stem cell transplantation. *Pediatr Transplant* 2006; **10**: 682–689.
17 Chahal P, Levy C, Litzow MR, Lindor KD. Utility of liver biopsy in bone marrow transplant patients. *J Gastroenterol Hepatol* 2008; **23**: 222–225.
18 Evens AM, Mehta J, Gordon LI. Rust and corrosion in hematopoietic stem cell transplantation: the problem of iron and oxidative stress. *Bone Marrow Transplant* 2004; **34**: 561–571.
19 Miceli MH, Dong L, Grazziutti ML, Fassas A, Thertulien R, Van Rhee F *et al*. Iron overload is a major risk factor for severe infection after autologous stem cell transplantation: a study of 367 myeloma patients. *Bone Marrow Transplant* 2006; **37**: 857–864.
20 Lichtman SM, Attivissimo L, Goldman IS, Schuster MW, Buchbinder A. Secondary hemochromatosis as a long term complication of the treatment of hematologic malignancies. *Am J Hematol* 1999; **61**: 262–264.
21 Strasser SI, Kowdley KV, Sale GE, McDonald GB. Iron overload in bone marrow transplant recipients. *Bone Marrow Transplant* 1998; **22**: 167–173.
22 Poli G. Pathogenesis of liver fibrosis: role of oxidative stress. *Mol Aspects Med* 2000; **21**: 49–98.
23 Allen KJ, Gurrin LC, Constantine CC, Osborne NJ, Delatycki MB, Nicoll AJ *et al*. Iron overload-related disease in HFE hereditary hemochromatosis. *N Engl J Med* 2008; **358**: 221–230.
24 McKay PJ, Murphy JA, Cameron S, Burnett AK, Camphell M, Tansey P *et al*. Iron overload and liver dysfunction after allogeneic and autologous bone marrow transplantation. *Bone Marrow Transplant* 1996; **17**: 63–66.
25 Waalen J, Felliti VJ, Gelbart T, Beutler E. Screening for hemachromatosis by measuring ferritin levels: a more effective approach. *Blood* 2008; **111**: 3373–3376.
26 Kamble RT, Selby GB, Mims M, Kharfan-Dabaja MA, Özer H, George JN. Iron overload manifesting as apparent exacerbation of hepatic graft versus host disease after allogeneic hematopoietic stem cell transplantation. *Biol Blood Marrow Transplant* 2006; **12**: 506–510.
27 Socie G, Salooja N, Cohen A, Rovelli A, Carreras E, Locasciulli A *et al*. Nonmalignant late effects after allogeneic stem cell transplantation. *Blood* 2003; **101**: 3373–3385.
28 Dürken M, Nielsen P, Knobel S, Finckh B, Herrnring C, Dresow B *et al*. Nontransferrin-bound iron in serum of patients receiving bone marrow transplants. *Free Rad Biol Med* 1997; **22**: 1159–1163.
29 Sahlstedt L, Ebeling F, Von Bonsdorff L, Parkkinen J, Ruutu T. Non-transferrin bound iron during allogeneic stem cell transplantation. *Br J Haematol* 2001; **113**: 836–838.
30 Gordon LI, Brown SG, Tallman MS, Rademaker AW, Weitzman SA, Lazarus HM *et al*. Sequential changes in serum iron and ferritin in patients undergoing high dose chemotherapy and radiation with autologous bone marrow transplantation: possible implications for treatment related toxicity. *Free Rad Biol Med* 1995; **18**: 383–389.
31 Morado M, Ojeda E, Garcia Bustos J, Aguado MJ, Arrieta R, Quevedo E *et al*. Serum ferritin as a risk factor for veno-occlusive disease of the liver. Prospective cohort study. *Hematology* 2000; **6**: 505–512.
32 Maertens J, Demuynck H, Verbeken EK, Zachee P, Verhoef GEG, Vandenberghe P *et al*. Mucormycosis in allogeneic bone marrow transplant recipients: report of five cases and review of the role of iron overload in the pathogenesis. *Bone Marrow Transplant* 1999; **24**: 307–312.
33 Altes A, Remacha AF, Sadra P, Sancho FJ, Sureda A, Martino R *et al*. Frequent severe liver iron overload after stem cell transplantation and its possible association with invasive aspergillosis. *Bone Marrow Transplant* 2004; **34**: 505–509.
34 Altes A, Remacha AF, Sadra P, Baiget M, Sureda A, Martino R *et al*. Early clinical impact of iron overload in stem cell transplantation. A prospective study. *Ann Hematol* 2007; **86**: 443–447.
35 Angelucci E, Muretto P, Nicolucci A, Baronciani D, Erer B, Gaziev J *et al*. Effects of iron overload and hepatitis C virus positivity in determining progression of liver fibrosis in thalassemia following bone marrow transplantation. *Blood* 2002; **100**: 17–21.
36 Kallianpur AR, Hall LD, Yadav M, Christman BW, Dittus RS, Haines JL *et al*. Increased prevalance of the HFE C282Y Hemochromatosis allele in women with breast cancer. *Cancer Epidemiol* 2004; **13**: 205–212.
37 Barton JC, Bertoli LF, Acton RT. HFE C282Y and H63D in adults with malignancies in a community medical oncology practice. *BMC Cancer* 2004; **4**: 1–8.
38 Carreras E. Risk assessment in haematopoietic stem cell transplantation: the liver as a risk factor. *Best Pract Res Clin Haematol* 2007; **20**: 231–246.
39 Varkonyi J, Tarkovacs G, Karadi I, Andrikovics H, Varga Fe, Varga Fa *et al*. High incidence of hemochromatosis gene mutations in the myelodysplastic syndrome: the Budapest study on 50 patients. *Acta Haematol* 2003; **109**: 64–67.
40 Ko C, Siddaiah N, Berger J, Gish R, Brandhagen D, Sterling RK *et al*. Prevalence of hepatic iron overload and association with hepatocellular cancer in end-stage liver disease: results from the National Hemochromatosis Transplant Registry. *Liver Int* 2007; **27**: 1394–1401.