Bratislava Medical Journal
https://doi.org/10.1007/s44411-026-00581-7

RESEARCH

Recovery Effects of Resveratrol and Berberine Against Inflammation, Oxidative Stress, Biochemical, and Pathological Damage in Rats with Imidacloprid-Induced Hepatorenal Toxicity

Hatice Karaboduk[1] · Caglar Adiguzel[1] · Fatma Gokce Apaydin[1] · Yusuf Kalender[1]

Received: 24 September 2025 / Revised: 24 December 2025 / Accepted: 15 March 2026
© The Author(s) 2026

Abstract
Imidacloprid (IMI) is a neonicotinoid insecticide which can cause toxic effects in many non-target organisms. The aim of this study is to investigate the effects of resveratrol (RES; 20 mg/kg body weight) and berberine (BBR; 100 mg/kg body weight) on the liver and kidney tissues of rats induced with IMI in terms of oxidative, biochemical, immunohistochemical, and histopathological effects. For this purpose, 42 rats were divided into seven equal groups and the test substances were administered orally for 28 days. An increase in MDA levels was observed in the liver and kidney tissues of rats treated with IMI, while a decrease was observed in antioxidant enzyme activities (SOD, CAT, GPx, GST). Additionally, changes occurred in liver (AST, ALT, ALP, LDH) and kidney (BUN, creatinine, urea, uric acid) function markers. A decrease in TAS levels was observed in IMI treated rats, while an increase in TOS levels was observed. Furthermore, a significant increase in IL-17, 8-OHdG levels, TNF-α, and caspase-3 immunoreactivity, and a decrease in AChE activity were detected. Histopathological examinations revealed hepatocyte degeneration, sinusoidal dilatation, and cellular infiltration in the liver, while tubular degeneration and congestion were detected in the kidney. Co-treatment with IMI plus RES and/or BBR resulted in a significant amelioration of oxidative stress, inflammatory responses, and biochemical alterations in rat liver and kidney tissues. In this study, the toxic effects of IMI were further reduced when RES and BBR were administered together. Therefore, it can be stated that RES and BBR exhibit a synergistic effect.

Keywords Antioxidants · Apoptosis · Histopathology · Immunohistochemistry · Insecticides · Oxidative stress

1 Introduction

The assessment of potential toxic effects of pesticides, especially insecticides, is becoming increasingly important due to their widespread use in veterinary practice and agricultural control [1]. Imidacloprid is considered a prototypical neonicotinoid insecticide, which is well-known for targeting the nicotinic acetylcholine receptor (NAcR) in insects, with potential implications for mammal species [2]. Imidacloprid (IMI; N-{1-[(6-chloro-3-pyridyl) methyl]-4,5-dihydroimidazol-2 yl} nitramide), a chloronicotinyl neonicotinoid, belongs to a new class of systemic pesticides and is the most important member of this group. Only in the last decade has it been used commercially [3]. As with most pesticides, one of the toxic effects of IMI is on acetylcholinesterase (AChE) activity. This leads to excessive stimulation of nicotinic acetylcholine receptors (nAChR) and results in cholinergic effects and altered neurotransmission. Depending on the amount of substance administered, this can lead to nervous stimulation, paralysis, and death [4, 5]. IMI can cause many acute and chronic toxic damages, including reproduvtive toxicity [6], neuronal cell dysfunction [7], adverse developmental effects [8]. It is also known to cause neuroendocrinological disorders by inducing the transcription of nitric oxide synthase isoforms at the molecular level and by leading to thyroid-disrupting effects [9, 10].

A number of studies have demonstrated the protective or ameliorative effects of antioxidants with regard to oxidative tissue damage in rats. It is thought that the protective effect is due to the radical-scavenging properties of substances such as vitamin compounds and flavonoids, such as naringenin [11]. Plant seeds, vegetables and fruits contain flavonoids,

✉ Hatice Karaboduk
haticearikan@gazi.edu.tr

[1] Department of Biology, Faculty of Science, Gazi University, 06500 Ankara, Turkey

Published online: 24 March 2026

which are phenolic substances with many beneficial properties [12, 13]. Recent studies have emphasised the healing roles of phenolic compounds on health and their protective role in cellular toxicity [11, 14]. These include many effects such as antioxidant properties and anti-inflammatory roles [12].

Resveratrol (3,5,4′-trihydroxy-trans-stilbene) is known as a polyphenolic compound. It is found in a variety of plants, such as grapes, peels, berries, pine, legumes and peanuts, which have various biological activities. There are several ways in which resveratrol works, including by altering oxidative stress, inflammation, cell death (apoptosis) and the signals that cells use to communicate with each other during tissue injury [15, 16].

The many therapeutic effects of resveratrol on experimentally-induced animal models can be attributed to its effective ameliorative properties against toxic oxygen species [17]. Many researchers have demonstrated that these activities are related to its antiviral [18], antiplatelet [19], antineoplastic [20], cardioprotective [21], and hepatoprotective properties [15], as well as its ability to protect against free radicals that cause inflammation, aging, cancer, and oxidative stress. Because of its health benefits, resveratrol has recently been recommended as a dietary supplement [16].

Berberine, an isoquinoline alkaloid isolated from various Berberis plants such as *Berberis vulgaris* (barberry) and *Berberis aristata* (tree turmeric) and the Chinese plant *Coptis chinensis*, has a variety of potent medicinal and beneficial properties [22]. Berberine has been shown to promote the activity of antioxidant enzymes both in vitro and in vivo, and has the ability to react with many xenobiotic-induced pro-oxidant reactive species. It has been shown to have therapeutic effects in cardiovascular disease, inflammatory situations, platelet aggregation, microbial infections, cancer and diabetes. These effects are attributed to its biologically active component, berberine [23–27]. Furthermore, berberine is known to have various effects such as suppressing tumors and maintaining homeostasis [28]. Studies have shown that berberine increases antioxidant enzyme activities and total thiol levels in the hypothalamus, epididymis, and testes of rats, while reducing reactive oxygen and nitrogen species and lipid peroxidation [29, 30]. Also it has been reported to regulate cellular redox balance, reduce pro-inflammatory mediators, and support the histochemical integrity of the liver and kidney of experimental rats [31].

The objective of this study was to determine the therapeutic activity of resveratrol and berberine in the prevention of imidacloprid-induced liver and kidney injury, using pathological, biochemical, and inflammatory parameters as a basis.

2 Materials and Methods

2.1 Reagents

Imidacloprid (CAS no: 138261-41-3; Bayer, Leverkusen, Germany), Resveratrol (CAS no:501-36-0; purity 98%, BLDpharm, Shangai, China) and Berberine (CAS no: 633-65-8; purity 97%, BLDpharm, Shangai, China) were obtained and used.

2.2 Animals

A total of 42 adult male Wistar albino rats, aged 12 weeks and weighing between 200 and 250 g, were sourced from the Laboratory Animal Breeding and Experimental Research Center at Gazi University. The animals were kept in designated housing under controlled environmental conditions, which included a 12-h light/dark cycle and a suitable temperature range (18–22 °C). They had access to standard laboratory feed and water ad libitum. The animal protocols employed in this research were reviewed and authorized by the Animal Ethics Committee of Gazi University (G.U.ET-23.035).

2.3 Treatment Protocol

The substances under investigation were administered to the test animals by gavage at fixed daily doses for the entire 28-day period. The study comprised 42 rats, which were allocated into seven distinct groups, each containing six rats. The administered doses of imidacloprid, resveratrol, and berberine were structured as follows through gavage (Table 1).

Table 1 Design of experimental application protocol

Groups	Treatment doses
Control group (n = 6)	1 ml/kg bw/day corn oil
Resveratrol group (RES) (n = 6)	20 mg/kg bw/day (dissolved in corn oil)
Berberine group (BBR) (n = 6)	100 mg/kg bw/day (dissolved in distilled water)
Imıdacloprid group (IMI) (n = 6)	9 mg/kg bw/day (1/50 LD_{50}) (dissolved in corn oil)
IMI plus RES group (n = 6)	9 mg/kg bw/day + 20 mg/kg bw/day
IMI plus BBR group (n = 6)	9 mg/kg bw/day + 100 mg/kg bw/day
IMI plus RES + BBR group (n = 6)	9 mg/kg bw/day + 20 mg/kg bw + 100 mg/kg bw/day

In this study, the subacute exposure dose of imidacloprid in rats was determined based on the LD_{50} value of 450 mg/kg reported by Mikolic and Karaconji [32]. The doses of resveratrol and berberine were selected based on previous research findings, which show their antioxidant effects [33, 34].

After 28 days of treatment, rats were euthanized with intramuscular ketamine and xylazine, and cardiac blood samples were collected from the rats for biochemical analysis. The dissected liver and kidney tissues were collected for comprehensive analyses, including oxidative stress, histological and immunohistochemical.

2.4 Body and Organ Weights

The body weights of the animals in all treatment groups were recorded at both the beginning and the end of the treatment period. Following dissection, liver and kidney tissues were excised and weighed. The relative organ weights (%) were then calculated as grams per 100 g of body weight.

2.5 Analysis of Oxidative Stress Biomarkers in Liver and Kidney

2.5.1 Analysis of MDA Levels and Antioxidant Enzyme Activities

Prior to conducting the oxidative stress assessments, liver and kidney tissues were initially homogenized in a potassium chloride (KCl) solution and subjected to centrifugation at 4 °C (1424 × g for 5 min). Colorimetric tests were performed on liver and kidney tissues of rats using commercially available kits. To determine superoxide dismutase (SOD) (Otto Scientific, Otto3047, Ankara, Türkiye) activity, superoxide radicals were produced using xanthine and xanthine oxidase. These radicals were reacted with 2-(4-iodophenyl)-3-(4-nitrophenol)-5-phenyltetrazolium chloride. SOD activity was measured based on the degree of inhibition of this reaction. Glutathione peroxidase (GPx) (Otto Scientific, Otto208, Ankara, Türkiye), after catalyzing the oxidation of glutathione by hydroperoxide, the formation of the reduced form of NADPH via oxidation to NADP in the presence of glutathione was observed. Subsequently, absorbance measurements were performed at 340 nm. Glutathione-S-transferase (GST) (Elabscience, E-BC-K278-S, Hubei, China) was obtained by the absorption at 340 nm of the product formed by the binding of reduced glutathione (GSH) with dinitrobenzene (CDNB). Catalase (CAT) (Elabscience, E-BC-K031-S, Hubei, China), H_2O_2 reacts with ammonium molybdate to form a yellowish complex, and the absorbance of the resulting product at 405 nm was used for determination. The malondialdehyde (MDA) (Otto Scientific, Otto1001, Ankara, Türkiye) level was determined using a method based on reaction with thiobarbituric acid (TBA) at 90–100 °C, and trichloroacetic acid was added to precipitate the protein obtained in the reaction. The precipitate obtained was centrifuged to form a pellet. The supernatant was then read at 532 nm to obtain the absorbance.

2.5.2 Analysis of Total Oxidants and Antioxidant Status

In liver and kidney tissue samples, the total antioxidant status (TAS) and total oxidant status (TOS) were quantified using standardized commercial assay kits (TAS: Cat No: RL0017; TOS: Cat No: RL0024, Rel Assay Diagnostics, Gaziantep, Türkiye). The TAS level is based on the bleaching of the characteristic color of a stable ABTS (2,2-Azinobis(3-ethylbenzothiazoline-6-sulfonic acid)) radical cation by antioxidants. For TOS levels, oxidants oxidized the iron(II) ion-o-dianisidine complex to iron(III) ion. The iron(III) ion formed a complex with xylenol orange in an acidic environment, and a color intensity measurable spectrophotometrically is associated with the total oxidant molecule. The oxidative stress index (OSI) was derived by computing the ratio of TOS to TAS, expressed as OSI (arbitrary units) = TOS (in mmol H_2O_2 equivalents per liter) divided by TAS (in mmol Trolox equivalents per liter).

2.6 Analysis of Acetylcholinesterase (AChE) Activity

Using a spectrophotometric approach based on the Ellman assay [35], AChE enzymatic activity was measured in hepatic and renal tissue samples. Acetylthiochline iodide, used as a substrate, was analyzed through the reaction of AChE with thiocholine and acetic acid. The reaction of thiocholine with 5,5-dithio-bis-(2-nitrobenzoic acid) (DTNB) was measured spectrophotometrically at 412 nm.

2.7 Analysis of Hematological Parameters

A hematology analyzer was utilized to conduct a complete blood count on rat blood samples obtained from the test animals. The analyzed parameters included hemoglobin (Hb), white blood cell count (WBC), hematocrit (Hct), red blood cell count (RBC), mean corpuscular hemoglobin concentration (MCHC), mean corpuscular hemoglobin (MCH), mean corpuscular volume (MCV), and platelet count.

2.8 Analysis of Biochemical Markers in Hepatic and Renal Function

Serum biochemical profiling was conducted via an autoanalyzer to determine lactate dehydrogenase (LDH), alkaline phosphatase (ALP), aspartate aminotransferase (AST), and alanine aminotransferase (ALT) activities. Furthermore, the analysis included quantification of total cholesterol,

triglycerides, total protein, albumin, blood urea nitrogen (BUN), urea, uric acid, and creatinine concentrations.

2.9 Analysis of 8-Hydroxy-2'-Deoxyguanosine (8-OHdG)

The concentration of oxidative DNA damage marker 8-OHdG in liver and kidney homogenates was measured with an ELISA assay (Elabscience, Cat No: E-EL-0028, Hubei, China) according to the manufacturer's standardized procedures. The sample and HRP-conjugated avidin were reacted on a plate pre-coated with 8-OHdG and then incubated. Subsequently, substrate and stop solution were added to each well, color change was observed, and absorbance was measured at 450 nm.

2.10 Analysis of IL-17 Levels

To evaluate the inflammatory response, concentrations of interleukin-17 (IL-17) in hepatic and renal tissues were quantified using commercially available enzyme-linked immunosorbent assay (ELISA) kits (BT LAB, Cat No: E0115Ra, Shanghai, China). Tissue homogenates were prepared and processed following the manufacturer's standardized protocols for accurate measurement. The sample was placed on a plate coated with IL-17 antibody, and biotinylated rat IL-17 antibody and Streptavidin-HRP were added and incubated. During the washing stage, Streptavidin-HRP was removed, substrate solution was added, and a color change was observed. Subsequently, the absorbance was measured at 450 nm.

2.11 Analysis of Insulin, Glucagon and Glucose Levels

The sample for serum insulin level (Elabscience, Cat No: E-EL-R3034, Hubei, China) and HRP-conjugated avidin were reacted on a plate pre-coated with insulin and then incubated. Subsequently, TBM substrate solution was added to each well. Finally, a stopping solution was added, the color change was observed, and absorbance was measured at 450 nm. Glucagon levels (BT-Lab, Cat No: E1066Ra, Shanghai, China) were measured using commercial kits. This kit is an enzyme-linked immunosorbent assay kit. The sample and Streptavidin-HRP were added to a plate pre-coated with rat glucagon antibody. After incubation, unbound Streptavidin-HRP was removed in the washing step, substrate solution was added, and color change was observed. After adding reaction stop solution, absorbance was measured at 450 nm. The reaction used to determine glucose levels (Otto Scientific, Catalog No: OttoBC142, Ankara, Türkiye) consisted of a mixture of glucose oxidase, glucose, and H_2O_2. Glucose levels were determined using a colorimetric method via commercial kits.

2.12 Histopathology

Hepatic and renal specimens were preserved in a 10% neutral buffered formalin solution before undergoing conventional histological processing. Following paraffin embedding, thin Sects. (5–6 µm) were prepared and subsequently stained with hematoxylin and eosin (H&E) for microscopic evaluation. Photographs were taken from the liver and kidney tissues with an integrated camera (Olympus EP50) connected to a light microscope (Olympus BX-51).

2.13 Immunohistochemistry

Deparaffinised 5–6 µm sections were taken from liver and kidney tissues embedded in paraffin blocks. The sections were passed through xylene and alcohol series and treated with 10% citrate buffer for antigen retrieval and 3% hydrogen peroxide for endogenous peroxidase. Ultra V serum block was added to the sections and kept waiting. TNF-α (bs-10802R, Bioss, Boston, USA) and Cas-3 (bs-2593R, Bioss, Boston, USA) polyclonal antibodies were then added to the tissues and incubated at + 4 °C overnight. After the sections were washed with PBS, secondary antibodies and HRP-streptavidin were added and washed again with PBS. DAB chromogen was added to the sections and lightly counterstained with Gill haematoxylin. In the final step, sections were passed through the ascending alcohol series and xylol and covered with entellan. Each experimental group was evaluated and photographed to assess the immunoreactivity of TNF alpha and Cas-3 antibodies. Immunoreactivity intensity was evaluated and analysed with Image J (1.53 k, National Institute of Health, USA) software. For Caspase-3 and TNF-α antibodies, images were taken from 10 microscopic fields from each experimental animal, a total of 60 microscopic fields from each group. Quantitative data obtained from the experiments were subjected to statistical analysis to determine intergroup variations. All image evaluations were performed by an observer blinded to the experimental groups.

2.14 Statistical Analyses

The Shapiro–Wilk test was used to determine whether the data were normally distributed. The data obtained from the experimental groups were analysed by one-way ANOVA and Tukey's post-hoc tests for multiple comparisons, using SPSS software (version 23). Statistical analyses and graphs were performed using Graph Pad Prism v8.0.2. Statistical significance was defined at $p < 0.05$.

3 Results

3.1 Body and Organ Weights

When Table 2 was evaluated in terms of body weight changes in rats, it was determined that the IMI, IMI + RES, IMI + BBR, and IMI + RES + BBR groups showed significant differences compared to the control, RES, and BBR groups ($p < 0.05$). However, no significant difference was observed between IMI and IMI + RES, IMI + BBR, IMI + RES + BBR groups. No statistically significant differences were observed in liver and kidney weights between the control group and the groups administered IMI, IMI + RES, IMI + BBR, or IMI + RES + BBR.

3.2 Biomarkers of Oxidative Stress in Hepatic and Renal Tissues

3.2.1 MDA Levels and Antioxidant Enzyme Activities

In both tissues, a statistically significant increase in MDA levels was found in the IMI group compared to the control group. Conversely, a statistically significant decrease in MDA levels was observed in the IMI + RES, IMI + BBR, and IMI + RES + BBR groups compared to the IMI group ($p < 0.05$) (Fig. 1).

Analysis of antioxidant enzyme activities in liver and kidney tissues revealed a statistically significant reduction in antioxidant enzyme activities in the IMI-treated group compared to the control. In contrast, when the IMI + RES, IMI + BBR, and IMI + RES + BBR groups were compared with the IMI group, a statistically significant increase

Table 2 Effects of imidacloprid on the body and organ weights in rats

Parameters	Groups						
	Control	RES	BBR	IMI	IMI + RES	IMI + BBR	IMI + RES + BBR
Body weight initial (g)	237.89 ± 17.32	242.67 ± 30.75	248.33 ± 38.92	248.66 ± 11.34	218.16 ± 19.13	229.66 ± 28.01	217 ± 20.50
Body weight final (g)	263 ± 29.83	270.16 ± 34.77	264.5 ± 24.04	326.16 ± 18.37	270.66 ± 21.33	285 ± 28	286.83 ± 12.59
Body weight % change	10.34 ± 5.01	11.45 ± 5.98	7.63 ± 9.46	31.20 ± 5.76[a,b,c]	24.39 ± 8.89[a,c]	24.55 ± 8.05[a,c]	31.55 ± 9.01[a,b,c]
Absolute liver weight (g)	8.8 ± 1.2	8.76 ± 1.14	8.65 ± 0.76	12.06 ± 0.92	9.37 ± 0.81	9.94 ± 0.97	9.77 ± 0.65
Relative liver weight (g)	3.34 ± 0.22	3.25 ± 0.23	3.29 ± 0.42	3.69 ± 0.09	3.46 ± 0.17	3.51 ± 0.49	3.41 ± 0.25
Absolute right kidney weight (g)	0.93 ± 0.15	1.07 ± 0.18	1.02 ± 0.16	1.31 ± 0.1	1.08 ± 0.11	1.18 ± 0.2	1.2 ± 0.13
Relative right kidney weight (g)	0.35 ± 0.21	0.39 ± 0.05	0.39 ± 0.08	0.4 ± 0.01	0.4 ± 0.04	0.41 ± 0.04	0.42 ± 0.03
Absolute left kidney weight (g)	0.97 ± 0.14	1.04 ± 0.2	0.99 ± 0.11	1.26 ± 0.06	1.22 ± 0.33	1.13 ± 0.15	1.2 ± 0.12
Relative left kidney weight (g)	0.36 ± 0.3	0.38 ± 0.07	0.38 ± 0.06	0.38 ± 0.01	0.45 ± 0.11	0.39 ± 0.03	0.41 ± 0.04

Comparison of [a]Control group, [b]RES group, [c]BBR group, [d]IMI group, [e]IMI + RES group, [f]IMI + BBR group, Significance at $p < 0.05$

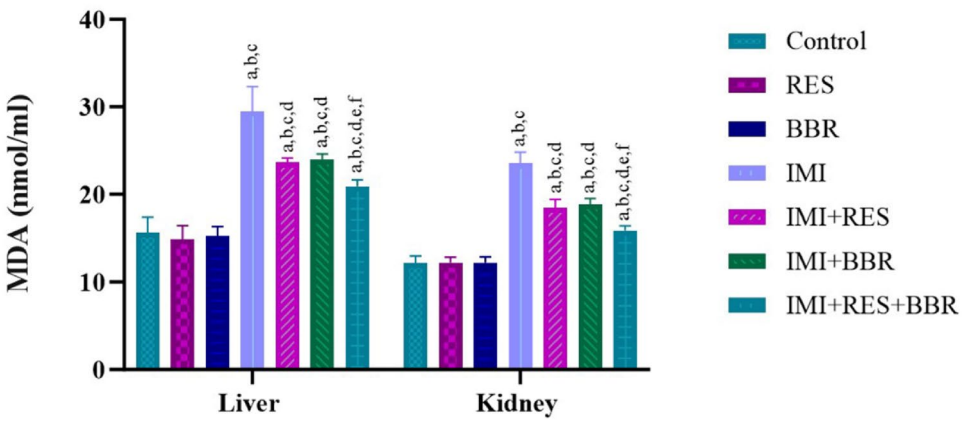

Fig. 1 Effects of imidacloprid on MDA levels in liver and kidney tissues of Wistar rats. Comparison of [a]Control group, [b]RES group, [c]BBR group, [d]IMI group, [e]IMI + RES group, [f]IMI + BBR group, Significance at $p < 0.05$

in antioxidant enzyme activities was detected ($p < 0.05$) (Fig. 2).

3.2.2 Total Oxidants and Antioxidants Status

IMI exposure markedly reduced total antioxidant status (TAS), and elevated total oxidant status (TOS) along with the oxidative stress index (OSI) in both hepatic and renal tissues relative to controls. However, co-administration of RES and/or BBR with IMI significantly attenuated these effects, demonstrating higher TAS values and lower TOS and OSI measurements compared to IMI ($p < 0.05$) (Fig. 3).

3.3 AChE Activities in Hepatic and Renal Tissues

IMI exposure caused a significant decrease in AChE enzyme activity in hepato-renal tissues of rats compared to the control group. However, IMI + RES, IMI + BBR, and IMI + RES + BBR treatments reversed the IMI-induced change in AChE enzyme activities and increased the enzyme activity in the tissues ($p < 0.05$) (Fig. 4).

3.4 Hematological Parameters

After the completion of the experimental period, when the control, RES and BBR groups were compared with the IMI groups, a decrease in RBC, hemoglobin, hematocrit, MCH, and MCV values and an increase in WBC and platelet values were observed ($p < 0.05$). No statistically significant difference was observed in MCHC values. When the IMI + RES, IMI + BBR and IMI + RES + BBR groups were compared with the IMI-treated groups, statistically significant changes were observed in hematocrit, WBC, MCH, MCV, and platelet values ($p < 0.05$), but no significance was observed in RBC, hemoglobin, and MHCH values (Table 3).

3.5 Hepatic and Kidney Function Markers

As shown in Table 4, the biochemical markers of liver damage, namely ALT, AST, ALP, and LDH activities, triglyceride, and total cholesterol levels, were significantly increased in the groups exposed to IMI compared to the control group, while total protein and albumin levels were significantly decreased. In the IMI + RES, IMI + BBR, and IMI + RES + BBR groups, the high ALT, AST, ALP, and LDH activities caused by IMI, as well as triglyceride and total cholesterol levels, decreased significantly, while

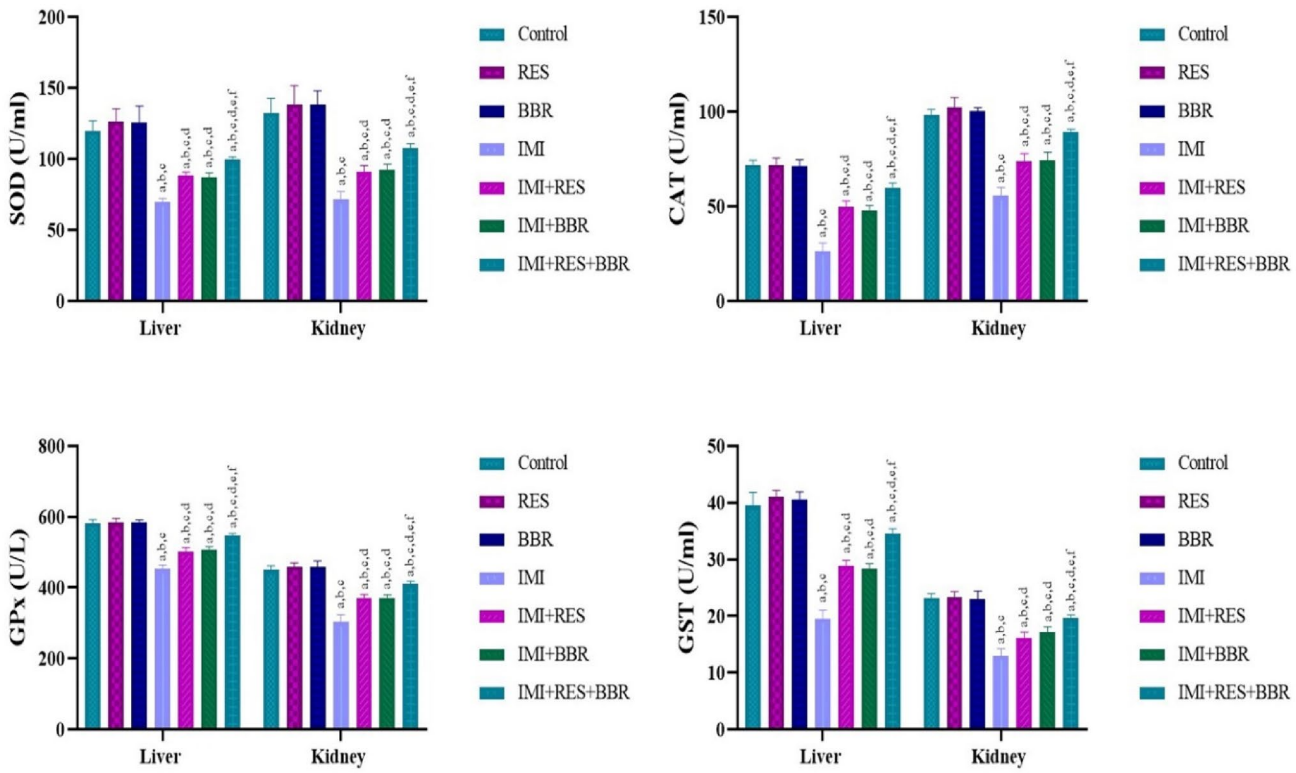

Fig. 2 Effects of imidacloprid on antioxidant enzyme activities (SOD, CAT, GPx and GST) in liver and kidney tissues of Wistar rats. Comparison of [a]Control group, [b]RES group, [c]BBR group, [d]IMI group, [e]IMI + RES group, [f]IMI + BBR group, Significance at $p < 0.05$

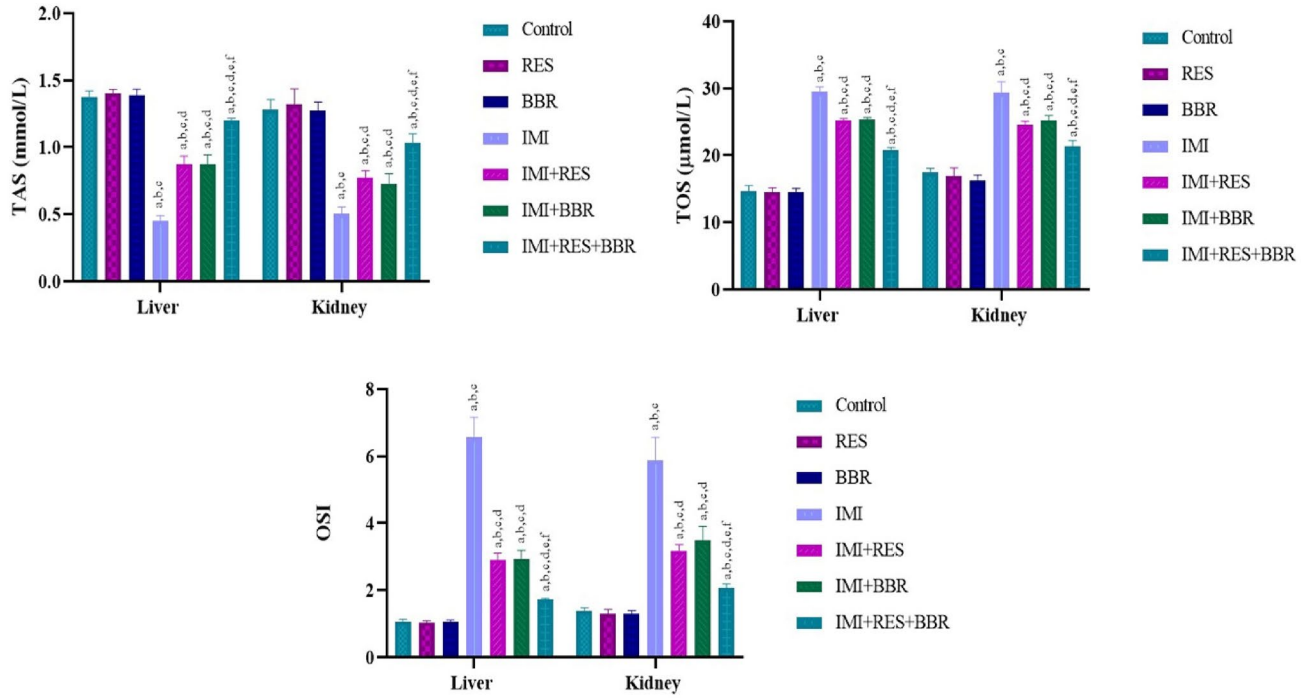

Fig. 3 Effects of imidacloprid on TAS, TOS levels and OSI index in liver and kidney tissues of Wistar rats. Comparison of [a]Control group, [b]RES group, [c]BBR group, [d]IMI group, [e]IMI + RES group, [f]IMI + BBR group, Significance at $p < 0.05$

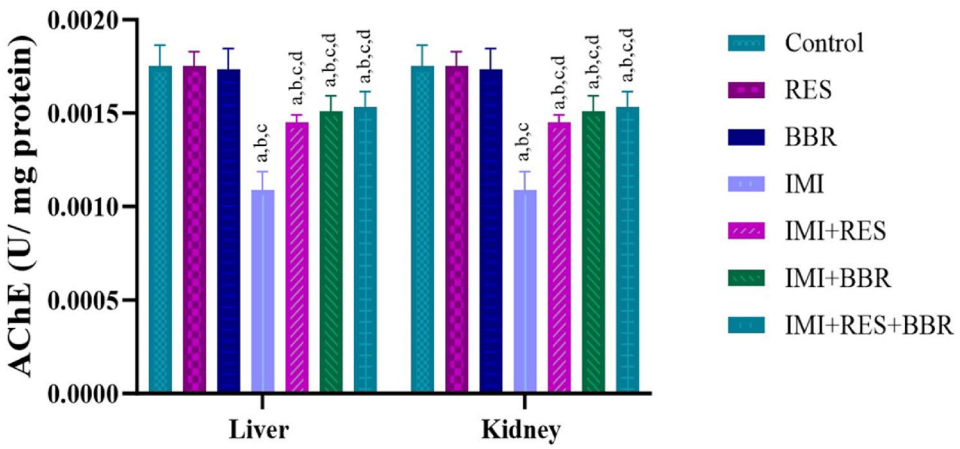

Fig. 4 Effects of imidacloprid on AChE activity in liver and kidney tissues of Wistar rats. Comparison of [a]Control group, [b]RES group, [c]BBR group, [d]IMI group, [e]IMI + RES group, [f]IMI + BBR group, Significance at $p < 0.05$

total protein and albumin levels increased significantly ($p < 0.05$) (Table 4).

In the IMI group, kidney function markers (serum urea, uric acid, creatinine, and BUN) were significantly increased compared to the control group. However, in the IMI + RES, IMI + BBR, and IMI + RES + BBR groups, there was a significant decrease in these parameters compared to the IMI group ($p < 0.05$) (Table 4).

3.6 8-OHdG Levels in Hepatic and Renal Tissues

The level of 8-OHdG, a biological marker of DNA damage caused by oxidative stress, was significantly elevated in the liver and kidney tissues of the group treated with IMI compared to the control group. However, a significant decrease was observed in the IMI + RES, IMI + BBR,

Table 3 Effects of imidocloprid on haematological parameters of Wistar rats

Parameters	Groups						
	Control	RES	BBR	IMI	IMI + RES	IMI + BBR	IMI + RES + BBR
RBC (M/mm^3)	9.49 ± 0.31	9.96 ± 1.09	9.89 ± 1.09	7.05 ± 0.64^{abc}	8.03 ± 0.97^{abc}	8.21 ± 0.76^{bc}	8.36 ± 0.28^{bc}
Hemoglobin (g/L)	170.83 ± 11.12	185.0 ± 11.88	175.50 ± 9.24	133.16 ± 18.96^{abc}	146.83 ± 19.91^{bc}	140.16 ± 17.40^{abc}	155.50 ± 14.92^{b}
Hematocrit (%)	49.31 ± 1.98	49.78 ± 1.68	50.55 ± 2.05	39.86 ± 2.57 ^{abc}	44.75 ± 1.25^{abcd}	44.40 ± 2.17^{abcd}	45.68 ± 1.31^{abcd}
WBC (K/mm^3)	7.44 ± 0.42	7.15 ± 0.59	7.25 ± 0.61	9.43 ± 0.48^{abc}	8.02 ± 0.54^{d}	7.84 ± 0.79^{d}	7.55 ± 0.52^{d}
MCH (Pg)	19.58 ± 0.35	19.53 ± 0.36	19.40 ± 0.28	17.83 ± 0.65^{abc}	19.51 ± 0.53^{d}	19.0 ± 0.50^{d}	18.93 ± 0.63^{d}
MCV (fL)	57.13 ± 2.15	55.20 ± 2.28	55.71 ± 1.01	52.01 ± 1.54^{ac}	55.88 ± 0.99^{d}	57.80 ± 2.37^{d}	56.78 ± 1.48^{d}
MCHC (g/L)	343.16 ± 6.36	344.33 ± 8.26	344.50 ± 8.11	332.0 ± 9.25	341.83 ± 4.53	337.0 ± 6.32	338.50 ± 10.01
Platelet (K/mm^3)	584.0 ± 32.25	590.16 ± 24.98	562.83 ± 17.22	772.0 ± 37.51^{abc}	658.50 ± 28.11^{abcd}	663.83 ± 22.19^{abcd}	609.83 ± 18.33^{def}

Comparison of [a]Control group, [b]RES group, [c]BBR group, [d]IMI group, [e]IMI + RES group, [f]IMI + BBR group, Significance at $p < 0.05$

and IMI + RES + BBR groups compared to the IMI group ($p < 0.05$) (Fig. 5).

3.7 IL-17 Levels in Hepatic and Renal Tissues

In the group treated with IMI, a significant increase in IL-17 levels was observed compared to the control group. In contrast, in the IMI + RES, IMI + BBR, and IMI + RES + BBR groups, a significant decrease in IL-17 levels occurred compared to the IMI group ($p < 0.05$) (Fig. 6).

3.8 Serum Insulin, Glucagon and Glucose Levels

A statistically significant decrease in serum insulin levels was observed in the IMI group compared to the control group, while a statistically significant increase in glucagon and glucose levels was observed in the IMI group compared to the control group. In the IMI + RES, IMI + BBR, and IMI + RES + BBR groups, insulin levels increased and glucagon and glucose levels decreased compared to the IMI group ($p < 0.05$) (Fig. 7).

3.9 Histopathological Findings

Light microscope images of histological examinations of rat hepato-renal tissues are shown in Figs. 8 and 9, respectively. Liver tissues of rats in the berberine and resveratrol groups showed normal hepatic structure hepatocytes, sinusoidal areas, and central vens (Fig. 8A–C).

Degeneration in hepatocytes, dilatation in sinusoids, and inflammatory cell infiltration were detected in the hepatic tissue of imidacloprid -treated rats (Fig. 8D). Some pathological changes, such as degeneration in hepatocytes, dilatation in sinusoids, inflammatory cell infiltration, were observed in the hepatic tissue of both berberine and resveratrol plus imidacloprid-treated rats, as well as berberine plus resveratrol plus imidacloprid-treated rats (Fig. 8E–G). In this study, we showed that when supplementation of antioxidant compounds with imidacloprid, milder pathological changes in hepatic tissues.

Histological examination of kidney tissues from the control, berberine-treated, and resveratrol-treated groups revealed normal morphology of the Bowman's capsule, glomeruli, and renal tubules (Fig. 9A–C). Tubular degeneration and congestion were detected in the renal tissue of imidacloprid-treated rats (Fig. 9D). Tubular degeneration and congestion were observed in the renal tissue of rats treated with resveratrol plus imidacloprid-treated rats. Similarly, renal tissues from rats receiving berberine plus imidacloprid-treated rats exhibited tubular degeneration and congestion (Fig. 9E–F). Tubular degeneration and congestion were observed in the renal tissue of berberine plus resveratrol plus imidacloprid-treated rats (Fig. 9G).

3.10 Immunohistochemical Findings

Alterations in the expression of Caspase-3 and TNF-α within hepatic and renal tissues were assessed through immunohistochemical analysis. Caspase-3 and TNF-α expression was not observed in hepatic tissue of control, RES and BBR groups (Fig. 10–11). In the IMI + RES, IMI + BBR and IMI + RES + BBR groups, there was a decrease in the expression of Caspase-3 and TNF-α in hepatocytes compared to the IMI group (Figs. 10–11). Figures 10–11 show

Table 4 Effects of IMI on the hepatic and renal biochemical parameters of Wistar rat

Parameters	Groups						
	Control	RES	BBR	IMI	IMI + RES	IMI + BBR	IMI + RES + BBR
Liver							
Total Protein (g/dI)	8.04 ± 0.44	8.14 ± 0.36	8.09 ± 0.17	5.74 ± 0.36^{abc}	7.28 ± 0.68^{abcd}	7.21 ± 0.31^{abcd}	7.08 ± 0.33^{abcd}
Albumin (g/dI)	3.49 ± 0.05	3.50 ± 0.09	3.52 ± 0.04	3.02 ± 0.05^{abc}	3.18 ± 0.09^{abcd}	3.19 ± 0.1^{abcd}	3.33 ± 0.04^{abcdef}
AST (U/L)	96.83 ± 13.95	98.21 ± 14.36	98.22 ± 11.87	173.10 ± 13.75^{abc}	126.61 ± 9.13^{abcd}	125.91 ± 10.28^{abcd}	148.78 ± 7.78^{abcdef}
ALT (U/L)	6.95 ± 1.12	7.01 ± 0.68	6.88 ± 1.43	18.56 ± 1.56^{abc}	10.25 ± 1.37^{abcd}	9.95 ± 1.28^{abcd}	13.11 ± 2.33^{abcdef}
ALP (U/L)	100.16 ± 10.51	105.5 ± 6.47	111.16 ± 5.34	212.0 ± 15.67^{abc}	148.33 ± 23.08^{abcd}	135.0 ± 8.39^{abcd}	178.0 ± 8.71^{abcdef}
LDH (U/L)	687.0 ± 72.90	677.33 ± 43.19	766.33 ± 70.09	1467.16 ± 130.59^{abc}	1100.5 ± 88.5^{abcd}	1108.83 ± 107.76^{abcd}	934.16 ± 82.52^{abcdef}
Triglyceride (mg/dI)	28.16 ± 2.78	26.5 ± 1.87	26.83 ± 4.07	46.5 ± 2.5^{abc}	40.33 ± 1.96^{abcd}	37.66 ± 0.81^{abcd}	33.0 ± 1.54^{abcdef}
Total Cholesterol (mg/dI)	23.0 ± 1.54	21.33 ± 1.21	21.16 ± 1.16	48.33 ± 2.33^{abc}	36.66 ± 1.86^{abcd}	37.16 ± 3.65^{abcd}	30.66 ± 2.25^{abcdef}
Kidney							
BUN (mg/dl)	8.99 ± 1.06	8.84 ± 0.93	8.29 ± 0.84	15.80 ± 1.14^{abc}	12.80 ± 0.63^{abcd}	12.87 ± 1.21^{abcd}	10.91 ± 0.46^{abcdef}
Creatinine (mg/dl)	0.53 ± 0.01	0.56 ± 0.01	0.55 ± 0.01	0.77 ± 0.22^{abc}	0.69 ± 0.22^{abcd}	0.67 ± 0.09^{abcd}	0.64 ± 0.01^{abcdef}
Urea (mg/dl)	22.55 ± 2.20	21.25 ± 0.74	20.95 ± 1.79	45.13 ± 3.40^{abc}	34.48 ± 2.34^{abcd}	35.43 ± 2.76^{abcd}	29.93 ± 3.25^{abcdef}
Uric acid (mg/dl)	1.22 ± 0.08	1.24 ± 0.07	1.16 ± 0.08	1.88 ± 0.10^{abc}	1.56 ± 0.04^{abcd}	1.55 ± 0.07^{abcd}	1.41 ± 0.03^{abcdef}

Comparison of [a]Control group, [b]RES group, [c]BBR group, [d]IMI group, [e]IMI + RES group, [f]IMI + BBR group, Significance at $p < 0.05$

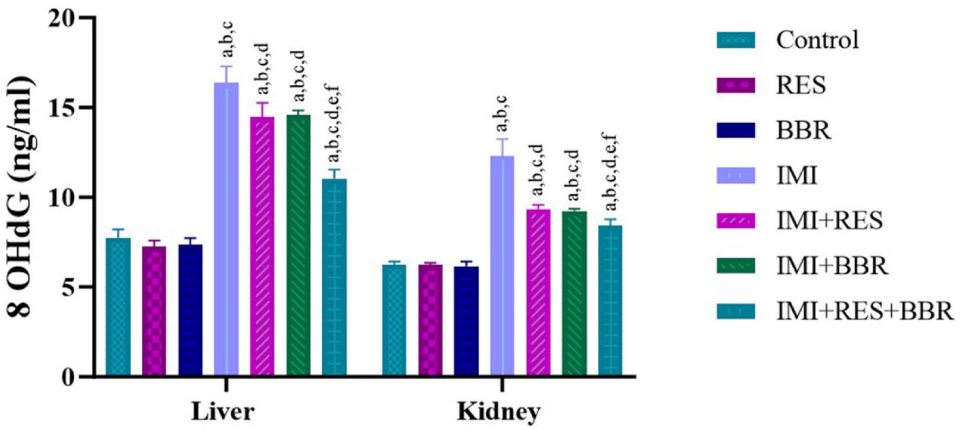

Fig. 5 Effects of imidacloprid on 8-OHdG levels in liver and kidney tissues of Wistar rats. Comparison of [a]Control group, [b]RES group, [c]BBR group, [d]IMI group, [e]IMI + RES group, [f]IMI + BBR group, Significance at $p < 0.05$

the immunoreactivity of the examined parameters in liver tissue between the groups. In the kidney tissue, no significant expression of Cas-3 or TNF-α was detected in the control, RES or BBR groups, while an increase in the expression of both markers was observed in the IMI group (Figs. 12, 13). A significant decrease in the expression of Caspase-3 and

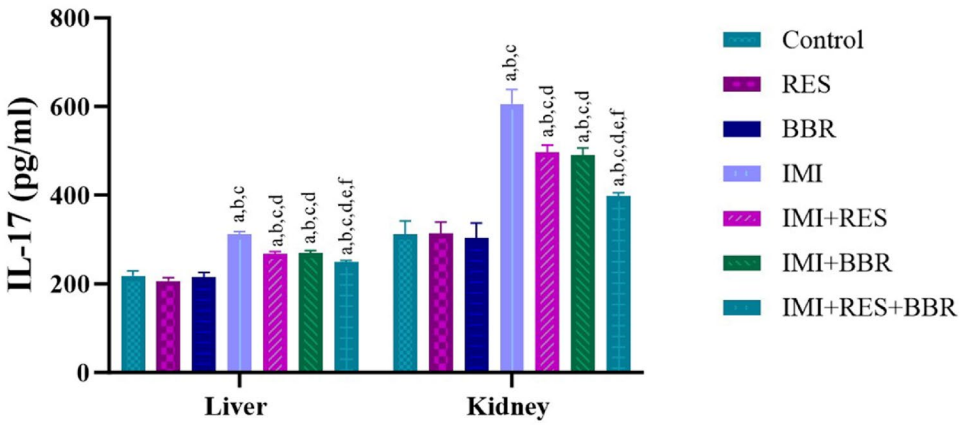

Fig. 6 Effects of IMI on IL-17 levels in liver and kidney tissues of Wistar rats. Comparison of [a]Control group, [b]RES group, [c]BBR group, [d]IMI group, [e]IMI + RES group, [f]IMI + BBR group, Significance at $p < 0.05$

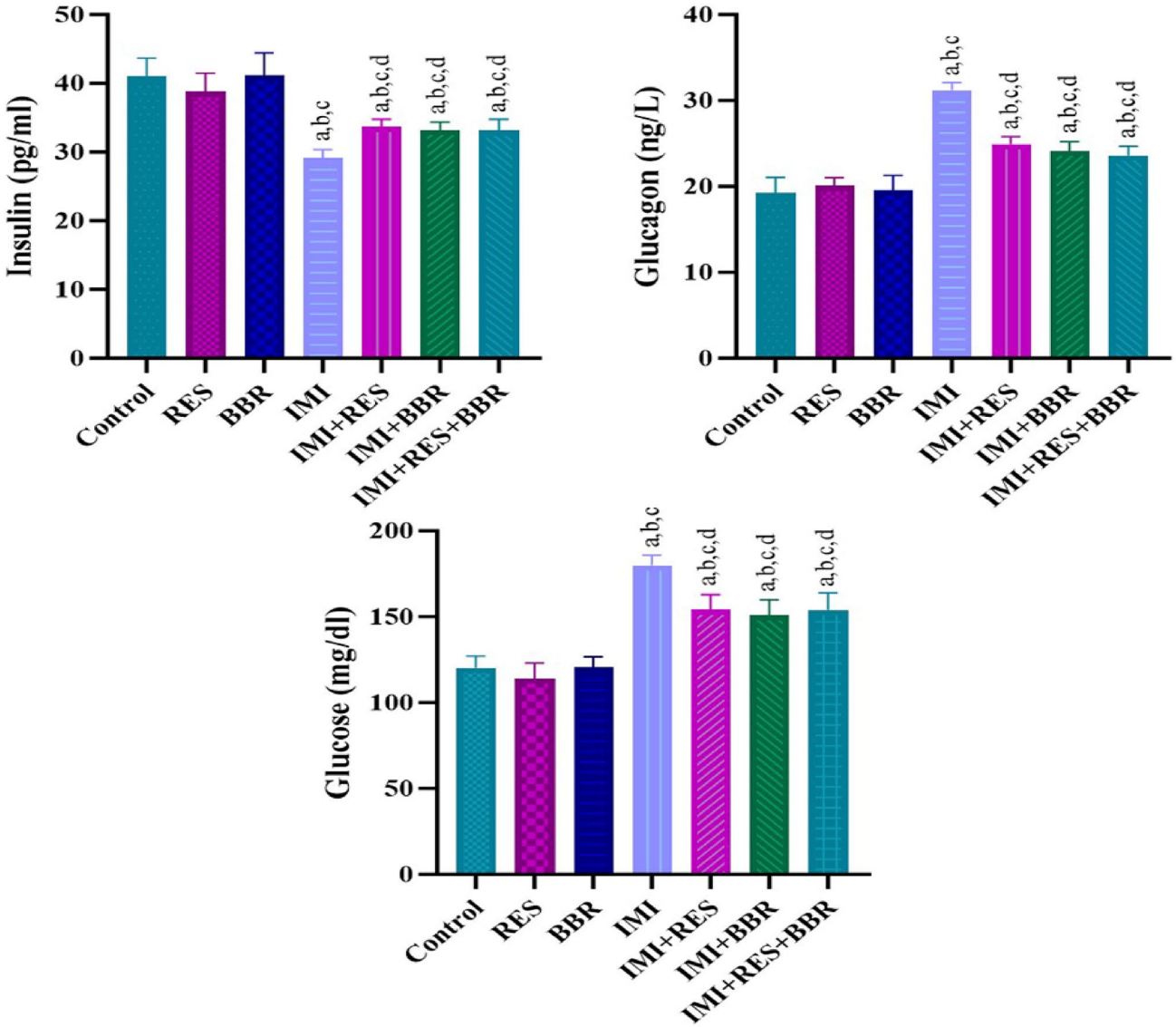

Fig. 7 Effects of imidacloprid on insulin, glucagon and glucose levels of Wistar rats. Comparison of [a]Control group, [b]RES group, [c]BBR group, [d]IMI group, [e]IMI + RES group, [f]IMI + BBR group, Significance at $p < 0.05$

TNF-α in the kidney tissues was observed in the IMI + RES, IMI + BBR and IMI + RES + BBR groups compared to the IMI group (Figs. 12, 13). The immunoreactivity graph of the kidney tissue is given in Figs. 12, 13.

4 Discussion

Over the past few decades, a large body of evidence has emerged highlighting the adverse effects of environmental toxins on organ systems [36]. Although pesticides contribute to human and animal life with their effects in agricultural areas, they cause many toxic effects on living organisms both by mixing into the environment and causing negative environmental effects [14]. Neonicotinoids are a commonly used class of systemic insecticides [37]. IMI, which is a neonicotinoid pesticide, has low toxicity to mammals, but there is increasing evidence that IMI can cause problems with the heart, kidneys and other organs, as well as gastrointestinal irritation and neural symptoms or even death [38]. Tonietto et al. [39] reported in their study that the administration of IMI at a subchronic level resulted in toxic effects, which manifested as behavioural, haematological and biochemical changes. These findings suggest that the substance may cause damage to mammals, including humans, given its extensive use in agriculture.

Flavonoids are widely used today for their antioxidant properties and have been the subject of many studies investigating their potential protective effects against various diseases [12]. RES has been shown to provide protection against various forms of oxidative stress and inflammation. It has also exhibited numerous health benefits, including influencing cytokine release levels, reducing oxidative stress and improving kidney function [17]. It has been shown through studies that BBR has the potential to reduce inflammation and oxidative damage in different tissues, such as the hepatic tissues, by adjusting signalling pathways like MAPKs (Mitogen-activated protein kinases), AMPK (AMP-activated protein kinase), NF-κB (Nuclear factor kappa-light-chain-enhancer of activated B cells) and Nrf2 (Nuclear factor erythroid 2-related factor 2). The fact that berberine is hydrophobic affects how well it works as a medicine, but advances in nanotechnology, like nanoemulsion formulations, have been used to make it easier for the body to absorb and improve its bioavailability [40]. In addition to this, resveratrol can reduce the toxic byproducts of oxidation by delaying the oxidation of lipids [41].

In toxicological studies, monitoring changes in the body weight and organ weight of laboratory animals is an important marker in determining the effect of the toxic substance. In this study, no significant changes were observed in organ weights, while body weight gain was significantly reduced in the IMI group compared to the control group. These changes in weight gain may be due to cellular degeneration and may disrupt bodily homeostasis [42].

Serum liver function parameters were aspartate aminotransferase (AST), alanine aminotransferase (ALT), lactat dehydrogenase (LDH) and alkaline phosphatase (ALP), kidney function [blood urea, creatinine, and urea], values were reported to be the most important biochemical markers in studies on pesticide toxicity [43]. In previous studies, it was reported that IMI increased cytosolic enzymes such as ALT, AST and LDH [39, 44]. The results of this study indicate that subacute exposure to imidacloprid causes histopathological changes in the liver, which are most likely related to damage to the membrane permeability of hepatocytes, allowing the enzyme and insecticide to leak out and damage the normal cellular structure of the hepatocellular membrane [11]. Monitoring changes in the levels of total protein, albumin, triglycerides, and total cholesterol in the blood is critical for the metabolism of proteins and lipids. Previous studies have reported that IMI exposure decreased total protein levels and increased cholesterol and triglyceride levels [44, 45]. Therefore, the decrease in total protein and albumin and the increase in triglyceride and total cholesterol can be attributed to the effect of IMI on protein and lipid metabolism. Pesticide exposure leads to hepatic injury and leaks of cytosolic enzymes from hepatic cells and other parts of the body into the blood [43]. Renal function markers such as urea, creatinine and uric acid are used to determine the kidney function of animals, with elevated levels indicating possible dysfunction. Plasma creatinine levels have been shown to be a good indicator of glomerular filtration rate [46]. When the kidneys are damaged by pesticide toxicity, the creatinine level in the blood will increase due to damaged functioning nephrons and impaired kidney function [11, 43]. It has been reported in previous reports that IMI administration increases renal creatinine, urea and uric acid values [44, 47]. When BBR/RES was taken together, the/their treatment was observed to be effective in reducing and improving hepatorenal damage.

Hematologic parameters are as important as biochemical diagnosis in toxic substance testing, especially pesticide studies [11]. In this study, while a decrease in RBC, hemoglobin, hematocrit, MCV, and MCH values was observed in the rats in the IMI-treated groups, an increase in WBC and platelet values was detected. This situation may be the result of the suppression of the activities of hematopoietic tissues as a result of the accumulation of toxic metabolites in the liver and kidney, as reported in other pesticide studies [39]. It has been established that IMI induces structural and functional changes in haemoglobin, thereby altering its physiological state [39]. However, an increase in WBC levels may be indicative of inflammation.

It has been suggested by earlier studies that oxidative stress is a major causative factor in cellular toxicity [11, 38,

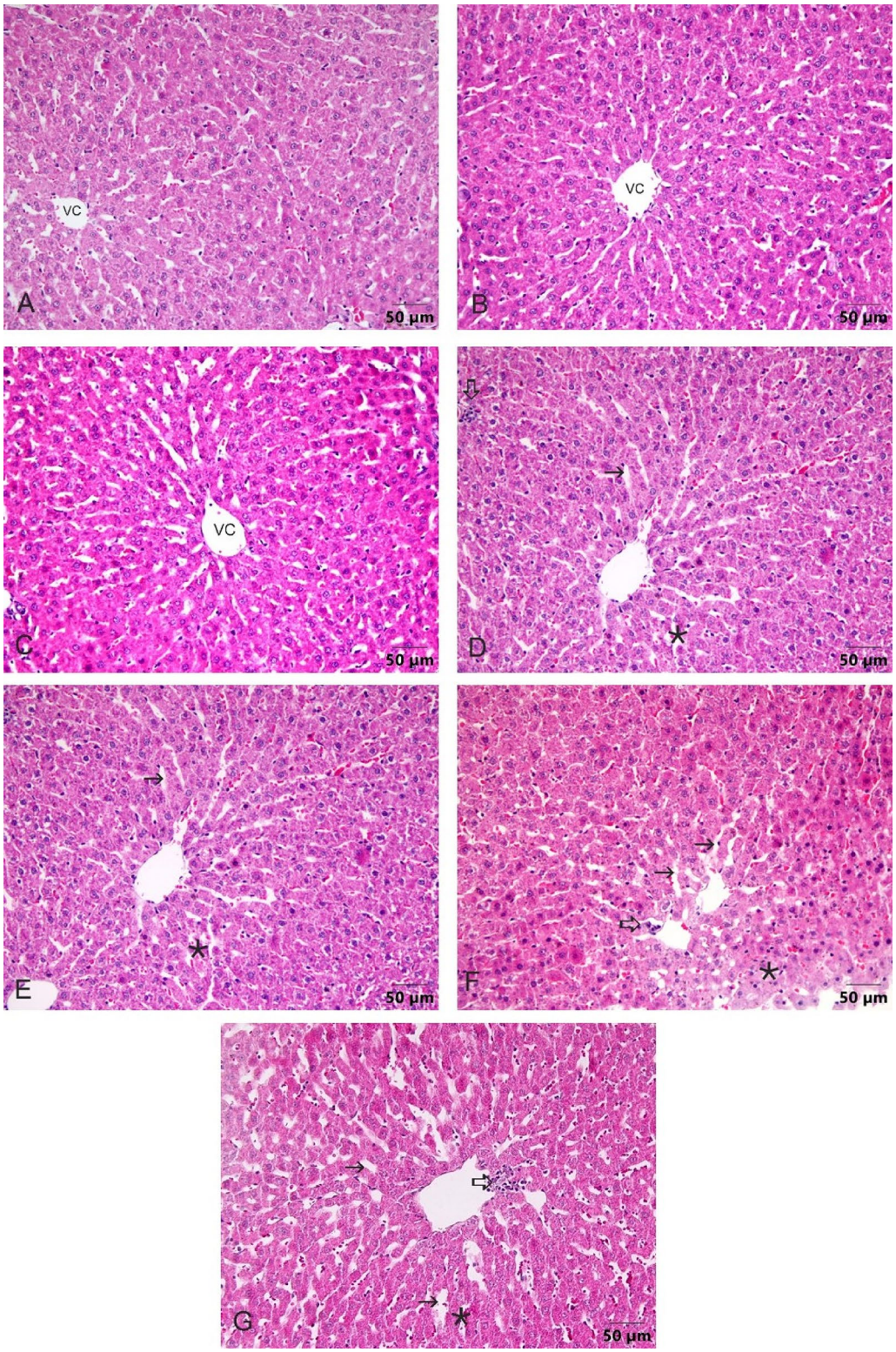

Fig. 8 Microscopic representation of the study groups using Hematoxylin & Eosin method in hepatic tissues. Hepatocytes and central vein (CV) in hepatic tissues of control (**A**), berberine (**B**) and resveratrol (**C**) groups appear to have normal histological structure. Degeneration in hepatocytes (∗), dilatation in sinusoids (→), and inflammatory cell infiltration (⇨) were observed in the hepatic tissue of imidacloprid-treated rats (**D**). Degeneration in hepatocytes (∗), dilatation in sinusoids (→), were observed in the hepatic tissue of berberine plus imidacloprid-treated rats (**E**). Degeneration in hepatocytes (∗), dilatation in sinusoids (→) were observed in the hepatic tissue of resveratrol plus imidacloprid-treated rats (**F**). Degeneration in hepatocytes (∗), dilatation in sinusoids (→), and inflammatory cell infiltration (⇨) were observed in the hepatic tissue of berberine plus resveratrol plus imidacloprid-treated rats (**G**). Scale bar = 50 µm

48]. Oxidative stress measurements have an important place in toxicological studies with pesticides [43, 49]. Malondialdehyde levels are widely used as a reliable biomarker for assessing cellular oxidative stress and antioxidant capacity [50]. High MDA in the liver suggests production of oxidative metabolites or free radicals during hepatic enzyme metabolism, and this could be due to the increasing free radical chain reaction; elevated level of MDA in tissues confirms the results of other studies [36, 51]. ROS formation induces DNA damage, protein degradation, LPO, and finally culminates in damage to various vital tissues. These increased free radicals and reduced antioxidant defences can lead to cell disruption, oxidative stress [38, 52]. Previous studies with IMI show that IMI increases MDA levels and decreases antioxidant activities [9, 45]. In this study, increased LPO levels and decreased CAT, SOD, GPx and GST enzyme activities were observed in the liver and kidneys of rats exposed to IMI. The antioxidative defenses of various tissues, such as liver, kidney, and testes, can be effectively improved by natural products to ameliorate the oxidative damage induced by IMI exposure [47]. TAS, TOS levels and OSI values, along with antioxidant levels in the cell, are very important in determining the oxidant/antioxidant balance. Among these, the increase in OSI value is an important marker of oxidative stress damage [11, 53].

It is very important to demonstrate tissue and cellular damage to emphasize the toxic effects of pesticides [54]. It may result in severe damage to cellular integrity, resulting in the exaggerated histopathology noted in the microscopy findings. Histopathology revealed that IMI exposure caused severe dilatation in sinusoids, inflammatory cell infiltration of liver tissue and also congestion and degeneration of kidney tissue. These results are similar to the previous one [47]. Significant increases in ALT, AST, LDH, BUN, uric acid and creatinine with IMI administration paralleled these results. These results suggest that imidacloprid may damage liver and kidney cells and tissues through oxidative stress. For example, Chakroun et al. [55] found that administering IMI orally caused liver damage in rats, as demonstrated by significant rises in plasma levels of AST, ALP, ALT and LDH. The observed elevation in these enzymes could be a result of liver dysfunction caused by the harmful effect of IMI on liver cell membranes. The changes seen are consistent with liver cell damage in rats treated with IMI.

Acetylcholinesterase (AChE) is an enzyme that plays a key role in the human nervous system. It is responsible for breaking down the neurotransmitter acetylcholine. Pesticides can interfere with the activity of AChE, resulting in severe neurological effects [56]. In the present study, IMI was observed to significantly reduce AChE activity by disrupting neurotransmission activity in liver and kidney tissue. BBR and RES administration were determined to significantly attenuate the IMI-induced decrease in AChE activity and exhibit an antioxidant effect.

DNA is a target for the excess production of reactive oxygen species, which are produced when oxygen is in excess. Guanine is the most likely to react with free radicals [57]. 8-OHdG is an important biomarker of oxidative DNA injury and also an important marker of oxidative modification of DNA by pesticides. Studies have shown that 8-OHdG is an effective biomarker for assessing the risk of a variety of cancers, degenerative diseases, and toxicant damage. The excessive presence of 8-OHdG under physiological conditions is regulated by a variety of complex mechanisms, one of which is the elimination of oxidised nucleotides [58]. In a previous study, the use of pesticides increased the level of 8-OHdG in rat tissues, while the use of the antioxidant compound decreased the level of 8-OHdG [59]. In the current study, similarly, IMI treatment increased 8-OHdG levels in rats. RES and BBR treatment decreased 8-OHdG levels.

The pancreas is both an endocrine and exocrine gland and is a very important organ that regulates blood glucose levels by secreting glucagon and insulin into the circulation [60]. However, previous studies have reported that chemicals cause cytotoxicity in the pancreas and lead to functional losses [61, 62]. Additionally, pesticides have been reported to cause abnormalities in glucose metabolism in the liver, increasing glycogenesis [63]. In a study by Khalil et al. [64], the IMI dose administered to rats increased serum glucose levels while decreasing insulin levels. In this study, insulin levels in the serum of rats administered IMI decreased, while glucose and glucagon levels increased. This can be attributed to the damage caused by IMI to pancreatic and liver tissue. In the study, RES and BBR supplementation administered together with IMI reduced glucose and glucagon levels while improving insulin levels.

The role of cytokines was examined, which are low-molecular-weight proteins that control functional aspects of cells, such as proliferation, cell migration, and immune cell activation, such as TNF-α and IL-17. Similarly, previous studies in rat models have reported that pesticide and other xenobiotic exposure triggers inflammation by increasing the release of pro-inflammatory cytokines in several tissues [65–67]. TNF-α is a major proinflammatory cytokine that has been the subject of many studies. It has been reported to play a role in: a cytokine that contributes to the formation and development of tissue damage [68]. IL-17 plays an active role in intracellular and extracellular protection against pathogens [69]. In the current study, IMI exposure increased TNF-α expression and IL-17 levels in liver and kidney tissues. In this study, inflammatory cytokines may have been activated due to oxidative stress in the cells, such as TNF- α and IL-17. RES and BBR significantly reduced the levels of TNF- α and IL-17, indicating that their hepatoprotective and nephroprotective effects may involve the

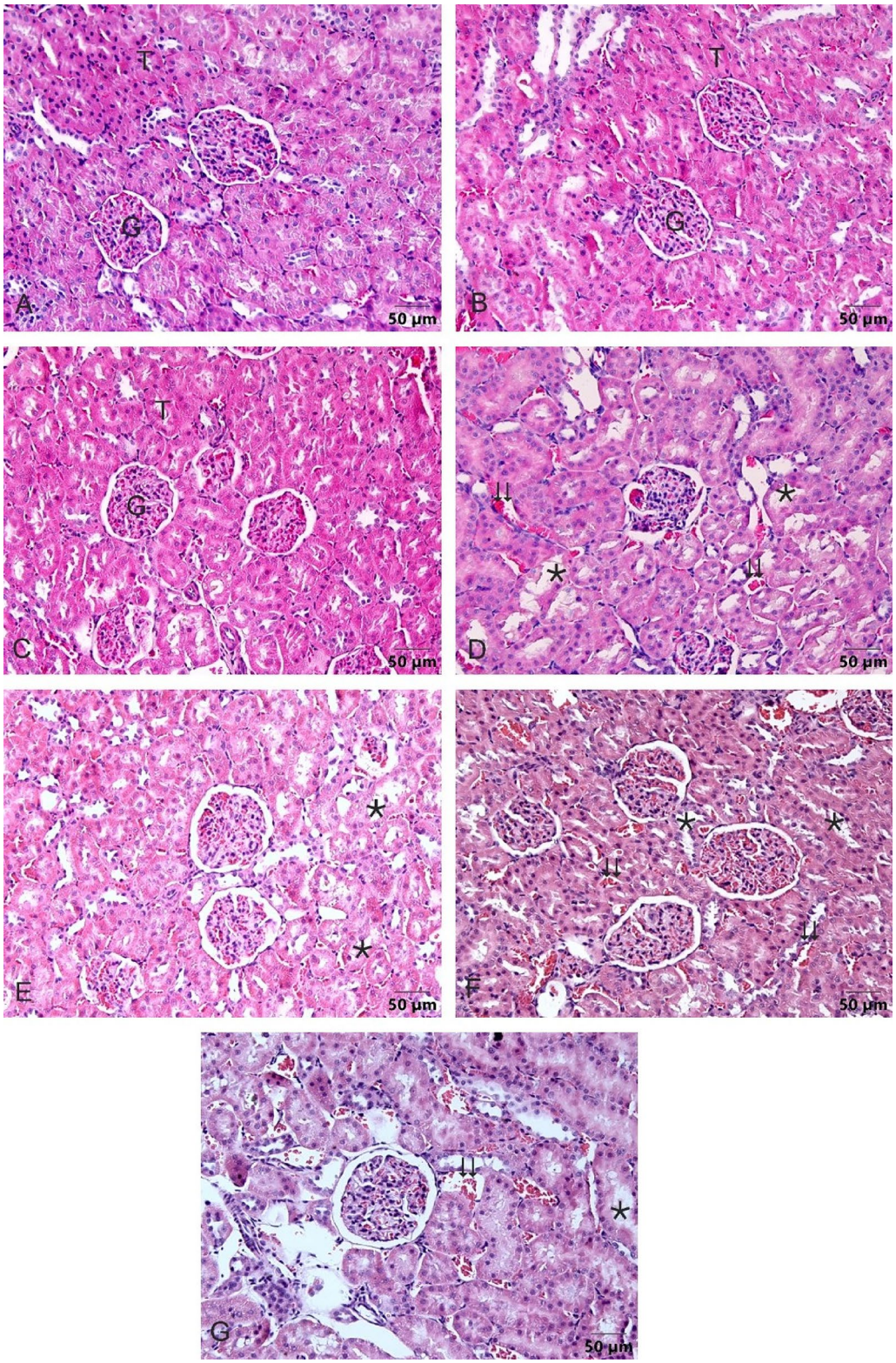

Fig. 9 Microscopic representation of the study groups using Hematoxylin & Eosin method in renal tissues. Tubules and glomerulus in renal tissues of control (**A**), berberine (**B**) and resveratrol (**C**) groups appear to have normal histological structure. Tubular degeneration (∗), congestion (⇊) were observed in the renal tissue of imidacloprid-treated rats (**D**). Tubular degeneration (∗) were observed in the renal tissue of berberine plus imidacloprid-treated rats (**E**). Tubular degeneration (∗), congestion (⇊) were observed in the renal tissue of resveratrol plus imidacloprid-treated rats (**F**). Tubular degeneration (∗), congestion (⇊) were observed in the renal tissue of berberine plus resveratrol plus imidacloprid-treated rats (**G**). Scale bar = 50 µm

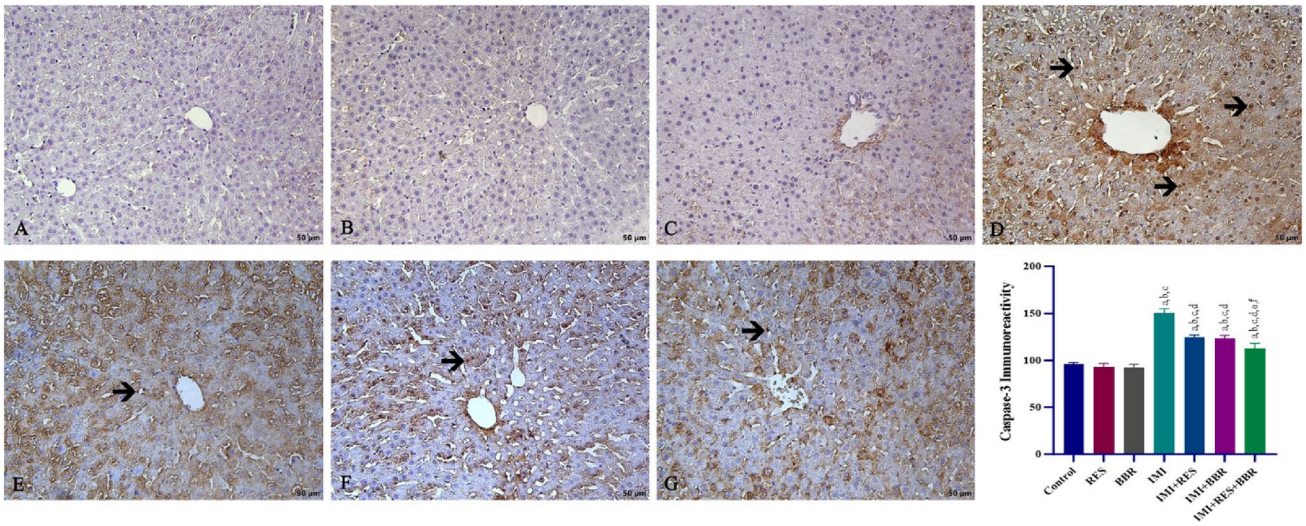

Fig. 10 Microscopic representation of the study groups by immunohistochemistry method of the caspase-3 in liver tissue. Comparison of [a]Control group, [b]RES group, [c]BBR group, [d]IMI group, [e]IMI + RES group, [f]IMI + BBR group, Significance at $p < 0.05$. Scale bar = 50 µm

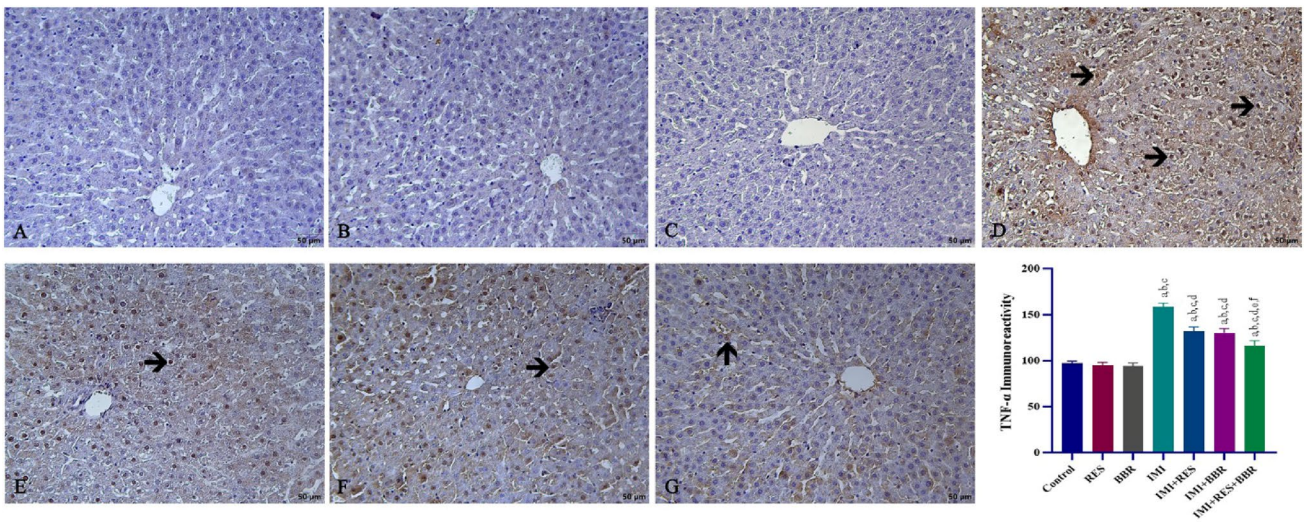

Fig. 11 Microscopic representation of the study groups by immunohistochemistry method of the TNF-α in liver tissue. Comparison of [a]Control group, [b]RES group, [c]BBR group, [d]IMI group, [e]IMI + RES group, [f]IMI + BBR group, Significance at $p < 0.05$. Scale bar = 50 µm

modulation of inflammatory pathways. These findings are parallel with previous reports on the anti-inflammatory effects of several flavonoids in tissue injury models [69].

Caspase-3 is a critical protease that plays a key role in the final stages of apoptosis. An increase in the number of cells that are immunopositive for caspase-3 is regarded as an indicator of apoptosis [70]. Caspase-3 was the point at which both intrinsic and extrinsic pathways came together in cells undergoing apoptosis-induced oxidative stress [70]. Our immunohistochemical study results show that IMI induces apoptosis with an increase in caspase-3 immunopositive cells in the liver and kidney tissue.

5 Conclusion

In the current study, the toxicological effects of neonicotinoids were evaluated comprehensively and revealed by many parameters, especially biochemical and histopathological evaluations. This imbalance may lead to cellular dysfunctions such as apoptosis, inflammation and mitochondrial damage. Taken together, BBR and RES have a protective effect against IMI-induced hepatorenal intoxication via their antioxidant, anti-inflammatory, and antiapoptotic effects by regulating apoptosis signaling pathways.

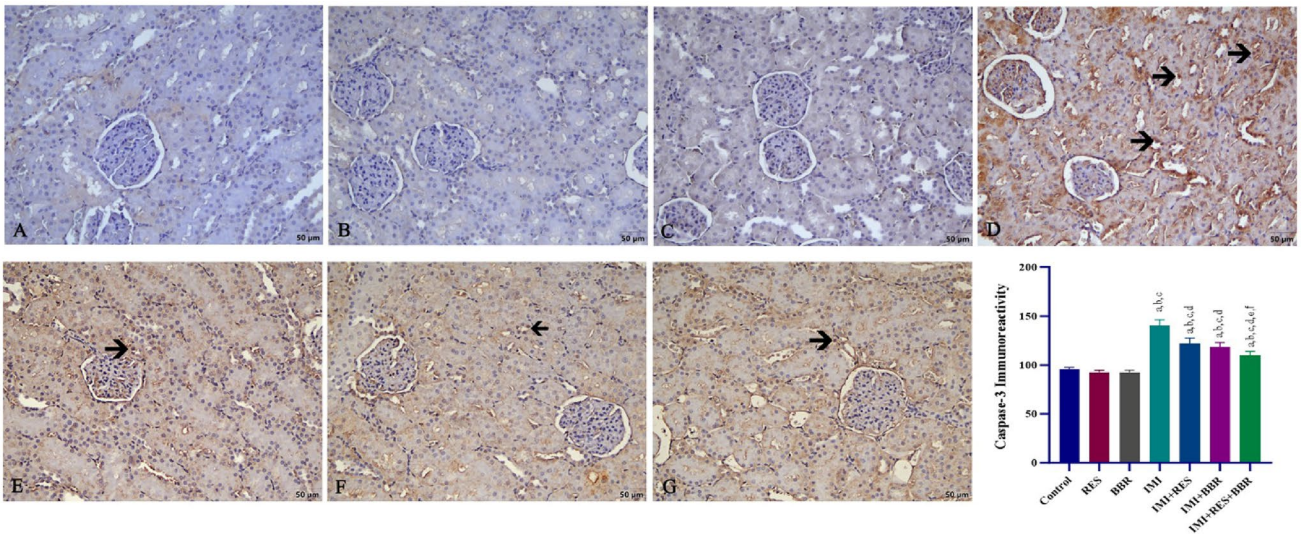

Fig. 12 Microscopic representation of the study groups by immunohistochemistry method of the caspase-3 in kidney tissue. Comparison of [a]Control group, [b]RES group, [c]BBR group, [d]IMI group, [e]IMI + RES group, [f]IMI + BBR group, Significance at $p < 0.05$. Scale bar = 50 µm

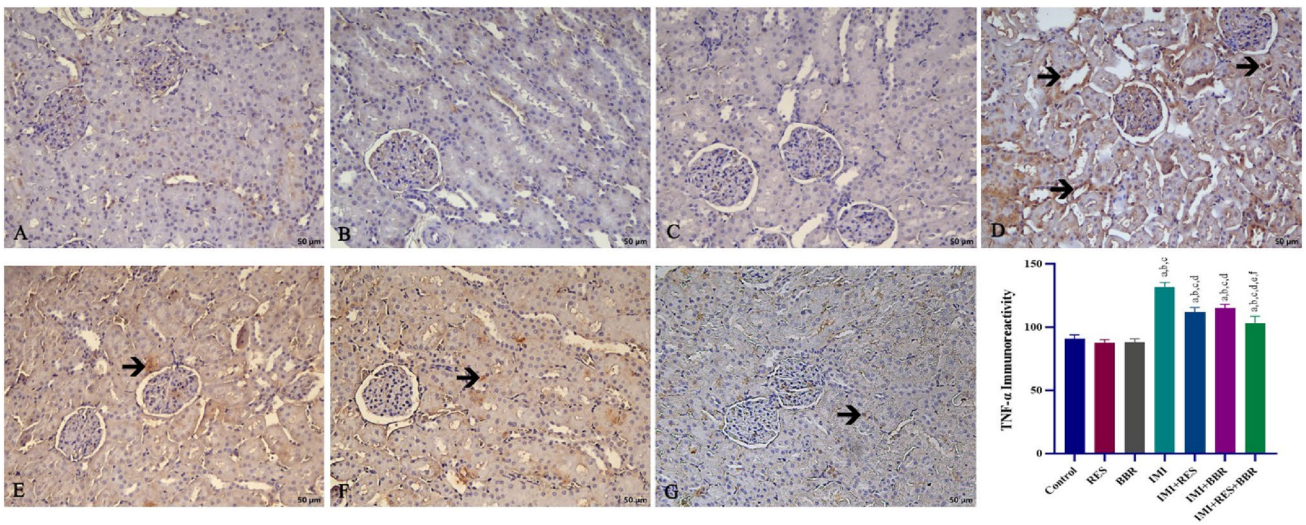

Fig. 13 Microscopic representation of the study groups by immunohistochemistry method of the TNF-α in kidney tissue. Comparison of [a]Control group, [b]RES group, [c]BBR group, [d]IMI group, [e]IMI + RES group, [f]IMI + BBR group, Significance at $p < 0.05$. Scale bar = 50 µm

5.1 Limitations

One limitation of the study is the absence of a water-vehicle control group. This decision was made in accordance with the 3R principles to reduce the number of animals used, as the inclusion of an additional control group was not expected to significantly affect the interpretation of the results.

Acknowledgements The authors would like to thank Gazi University for its financial support.

Author Contributions Hatice Karaboduk: Writing—original draft, Methodology, Formal analysis. Çağlar Adıgüzel: Writing—review & editing, Writing—original draft, Methodology, Data curation. Fatma G. Apaydin: Writing—original draft, Methodology. Yusuf Kalender: Supervision, Conceptualization.

Funding Open access funding provided by the Scientific and Technological Research Council of Türkiye (TÜBİTAK). The Gazi University Scientific Research Projects Coordination Unit (FGA-2023–8694).

Data Availability Data will be made available on request.

Declarations

Conflict of interest The authors declare that they have no known competing financial interests or personal relationships that could have appeared to influence the work reported in this paper.

Open Access This article is licensed under a Creative Commons Attribution 4.0 International License, which permits use, sharing, adaptation, distribution and reproduction in any medium or format, as long as you give appropriate credit to the original author(s) and the source, provide a link to the Creative Commons licence, and indicate if changes were made. The images or other third party material in this article are included in the article's Creative Commons licence, unless indicated otherwise in a credit line to the material. If material is not included in the article's Creative Commons licence and your intended use is not permitted by statutory regulation or exceeds the permitted use, you will need to obtain permission directly from the copyright holder. To view a copy of this licence, visit http://creativecommons.org/licenses/by/4.0/.

References

1. Apaydin FG, Kalender S, Kalender Y. Subacute exposure to dimethoate induces hepatotoxic and nephrotoxic effects on male rats: ameliorative effects of ferulic acid. Indian J Exp Biol. 2023;61:51–8.
2. Annabi A, Dhouib IB, Lamine AJ, El Golli N, Gharbi N, El Fazâa S, et al. Recovery by N-acetylcysteine from subchronic exposure to Imidacloprid-induced hypothalamic– pituitary–adrenal (HPA) axis tissues injury in male rats. Toxicol Mech Methods. 2015;25(7):524–31.
3. Shadnia S, Moghaddam HH. Case report, fatal intoxication with imidaclopride. Am J Emerg Med. 2008;26:1–4.
4. Ali HM, Abdel-Aty B, El-Sayed W, Mariy FM, Hegazy GM, Mohamed RA, Zoghly HM. Integrated biomarker response in common carp fingerlings exposed to neonicotinoid insecticide imidacloprid. Ecotoxicology. 2025; 1–21.
5. Abdelhafez HEH, Hammam FM, EL-Dahshan AA, Abo Dalam H, Guo J. Imidacloprid induces neurotoxicity in albino male rats by inhibiting acetylcholinesterase activity, altering antioxidant status, and primary DNA damage. J Toxicol. 2023;2023(1):4267469.
6. Lovakovi´c BT, Kašuba V, Sekovani´c A, Orct T, -Jan˘cec A, Pizent A. Effects of sub-chronic exposure to imidacloprid on reproductive organs of adult male rats: antioxidant state, DNA damage, and levels of essential elements. Antioxidants. 2021;10:1965.
7. Zouaoui S, Rouabhi R. Lysosomal disruption, mitochondrial impairment, histopathological and oxidative stress in rat's nervous system after exposure to a neonicotinoid (imidacloprid). Environ Sci Pollut Res. 2024;31:59472–89.
8. Mustafa KA, Alzubaidy MH, Al-Baggou BK. Adverse developmental and behavioral effects of imidacloprid in mice. Iraqi J Vet Sci. 2025;39(2):199–205.
9. Duzguner V, Erdogan S. Chronic exposure to imidacloprid induces inflammation and oxidative stress in the liver & central nervous system of rats. Pest Biochem Physiol. 2012;104:58–64.
10. Prakash Panday S, Mohanty B. The neonicotinoid pesticide imidacloprid and the dithiocarbamate fungicide mancozeb disrupt the pituitary-thyroid axis of a wildlife bird. Chemosphere. 2015;122:227–34.
11. Karaboduk H, Adiguzel C, Apaydin FG, Uzunhisarcikli M, Kalender S, Kalender Y. The ameliorative effect of Naringenin on fenamiphos induced hepatotoxicity and nephrotoxicity in a rat model: oxidative stress, inflammatory markers, biochemical, histopathological, immunohistochemical and electron microscopy study. Food Chem Toxicol. 2024;192:114911.
12. Caglayan C, Temel Y, Kandemir FM, Yildirim S, Kucukler S. Naringin protects against cyclophosphamide-induced hepatotoxicity and nephrotoxicity through modulation of oxidative stress, inflammation, apoptosis, autophagy, and DNA damage. Environ Sci Pollut Res. 2018;25:20968–84.
13. Renugadevi J, Prabu SM. Naringenin protects against cadmium-induced oxidative renal dysfunction in rats. Toxicology. 2009;256:128–34.
14. Ayhan H, Adiguzel C, Korkmaz Bayram K, Akin AT, Apaydin FG, Kalender Y. Effect of propolis supplementation on cadmium toxicity associated with renal and hepatic dysfunction in rats. J Trace Elem Med Biol. 2025;87:127587.
15. Alshehri MA, Alissa M, Alghamdi A. Resveratrol attenuates cyclophosphamide-induced hepatic apoptosis in association with the inhibition of oxidative stress and inflammation in a rat model of acute liver injury. Tissue Cell. 2025;93:102728.
16. Khayal EE, Elhadidy MG, Alnasser SM, Morsy MM, Farag AI, El-Nagdy SA. Podocyte-related biomarkers' role in evaluating renal toxic effects of silver nanoparticles with the possible ameliorative role of resveratrol in adult male albino rats. Toxicol Rep. 2025;14:101882.
17. Zargar S, Alonazi M, Rizwana H, Wani TA. Resveratrol reverses thioacetamide-induced renal assault with respect to oxidative stress, renal function, DNA damage, and cytokine release in wistar rats. Oxid Med Cell Longev. 2019; 1702959.
18. Xiao Z, Ye Q, Duan X, Xiang T. Network pharmacology reveals that resveratrol can alleviate COVID-19-related hyperinflammation. Dis Markers. 2021;2021(1):4129993.
19. Wang R, Chen Y, Zhao X, Mi T, Li X, Tian Z, et al. Evidence and mechanisms of resveratrol against platelet function: a literature review and network pharmacology. Food Rev Int. 2025;41:1757–70.
20. Ibrahim MA, Albahlol IA, Wani FA, Tammam AAE, Kelleni MT, Sayeed MU, et al. Resveratrol protects against cisplatin-induced ovarian and uterine toxicity in female rats by attenuating oxidative stress, inflammation and apoptosis. Chem Biol Interact. 2021;338:109402.
21. Riba A, Deres L, Sumegi B, Toth K, Szabados E, Halmosi R. Cardioprotective effect of resveratrol in a postinfarction heart failure model. Oxid Med Cell Longev. 2017;2017(1):6819281.
22. Ahmedy OA, El-Tanbouly DM, Al-Mokaddem AK, El-Said YAM. Insights into the role of P2X7R/DUSP6/ERK1/2 and SIRT2/MDM2 signaling in the nephroprotective effect of berberine against cisplatin-induced renal fibrosis in rats. Life Sci. 2022;309:121040.
23. Eftekhari A, Hasanzadeh A, Khalilov R, Hosainzadegan H, Ahmadian E, Eghbal MA. Hepatoprotective role of berberine against paraquat-induced liver toxicity in rat. Environ Sci Pollut Res. 2020;27:4969–75.
24. Abdel-kawy SH, Mohamed DH, Lotfy M. Possible hepatoprotective role of berberine versus silymarin on methotrexate toxicity: histological and biochemical study. Egypt J Histol. 2023;46(1):435–47.
25. Shi L, Wang W, Jing C, Hu J, Liao X. Berberine and health outcomes: an overview of systematic reviews. BMC Complement Med Ther. 2025;25(1):1–15.
26. Blais JE, Huang X, Zhao JV. Overall and sex-specific effect of berberine for the treatment of dyslipidemia in adults: a systematic review and meta-analysis of randomized placebo-controlled trials. Drugs. 2023;83(5):403–27.
27. Yang L, Zhu W, Zhang X, Zhou X, Wu W, Shen T. Efficacy and safety of berberine for several cardiovascular diseases: a systematic review and meta-analysis of randomized controlled trials. Phytomedicine. 2023;112:154716.

28. Jado MA, Kalender Y. Small intestinal toxicity induced by imidacloprid in rats and the protective role of berberine and resveratrol. Bozok J Sci. 2024;2(2):38–46.
29. Owumi S, Otunla M, Arunsi U, Asogwa E, Chimezie J, Babalola JO, et al. Sub-chronic berberine supplementation in prepubertal male rats relieved pro-inflammatory stressors and enhanced reproductive functional parameters. Discov Mol. 2024;1(1):7.
30. Owumi S, Chimezie J, Otunla M, Oluwawibe B, Agbarogi H, Anifowose M, et al. Prepubertal repeated berberine supplementation enhances cerebrocerebellar functions by modulating neurochemical and behavioural changes in Wistar rats. J Mol Neurosci. 2024;74(3):72.
31. Owumi S, Oluwawibe B, Agbarogi H, Otunla MT, Arunsi U, Babalola JO, Irozuru C, Amadi C, Altayyar A. Dietary berberine reduced oxido-inflammatory stress in rats' livers and kidneys, supplemented from prepuberty to adulthood. Chem Food Chem. 2025; e00020.
32. Mikolic A, Karaconji IB. Imidacloprid as reproductive toxicant and endocrine disruptor: investigations in laboratory animals. Arh Hig Rada Toksikol. 2018;69:103–8.
33. Akbel E, Arslan-Acaroz D, Demirel HH, Kucukkurt I, Inced S. The subchronic exposure to malathion, an organophosphate pesticide, causes lipid peroxidation, oxidative stress, and tissue damage in rats: the protective role of resveratrol. Toxicol Res. 2018;7:503.
34. Moghaddam HK, Baluchnejadmojarad T, Roghani M, Khaksari M, Norouzi P, Ahooie M, et al. Berberine ameliorate oxidative stress and astrogliosis in the hippocampus of STZ-induced diabetic rats. Mol Neurobiol. 2014;49:820–6.
35. Ellman GL, Courtney KD, Andres V, Featherstone RM. A new and rapid colorimetric determination of acetylcholinesterase activity. Biochem Pharmacol. 1961;7:88–95.
36. Fidan EB, Bali EB, Apaydin FG. Comparative study of nickel oxide and nickel oxide nanoparticles on oxidative damage, apoptosis and histopathological alterations in rat lung tissues. J Trace Elem Med Biol. 2024;83:127379.
37. Nili-Ahmadabadi A, Soleimanipour Z, Artimani T, Asl SS, Ahmadimoghaddam D. Effects of thiacloprid, a neonicotinoid pesticide, on rat reproductive system: pregnancy hormone disruption and abortion trends. Pestic Biochem Physiol. 2024;205:106166.
38. Lonare M, Kumar M, Raut S, More A, Doltade S, Badgujar P, et al. Evaluation of ameliorative effect of curcumin on imidacloprid-induced male reproductive toxicity in Wistar rats. Environ Toxicol. 2016;31:1250–63.
39. Tonietto BD, Laurentino AOM, Costa-Valle MT, Cestonaro LV, Antunes BP, Sates C, et al. Imidacloprid-based commercial pesticide causes behavioral, biochemical, and hematological impairments in Wistar rats. Environ Toxicol Pharmacol. 2022;94:103924.
40. Hormozi A, Salehi H, Hosseini SMA, Rajabi S, Kabiri-Rad H, Mansori A, et al. Berberine nanoemulsion attenuates bisphenol A-induced metabolic impairment through NF-κB signaling in the liver of rat. Toxicol Rep. 2025;15:102069.
41. Alshehri FS. Resveratrol ameliorates vancomycin-induced testicular dysfunction in male rats. Medicina B Aires. 2023;59:486.
42. Issa SY, Rahman SMA, Gaber YM, Soliman NAH. Toxicological impact of thiamethoxam on adult male rats: histopathological, biochemical, and oxidative DNA damage assessment. Toxicol Rep. 2025;14:101983.
43. Al-Janabi QAA, Abdulhay HS. Effect of inhalation exposure to nano-imidacloprid on liver and kidney functions in male rats. IOP Conf Ser Earth Environ Sci. 2024;1325:012021.
44. Banaee M, Zeidi A, Haghi BN, Beitsayah A. The toxicity effects of imidacloprid and chlorpyrifos on oxidative stress and blood biochemistry in *Cyprinus carpio*. Comp Biochem Physiol C Toxicol Pharmacol. 2024;284:109979.
45. Edwards H, Mustfa W, Tehreem S, Salamatullah AM, Bourhia M, Ghafoor A. Pharmacotherapeutic potential of malvidin to cure imidacloprid induced hepatotoxicity via regulating PI3K/AKT, Nrf-2/Keap-1 and NF-κB pathway. Food Chem Toxicol. 2024;190:114816.
46. Mohammed ET, Hashem KS, Abdelazem AZ, Foda FA. Prospective protective effect of ellagic acid as a SIRT1 activator in iron oxide nanoparticle-induced renal damage in rats. Biol Trace Elem Res. 2020;198(1):177–88.
47. Monfared AL. Protective role of Vitis vinifera L extract against imidacloprid-intoxicated kidney, liver, and testis in Wistar rats. Comp Clin Pathol. 2024;33:135–44.
48. Kalender S, Apaydin FG, Kalender Y. Testicular toxicity of orally administrated bisphenol A in rats and protective role of taurine and curcumin. Pak J Pharm Sci. 2019;32(3):1043–7.
49. Karaboduk H, Adiguzel C, Uzunhisarcikli M, Apaydin FG, Kalender Y. Melatonin mitigates abamectin-induced subacute hematotoxicity and hepato-renal toxicity in rats by regulating oxidative stress, inflammatory responses, and apoptosis. J Biochem Mol Toxicol. 2025;39(10):e70512.
50. Mohammed ET, Safwat GM, Bahnasawy EA, Abdel-Razik ARH, Mohamed DS. Zinc oxide nanoparticles and vitamin C ameliorate atrazine-induced hepatic apoptosis in rat via CYP450s/ROS pathway and immunomodulation. Biol Trace Elem Res. 2023;201(11):5257–71.
51. Adiguzel C, Karaboduk H. Biochemical, immunohistochemical, histopathological, and apoptotic evaluation of nickel oxide nanoparticle-and microparticle-induced testicular toxicity in male rats. ACS Omega. 2024;9(52):50910–21.
52. Mohammed ET, Safwat GM. Grape seed proanthocyanidin extract mitigates titanium dioxide nanoparticle (TiO_2-NPs)–induced hepatotoxicity through TLR-4/NF-κB signaling pathway. Biol Trace Elem Res. 2020;196(2):579–89.
53. Adiguzel C, Karaboduk H, Apaydın FG, Kalender Y. Effects of quercetin on palladium chloride-induced endoplasmic reticulum stress, inflammation, oxidative stress, and apoptosis in hepatorenal tissues. Microsc Microanal. 2025;31(4):ozaf077.
54. Uzun FG, Kalender Y. Chlorpyrifos induced hepatotoxic and hematologic changes in rats the role of quercetin and catechin. Food Chem Toxicol. 2013;55:549–56.
55. Chakroun S, Grissa I, Ezzi L, Ammar O, Neffati F, Kerkeni E, et al. Imidacloprid enhances liver damage in wistar rats: Biochemical, oxidative damage and histological assessment. J Coast Life Med. 2017;5:540–6.
56. Rajagopalan V, Venkataraman S, Rajendran DS, Kumar VV, Kumar VV, Rangasamy G. Acetylcholinesterase biosensors for electrochemical detection of neurotoxic pesticides and acetylcholine neurotransmitter: a literature review. Environ Res. 2023;227:115724.
57. Korolev VA, Babkina LA, Felkera EV, Yachmenevaa LA, Chertovaa YR, Usacheva MA, et al. Variability in the content of 8-Hydroxy-2-deoxyguanosine as a marker of oxidative stress during subchronic intoxication with pesticides. Biochem (Mosc) Suppl B: Biomed Chem. 2025;19:30–6.
58. Taha MAI, Bada MEI, Abdel-Razik RK, Younis HM, Abo-El-Saad MM. Effects of sub-chronic exposure of male albino rats to chlorpyrifos, cypermethrin, and imidacloprid on mitochondrial dysfunction and oxidative stress in the kidney with molecular docking. J Cell Neurosci Oxid Stress. 2021;13(3):1014–30.
59. Adiguzel C, Karaboduk H, Uzunhisarcikli M. Protective role of melatonin against abamectin-induced biochemical, immunohistochemical, and ultrastructural alterations in the testicular tissues of rats. Microsc Microanal. 2024;30(5):962–77.
60. He B, Ni Y, Jin Y, Fu Z. Pesticides-induced energy metabolic disorders. Sci Total Environ. 2020;729:139033.

61. Degirmenci I, Ustuner MC, Kalender Y, Kalender S, Gunes HV. The effects of acarbose and *Rumex patientia* L. on ultrastructural and biochemical changes of pancreatic B cells in streptozotocin-induced diabetic rats. J Ethnopharmacol. 2005;97(3):555–9.
62. Kalender Y, Kalender S, Uzunhisarcikli M, Ogutcu A, Açikgoz F, Durak D. Effects of endosulfan on B cells of Langerhans islets in rat pancreas. Toxicology. 2004;200(2–3):205–11.
63. Begum K, Rajini PS. Augmentation of hepatic and renal oxidative stress and disrupted glucose homeostasis by monocrotophos in streptozotocin-induced diabetic rats. Chem Biol Interact. 2011;193(3):240–5.
64. Khalil SR, Awad A, Mohammed HH, Nassan MA. Imidacloprid insecticide exposure induces stress and disrupts glucose homeostasis in male rats. Environ Toxicol Pharmacol. 2017;55:165–74.
65. Adiguzel C, Karaboduk H, Apaydin FG, Kalender S, Kalender Y. Comparison of nickel oxide nano and microparticles toxicity in rat liver: molecular, biochemical, and histopathological study. Toxicol Res. 2023;12(5):741–50.
66. Karaboduk H, Adiguzel C, Apaydin FG, Kalender S, Kalender Y. Investigating the impact of different routes of nano and micro nickel oxide administration on rat kidney architecture, apoptosis markers, oxidative stress, and histopathology. J Mol Histol. 2024;55:675–86.
67. Wali A, Rashid S, Rashid SM, Ansari MA, Khan MR, Haq N, et al. Naringenin regulates doxorubicin-induced liver dysfunction: impact on oxidative stress and inflammation. Plants. 2020;9:550.
68. Gok E, Deveci E. Histopathological, immunohistochemical and biochemical alterations in liver tissue after fungicide-mancozeb exposures in wistar albino rats. Acta Cir Bras. 2022;37(04):e370404.
69. Azman PD, Yildirim S, Sengul E, Warda M, Tekin S, Aykurt F, et al. Protective effects of naringin against oxidative stress, inflammation, apoptosis, and DNA damage in rats with doxorubicin-induced hepatotoxicity. Asian Pac J Trop Biomed. 2025;15(7):285–95.
70. Hashim AR, Bashir DW, Yasin DAE, Rashad MM, El-Gharbawy SM. Ameliorative effect of N-acetylcysteine on the testicular tissue of adult male albino rats after glyphosate-based herbicide exposure. J Biochem Mol Toxicol. 2022;36:e22997.

Publisher's Note Springer Nature remains neutral with regard to jurisdictional claims in published maps and institutional affiliations.