·Basic Research·

A histological study of rabbit corneas after transepithelial corneal crosslinking using partial epithelial photoablation or ethanol treatment

Mehmet Cuneyt Ozmen [1], Ahmet Hondur [1], Guldal Yilmaz [2], Kamil Bilgihan [1], Berati Hasanreisoglu [1]

[1]Department of Ophthalmology, Gazi University, Ankara 06500, Turkey
[2]Department of Pathology, Gazi University, Ankara 06500, Turkey
Correspondence to: Mehmet Cuneyt Ozmen. Department of Ophthalmology, Gazi University, Gazi Universitesi, Goz Hastaliklari Anabilim Dali, 13. Kat, Besevler, Ankara 06500, Turkey. mcozmen@gmail.com
Received: 2013-07-19 Accepted: 2014-05-11

Abstract

• AIM: To evaluate the histological changes after transepithelial corneal crosslinking (CXL) using partial thickness excimer laser ablation or epithelial ethanol application in an experimental rabbit study.

• METHODS: Right eyes of twenty-four rabbits were studied. Four eyes received total epithelial debridement (group I). Four eyes received partial thickness epithelial ablation with excimer laser (group II). Twelve eyes were treated with different durations (30s and 60s) and concentrations (18% to 48%) of ethanol (group III). Riboflavin was applied for 30min intervals along with topical proparacaine drops with benzalkonium chloride, and 370 nm irradiation was performed for 30min, while riboflavin was instilled every 3min. Four eyes (group IV) received 48% ethanol for 30s without riboflavin and irradiation. Eyes were collected after 24h and examined histologically.

• RESULTS: All eyes in group I showed keratocyte loss in the superficial 300 μ of corneal storma. In group II, 1-4 layers of epithelium were preserved and no keratocyte loss occurred. In group III, CXL after treatment with ethanol up to 24% concentration and up to 60s revealed no keratocyte loss. CXL after treatment with 48% and higher ethanol concentrations yielded keratocyte loss in the superficial 200 μ to 300 μ of cornea.

• CONCLUSION: Incomplete excimer laser ablation of the epithelium or treatment with ethanol up to 24% concentration and up to 60s duration yielded no stromal keratocyte loss. To get the same histological appearance seen in epithelial debridement group, partial thickness excimer laser epithelial ablation or ethanol application is not adequate for transepithelial CXL.

• **KEYWORDS:** crosslinking; keratoconus; transepithelial; photoablation; ethanol; histology
DOI:10.3980/j.issn.2222-3959.2014.06.08

Ozmen MC, Hondur A, Yilmaz G, Bilgihan K, Hasanreisoglu B. A histological study of rabbit corneas after transepithelial corneal crosslinking using partial epithelial photoablation or ethanol treatment. *Int J Ophthalmol* 2014;7(6):959-963

INTRODUCTION

Since the introduction of corneal collagen crosslinking (CXL) in 2003 many studies have shown its efficacy and it is now a widely accepted treatment for progressive keratoconus [1-6]. The original technique described by Wollensak *et al* [1] involved 7-9 mm of the central corneal epithelium removal to obtain optimum amount of riboflavin and ultraviolet-A (UVA) in the corneal stroma. This leads to postoperative patient discomfort and infectious complications [7-12]. To reduce these complications different techniques of transepithelial CXL have been attempted [13-16]. However, the efficacy of transepithelial CXL has not been verified with histological studies[17,18].

CXL is made possible with the help of oxygen radicals produced by riboflavin and UVA light [19]. Wollensak *et al* [20,21] demonstrated that 300 μ of keratocyte loss is evident in successful crosslinking after epithelial debridement and with a 370 nm UVA irradiance of 3 mw/cm^2 for 30min. Hence, stromal keratocyte loss might be used as a surrogate marker for successful crosslinking[20,21].

The purpose of this study is to evaluate histological changes after different methods of transepithelial CXL and to compare these changes to epithelium off CXL in an experimental rabbit study. The rationale is to find a pre-clinical support for transepithelial CXL.

SUBJECTS AND METHODS

Subjects and Treatment Groups Right eyes of 24 female New Zealand white rabbits were treated with different methods of CXL. All animals were healthy. The study was approved by the ethics committee for animal experiments (File number: G.U.ET-09.050) and was conducted according

Table 1 Ethanol duration, epithelial viability, stromal keratocyte loss and endothelial viability of study groups

Eye	Groups	Ethanol[1]	Epithelium		Stroma		Endothelium
			Layers	Viability	Keratocyte loss[2]	Edema	Viability
1	I	NA	0	-	250	+	+
2	I	NA	0	-	280	+	+
3	I	NA	0	-	300	+	+
4	I	NA	0	-	310	+	+
5	II	NA	1	+	0	+	+
6	II	NA	2	+	0	+	+
7	II	NA	3	+	0	-	+
8	II	NA	2	+	0	-	+
9	IIIa	18%/60s	4	+	0	+	+
10	IIIa	18%/60s	5	+	0	+	+
11	IIIa	18%/60s	5	+	0	+	+
12	IIIa	18%/60s	5	+	0	+	+
13	IIIb	24%/60s	0	-	0	+	+
14	IIIb	24%/60s	0	-	0	+	+
15	IIIb	24%/60s	0	-	0	+	+
16	IIIb	24%/60s	0	-	0	+	+
17	IIIc	48%/30s	0	-	280	+	+
18	IIIc	48%/30s	0	-	300	+	+
19	IIIc	48%/30s	0	-	250	+	+
20	IIIc	48%/30s	0	-	300	+	+
21	IV	48%/30s[3]	0	-	50	-	+
22	IV	48%/30s[3]	0	-	60	-	+
23	IV	48%/30s[3]	0	-	50	-	+
24	IV	48%/30s[3]	0	-	80	-	+
25	Control	NA	5	+	0	-	+
26	Control	NA	4	+	0	-	+
27	Control	NA	4	+	0	-	+
28	Control	NA	5	+	0	-	+

[1]Concentration/duration of ethanol application; [2]Maximum depth of keratocyte loss in microns; [3]Did not receive riboflavin instillation nor UVA irradiation. NA: Not applicable.

to ARVO Statement for the Use of Animals in Ophthalmic and Vision Research.

Eyes were divided into 4 groups based on epithelial treatment method. Eyes in group I received 7.5 mm central epithelial debridement with a crescent blade. Group II received partial thickness (20 μ) epithelial ablation with excimer laser (ESIRIS excimer laser, SCHWIND, Kleinostheim, Germany) to facilitate riboflavin diffusion into corneal stroma. Eyes in group III were treated with different durations (30s and 60s) and concentrations (18%, 24% and 48%) of ethanol. Group III is divided into three subgroups depending on the ethanol application time and concentration. Four eyes received 18% ethanol for 60s (group IIIa), 4 eyes received 24% ethanol for 60s (group IIIb), and 4 eyes received 48% ethanol for 30s (group IIIc). Ethanol was applied over the central cornea with a 7.5 mm diameter laser assisted subepithelial keratomileusis (LASEK) well. After ethanol application no attempt was made to remove the epithelium. Four eyes in group IV received 30s of 48% ethanol without riboflavin instillation or UVA irradiation and served as control for group III. Left eyes of 4 rabbits were evaluated without treatment and served as negative control group (Table 1).

Crosslinking Treatment All treatments were done under general anesthesia with intramuscular 35 mg/kg ketamine hydrochloride and 5 mg/kg xylazine hydrochloride. After epithelial treatments in groups I to III, 0.1% riboflavin solution in 20% Dextran T-500 was applied for 30min with 3min intervals along with topical proparacaine drops with benzalkonium chloride (Alcaine, Alcon, Belgium). UVA irradiation was performed with a 370 nm double diode (Roithner Laser Technik, Austria) with an irradiance of 3 mw/cm^2 for 30min (total dose 5.4 J/cm^2), while riboflavin solution was instilled every 3min.

Histology Eyes were enucleated 24h postoperatively after sacrifice with 150 mg/kg intravenous sodium pentobarbital. Corneas were fixed in 10% neutral-buffered formalin for light microscopy. Paraffin sections were cut at 4 μ thickness and stained with hematoxylin-eosin. The specimens were evaluated under different magnifications with light microscope (×20- ×1000). Viability of epithelium, stromal keratocytes and endothelium were examined. Stromal depth of keratocyte loss was measured by a morphometry reticule.

TUNEL Assay To detect apoptosis with DNA strand breaks *in situ*, terminal deoxynucleotidyl transferase (TdT) mediated dUTP nick end labeling (TUNEL) was performed. After deparaffinization with ApopTag (Chemicon, EMD Millipore corporation, Billerica, MA, USA), the sections were washed with phosphate buffer saline (PBS) for 5min and stored in room temperature for 15min in proteinase K then washed twice with distilled water. Sections were kept in 3% hydrogen peroxide (H_2O_2) for 5min then washed with PBS. Drops of equilibrium buffer were applied to this tissue and after 10s excess liquid was drained, drops of working strength TdT enzyme was added and samples were incubated in a damp condition at 37℃ for 30min. After incubation it was shaken for 15s in stop-wash buffer then left in the buffer for 10min. Excess liquid was dried using blotting paper and drops of anti-digoxigenin was applied. Samples were stored in room temperature for 30min and were washed with PBS again and were stored in room temperature after peroxidase substrate was added. After washing thrice with distilled water it was stored in 1% methyl green for 10min in room temperature for opposing stain. At the end of the process samples were washed thoroughly with distilled water and were put in to xylene for 2-3min before dehydration with alcohol. Samples are then mounted with balsam and closed for examination. They were examined with light microscope.

RESULTS

Viability results of corneal epithelial cells, stromal keratocytes, and endothelial cells are demonstrated in Table 1. Histological examination of the corneas in group I (total epithelial debridement) showed stromal keratocyte loss up to 300 μ depth with no endothelial damage. At 24h, the epithelium had not healed (Figure 1). Anterior stroma was almost acellular with some remaining scattered apoptotic TUNEL-positive keratocytes. There were no TUNEL staining in the endothelium.

In eyes treated with transepithelial 20 μ excimer laser ablation to facilitate riboflavin diffusion (group II), different numbers of epithelial layers were observed at 24h postoperatively. There was no keratocyte loss even in eyes with one layer of basal epithelium (Figure 2). The endothelium was totally unaffected. In TUNEL-stained sections group II had scarce apoptotic cells in epithelial layer. There were no apoptosis in the stroma or endothelium.

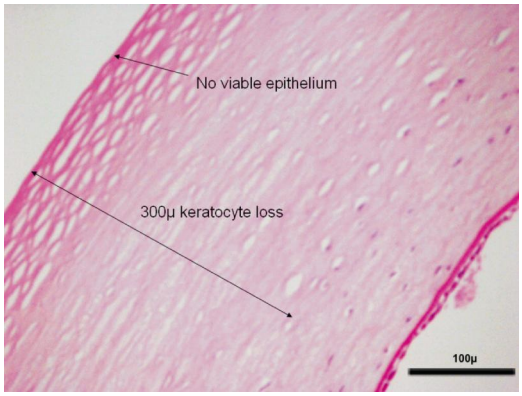

Figure 1 Histological examination of an eye in group I (total epithelial debridement). Diffuse keratocyte loss is seen to a depth of 300 μ with intact endothelium. Epithelial recovery is not observed (× 200 magnification).

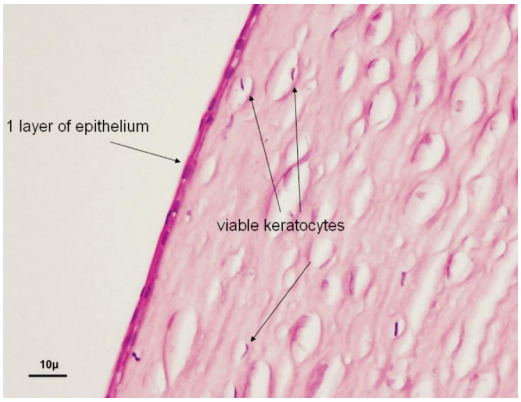

Figure 2 Histological examination of an eye in group II (20 μ transepithelial excimer laser ablation). Basal epithelial cell layers are intact. Diffuse keratocyte loss is not present with viable keratocytes in the superficial layers of stroma (×600 magnification).

In group IIIa, 4 eyes received 18% ethanol for 60s before CXL and these eyes showed no epithelial cell loss and no stromal keratocyte loss in the UVA irradiation zone. Histological examination was similar to negative control group. There were scarce apoptotic epithelial cells in the superficial layer but no apoptotic keratocytes in the stroma in TUNEL stained sections. Group IIIb received 24% ethanol for 60s and although epithelium was intact at the end of CXL procedure in all eyes of group IIIb, at 24h the epithelium had been totally sloughed in the central cornea, but no keratocyte loss was present (Figure 3). No apoptosis was shown with TUNEL staining in the stroma. In the 4 eyes which received 48% ethanol for 30s (group IIIc), epithelium remained intact throughout the procedure. However, epithelial edema was noted in these corneas despite no attempt to remove the epithelium. At 24h, there was no viable epithelium and there was keratocyte loss up to 300 μ depth (Figure 4). There were scattered TUNEL-positive epithelial cells in the peripheral cornea and apoptotic keratocytes in the stroma (Figure 5). The endothelium was unaffected in all group III eyes.

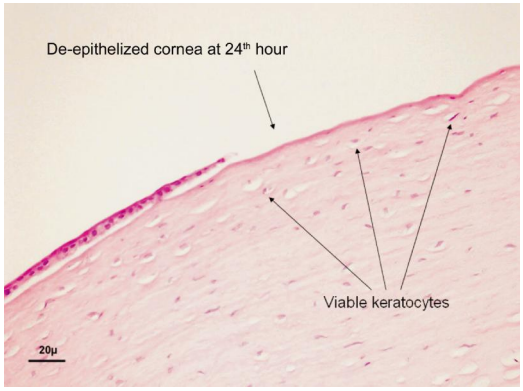

Figure 3 Histological examination of an eye in group IIIb (24% ethanol with a duration of 60s). Central epithelial cell damage is observed with no stromal keratocyte loss (×400 magnification).

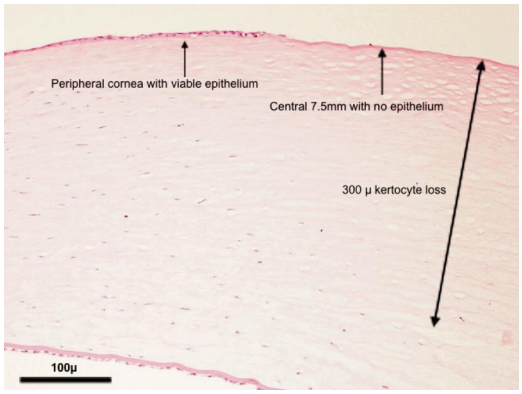

Figure 4 Histological examination of an eye in group IIIc (48% ethanol with a duration of 30s). Epithelial damage is observed with keratocyte loss up to 300 µ depth (×200 magnification).

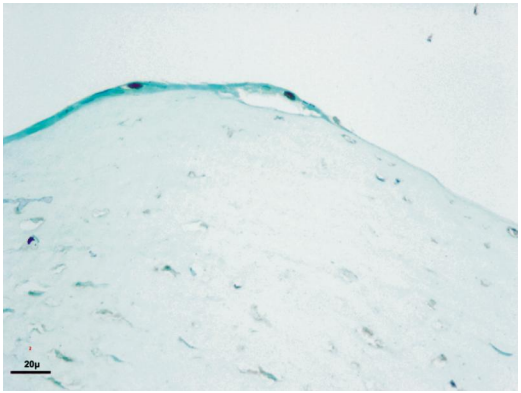

Figure 5 TUNEL stained section of an eye in group IIIc. Epithelial apoptotic cells and scattered TUNEL –positive keratocytes (×400 magnification).

In group IV (30s of 48% ethanol application without riboflavin instillation nor UVA irradiation) the epithelium had been totally sloughed and there was keratocyte loss up to 80 µ depth at 24h. The endothelium was unaffected.

Histological examination of negative control group revealed 4 to 5 layers of epithelial cells with normal distribution of keratocytes throughout corneal stroma and viable endothelial cells. There were no apoptotis in this group.

DISCUSSION

Today, CXL with riboflavin and UVA is the first line of defense in progressive ectatic diseases [4,19]. CXL is made possible with the help of oxygen radicals produced by riboflavin and UVA light [19]. Histologically, oxygen radical associated keratocyte apoptosis results in diffuse corneal stromal keratocyte loss in crosslinked eyes [20,21]. Hence, keratocyte loss can be used as a surrogate marker of successful CXL.

In the epithelial debridement group (group I) findings were similar to previous studies and keratocyte loss and scattered TUNEL-positive keratocytes in the upper 300 µ of the corneal stroma was observed, indicating successful accomplishment of CXL[20-24].

Our rationale for incomplete transepithelial ablation (group II) is to remove the epithelial tight junctions which are the main site of riboflavin blockage. A previous study showed that these tight junctions are located in the superficial layer of the stratified corneal epithelium of rabbit eyes [22]. In our study, no stromal keratocyte loss was observed in eyes treated with incomplete transepithelial ablation (group II). Even one layer of basal epithelium was sufficient to inhibit keratocyte loss (Figure 2). This implies that a single layer of basal epithelium might avoid riboflavin penetration into the corneal stroma, and therefore no keratocyte loss was observed. In contrast, Bakke *et al* [16] reported that after incomplete epithelial ablation, with prolonging the duration of riboflavin application by one third of the routine duration (40min instead of the routine 30min), the corneal stroma can be saturated with riboflavin.

It can be postulated that if 40min of riboflavin application is sufficient for total stromal saturation of human corneas, 30min should provide at least 75% saturation in rabbit corneas, which are about a 100 µ thinner than human corneas. Therefore, some keratocyte loss would be expected. However, another requisite for CXL is penetration of UVA into the corneal stroma. Previous studies have suggested that the epithelium may lead to insufficient penetration of UVA irradiation, even a sufficient level of stromal saturation with riboflavin is achieved [23-25]. Therefore, another obstacle for transepithelial CXL may be epithelial impediment of UVA penetration. Our results imply inadequate keratocyte loss with the transepithelial approach. However, the exact mechanism of inhibition-riboflavin or UVA penetration- requires further studies.

In group III, the rationale of ethanol application was to loosen the epithelial tight junctions, and therefore to assist the diffusion of riboflavin while maintaining the epithelium.

Twenty-four hours after CXL with epithelial treatment with 60s of 18% and 24% ethanol (groups IIIa and IIIb), no stromal keratocyte loss was noted. However, the epithelium was totally sloughed in group IIIb at 24h (Figure 3), despite

being totally intact at the end of the procedure. This implies that treatment of the epithelium with 24% ethanol for 60s was not sufficient for keratocyte loss, but caused epithelial damage leading to total sloughing by 24h.

After CXL with epithelial treatment with 30s of 48% ethanol concentrations (group IIIc), keratocyte loss and TUNEL staining was similar to that in group I (epithelial debridement) at 24h. During the procedure the epithelium remained intact, but became edematous indicating apparent epithelial damage. At 24h, the epithelium was totally sloughed. Therefore, application of 48% and higher ethanol concentrations seems to provide adequate riboflavin and UVA penetration for similar keratocyte loss as in group I. However, the epithelium seems to be totally damaged and completely sloughed, rendering this method infeasible for transepithelial CXL. In addition, high ethanol concentrations carry the risk of toxic effects to the superficial corneal stroma (50-80 μ superficial keratocyte loss) even without riboflavin and UVA as demonstrated in group IV (Table 1).

Tao *et al* [26] found that transepithelial CXL produces significantly improved biomechanical response compared to control group but less than stardard procedure group. This might suggest that although groups II, IIIa and IIIb has not shown the same histological results as group I, there might be a CXL effect to some extent.

In conclusion, an intact epithelium during riboflavin administration and UVA irradiation seems to inhibit keratocyte loss, which is seen in standard crosslinking process. Partial thickness excimer laser epithelial ablation or ethanol application is not sufficient to achieve the same histological appearance seen in epithelial debridement group. Epithelial removal seems mandatory to achieve similar histological changes in standard CXL method. Further histological and biomechanical studies with modifications of UVA dose and riboflavin application are required to address safety and efficacy of transepithelial CXL.

ACKNOWLEDGEMENTS

Conflicts of Interest: Ozmen MC, None; **Hondur A,** None; **Yilmaz G,** None; **Bilgihan K,** None; **Hasanreisoglu B,** None.

REFERENCES

1 Wollensak G, Spoerl E, Seiler T. Riboflavin/ultraviolet-a-induced collagen crosslinking for the treatment of keratoconus. *Am J Ophthalmol* 2003;135(5):620-627

2 Caporossi A, Mazzotta C, Baiocchi S, Caporossi T. Long-term results of riboflavin ultraviolet a corneal collagen cross-linking for keratoconus in Italy: the Siena eye cross study. *Am J Ophthalmol* 2010;149(4):585-593

3 Iovieno A, Oechsler RA, Yoo SH. Long-term results of collagen crosslinking with riboflavin and UVA in keratoconus. *J Cataract Refract Surg* 2008;34(10):1616-1617; author reply 1617

4 Wollensak G. Crosslinking treatment of progressive keratoconus: new hope. *Curr Opin Ophthalmol* 2006;17(4):356-360

5 Spoerl E, Wollensak G, Seiler T. Increased resistance of crosslinked cornea against enzymatic digestion. *Curr Eye Res* 2004;29(1):35-40

6 Raiskup-Wolf F, Hoyer A, Spoerl E, Pillunat LE. Collagen crosslinking with riboflavin and ultraviolet-A light in keratoconus: long-term results. *J Cataract Refract Surg* 2008;34(5):796-801

7 Sharma N, Maharana P, Singh G, Titiyal JS. Pseudomonas keratitis after collagen crosslinking for keratoconus: case report and review of literature. *J Cataract Refract Surg* 2010;36(3):517-520

8 Zamora KV, Males JJ. Polymicrobial keratitis after a collagen cross-linking procedure with postoperative use of a contact lens: a case report. *Cornea* 2009;28(4):474-476

9 Rama P, Di Matteo F, Matuska S, Paganoni G, Spinelli A. Acanthamoeba keratitis with perforation after corneal crosslinking and bandage contact lens use. *J Cataract Refract Surg* 2009;35(4):788-791

10 Pollhammer M, Cursiefen C. Bacterial keratitis early after corneal crosslinking with riboflavin and ultraviolet-A. *J Cataract Refract Surg* 2009;35(3):588-589

11 Perez-Santonja JJ, Artola A, Javaloy J, Alio JL, Abad JL. Microbial keratitis after corneal collagen crosslinking. *J Cataract Refract Surg* 2009; 35(6):1138-1140

12 Micelli Ferrari T, Leozappa M, Lorusso M, Epifani E, Micelli Ferrari L. Escherichia coli keratitis treated with ultraviolet A/riboflavin corneal cross-linking: a case report. *Eur J Ophthalmol* 2009;19(2):295-297

13 Leccisotti A, Islam T. Transepithelial corneal collagen cross-linking in keratoconus. *J Refract Surg* 2010;26(12):942-948

14 Ertan A, Karacal H, Kamburoglu G. Refractive and topographic results of transepithelial cross-linking treatment in eyes with intacs. *Cornea* 2009; 28(7):719-723

15 Chan CC, Sharma M, Wachler BS. Effect of inferior-segment Intacs with and without C3-R on keratoconus. *J Cataract Refract Surg* 2007;33 (1): 75-80

16 Bakke EF, Stojanovic A, Chen X, Drolsum L. Penetration of riboflavin and postoperative pain in corneal collagen crosslinking: excimer laser superficial versus mechanical full-thickness epithelial removal. *J Cataract Refract Surg* 2009;35(8):1363-1366

17 Samaras K, O'Brart DP, Doutch J. Hayes S, Marshall J, Meek KM. Effect of epithelial retention and removal on riboflavin absorption in porcine corneas. *J Refract Surg* 2009;25(9):771-775

18 Baiocchi S, Mazzotta C, Cerretani D, Caporossi T, Caporossi A. Corneal crosslinking: riboflavin concentration in corneal stroma exposed with and without epithelium. *J Cataract Refract Surg* 2009;35(5):893-899

19 Spoerl E, Mrochen M, Sliney D, Trokel S, Seiler T. Safety of UVA-riboflavin cross-linking of the cornea. *Cornea* 2007;26(4):385-389

20 Wollensak G, Spoerl E, Wilsch M, Seiler T. Keratocyte apoptosis after corneal collagen cross-linking using riboflavin/UVA treatment. *Cornea* 2004;23(1):43-49

21 Wollensak G, Spoerl E, Reber F, Seiler T. Keratocyte cytotoxicity of riboflavin/UVA-treatment *in vitro*. *Eye* 2004;18(7):718-722

22 McLaughlin BJ, Caldwell RB, Sasaki Y, Wood TO. Freeze-fracture quantitative comparison of rabbit corneal epithelial and endothelial membranes. *Curr Eye Res* 1985;4(9):951-961

23 Boxer Wachler BS, Pinelli R, Ertan A, Chan CC. Safety and efficacy of transepithelial crosslinking (C3-R/CXL). *J Cataract Refract Surg* 2010;36 (1):186-188; author reply 188-189

24 Wollensak G, Iomdina E. Biomechanical and histological changes after corneal crosslinking with and without epithelial debridement. *J Cataract Refract Surg* 2009;35(3):540-546

25 Spoerl E, Huhle M, Seiler T. Induction of cross-links in corneal tissue. *Exp Eye Res* 1998;66(1):97-103

26 Tao X, Yu H, Zhang Y, Li Z, Jhanji V, Ni S, Wang Y, Mu G. Role of corneal epithelium in riboflavin/ultraviolet-A mediated corneal cross-linking treatment in rabbit eyes. *Biomed Res Int* 2013;2013:624563